

HEPATIC SOLITARY FIBROUS TUMOR: A RARE ENTITY CASE REPORT AND REVIEW OF THE LITERATURE

Tiago dos Santos Gutierrez Lazaro

Departamento de Cirurgia do Aparelho Digestivo, Hospital Universitário, Universidade Federal de Sergipe, Aracaju, Sergipe, Brasil
ORCID: 0009-0002-4157-6236

Iago Fernando Alencar Amorim

Departamento de Cirurgia do Aparelho Digestivo, Hospital Universitário, Universidade Federal de Sergipe, Aracaju, Sergipe, Brasil
ORCID: 0009-0006-2572-543X

René Pereira da Costa

Departamento de Cirurgia do Aparelho Digestivo, Hospital Universitário, Universidade Federal de Sergipe, Aracaju, Sergipe, Brasil
ORCID: 0009-0009-6918-5211

Paulo Eduardo Gonçalves

Departamento de Medicina, Universidade Federal de Sergipe, Aracaju, Sergipe, Brasil
ORCID: 0000-0002-9433-6482

Antônio Alves Junior

Departamento de Cirurgia do Aparelho Digestivo, Hospital Universitário, Universidade Federal de Sergipe, Aracaju, Sergipe, Brasil
ORCID: 0000-0002-5034-6187

All content in this magazine is licensed under a Creative Commons Attribution License. Attribution-Non-Commercial-Non-Derivatives 4.0 International (CC BY-NC-ND 4.0).



Abstract: Background: Solitary Fibrous Tumor is a rare entity that originates from the meninges and soft tissues. It shows expression for markers such as SATAT6 and CD34 in immunohistochemical methods. More present in women aged 50-60 years old. **Objective:** to report the case of a 49-year-old patient, who started with abdominal pain and bloating. The computed tomography image demonstrated a mass in the region of the left hepatic lobe measuring 15.3x13.7x11.1 cm. Surgical resection was chosen, given the patient's symptoms and the imaging findings. After pathological and immunohistochemical analysis, the diagnosis of solitary fibrous hepatic tumor was given. **Discussion:** in the literature there is still some controversy regarding the best treatment, but many studies suggest that surgical resection with a safety margin is the best option. **Conclusion:** this is a rare entity, with few reports in the literature and we hope that our case can contribute to a better understanding of this entity. **Keywords:** Solitary Fibrous Tumor; Liver Neoplasms; Oncological Surgery.

INTRODUCTION

Solitary fibrous tumor (SFT) is an entity that has its etiology not understood yet. It generally originates in the meninges and soft tissues (EHMAN et al., 2018). Histologically, it is originated from the pericytes that surround the vessels endothelium. In microscope, it shows areas of hypocellular and hypercellular growth, presenting no pattern and having staghorn vessels, showing around 50% of cellular atypia, and in the malignant ways, presents a higher score of mitotic activity. Using immunohistochemistry methods, these tumors present positivity for CD34 and STAT-6 (SARANGI et al., 2023). It is an extreme rare tumor, presenting in less than 2% of all soft tissue tumors (HUANG; HUANG, 2019). Its presentation in the liver

may be as primary or metastatic tumor and having an incidence of less than 1%. It appears more often in females, aged between 50 and 60 years old, presenting as a well-defined lesion, generally with hemorrhage and cystic degeneration (SARANGI et al., 2023).

STF presents a non-specific symptomatology, such as vomiting, weight loss, post prandial fullness, anorexia, abdominal distention, and fatigue. It may remain asymptomatic and presents an acute abdominal case due to its rupture. It may be diagnosed by ultrasound (USG), computed tomography (CT) or magnetic resonance imaging (MRI), where the last is the option of choice to the best diagnosis. The tumor shows a well-delimited image in the USG demonstrating hypo and hyperechogenic areas; on non-contrast TC, it presents hypodense imaging; on MRI, SFT has hypointense signal on T1, while on T2 presents an iso-hyperintensity. It may present hyperintensity signals on T2-weighted images due to cystic components, vessels, and hypercellularity. (SARANGI et al., 2023)

The treatment of choice to this tumor is a total gross resection, with good margins and long-term follow-up Kalinin et al., demonstrating a 90% rate of tumor-free survival and only 5-10% of metastatic occurrence (KALININ et al., 2016). Some long-term follow-up recent studies show a tendency in late recurrence for these tumors, approximately 10 years after the first surgery. The rates of overall recurrence and metastatic rates have been estimated to be 5-12% and 14-26%, respectively (DEMICCO et al., 2012; GHOLAMI et al., 2017; SALAS et al., 2017) encompassing tumors previously termed hemangiopericytoma, which are classified as having intermediate biological potential (rarely metastasizing. In cases where the tumor is inoperable, high-risk, or recurrent, radiation therapy may be indicated, although it rules out a consistent survival benefit (COHEN-INBAR et al., 2017). In

the same way, it barely achieves 20% of partial or complete response to conventional chemotherapies (CONSTANTINIDOU et al., 2012; PARK; ARAUJO, 2009; STACCHIOTTI et al., 2013). The main point of our study is to report a case of a malignant solitary fibrous tumor aiming sharing our experience with medical literature.

CASE REPORT

We report a case of a 49-year-old patient, female, with complaints of abdominal pain and gastric distension associated with early gastric fullness. She claimed to have hypertension and irregular use of losartan. She presented laboratory tests with the following changes, alanine aminotransferase 28 U/L, aspartate aminotransferase 33 U/L, gamma glutamyl transferase 306 U/L, CA 125 130.6, alkaline phosphatase 726 U/L, C-reactive protein 198.7 mg/L, partially activated thromboplastin time 36.3s, prothrombin time 20.8s. Computed tomography of the abdomen was performed showing a massive solid expansive formation with heterogeneous contrast enhancement, presenting hyper vascular foci with delayed washout and areas of cystic/necrotic degeneration in between, measuring 15.3 x 13.7 x 11.1 cm and occupying almost the entire left hepatic lobe (Fig. 1). The lesion compresses the portal vein, subsequently pushing back the antro-gastric, duodenal bulb and pancreas. The lateral end of hepatic segment III did not show contrast enhancement, suggesting an ischemic vascular lesion. We raised the following hypotheses: hepatic adenoma, hepatocarcinoma or cavernous hemangioma. The surgical approach was chosen due to findings in the CT scan and the symptomatology of the patient.

Surgery began with the patient in the horizontal supine position under general anesthesia associated with an epidural. Soon after, antisepsis was performed, followed by

asepsis and placement of sterile fields. Then, a supra-umbilical incision was made, with subcutaneous hemostasis, opening of the abdominal wall. Soon after, an inventory was carried out showing a liver with a steatotic appearance with grade II and III lesions, with a large volume measuring 14x14 cm. Adhesion lysis and dissection of vessels in the hepatic hilum were performed. Identification of Winslow's foramen and passage of a #12 Foley probe towards the small omentum (Pringle maneuver). Lysis of lateral adhesions was performed, release of the left coronary and triangular ligaments until the vena cava was exposed, and the left hepatic vein was identified. MM positioning and stapled, using 4 loads, consequently having resection of the left hepatic lobe (Fig. 2). Cavity review, hemostasis and compress counts were performed without any changes. A Blake drain was placed on the right flank, fixed with Nylon 2-0, the aponeurosis was closed with Vicryl 1 and, finally, the skin was sutured with Monocryl 4-0.

The patient did well postoperatively, being discharged home 3 days after surgery and followed up with clinical oncology. The pathology revealed atypical hypercellular fusoeplithelioid neoplasia with the presence of areas of necrosis, occasional atypical pleomorphic multinucleated cells, a mitotic index of 10 mitoses per 10 high power fields, the presence of a focal area suspicious for angiolymphatic vascular infiltration, with no evidence of perineural infiltration (Fig. 3A). Immunohistochemistry (IHC) revealed focal expression of CD34 (Fig. 3B) and weak expression of STAT6 (Fig. 3C), corroborating the diagnosis of malignant solitary fibrous tumor.

We performed a review of the literature of SFT in the liver and it came up with 39 cases. We reported the cases, age, local of occurrence in the liver, size, treatment performed, the results of IHC and the time of follow-up (Table 1).

DISCUSSION

The first solitary fibrous tumor has been described in 1931 in the pleura (KLEMPERER; COLEMAN, 1992). After that, WHO classified SFT outside of the pleura as fibroblastic/myofibroblastic neoplasm with a rare metastatic behavior (JO; FLETCHER, 2014). Later, in 2020, WHO mentions that there are SFT benign and malignant. In addition, they state that SFT is still a challenge to diagnose because it may mimic other types of tumor, such as many mesenchymal and non-mesenchymal entities (SBARAGLIA; BELLAN; DEI TOS, 2020).

The tumor's symptomatology is not specific. It may vary according to its localization and size. The most common symptoms cited in the literature are dyspnea, abdominal pain, weight loss, nausea, vomiting and hyperglycemia. The last one may be related to the insulin like growth factor 2 (IFG-2) (WANG et al., 2021). In our case, the patient started with an abdominal pain associated with distension probably caused by the tumor's compression in the gastro-intestinal tract.

MRI and CT are very important imaging methods to localize and study the tumor in a macroscopic view, although diagnose these tumors is extremely important to analyze its microscopic anatomy along with IHC (SARANGI et al., 2023). Nowadays, IHC has becoming more accurate, and some

marks can be associated with SFT. The CD34, Vimentin, CD99, Bcl-2 are some markers that can be found in SFTs, although they are not expressed only for SFT. Meanwhile, Doyle et al. suggests that SATAT6 may be a marker to identify SFT (DOYLE et al., 2014). In their study they evaluated about 240 mesenchymal tumors, including SFTs, among them 98% expressed SATAT6, while the other types of mesenchymal tumors did not express the marker (DOYLE et al., 2014).

Regarding treatment options, our research showed that 32 of the cases (82%) were treated with resection, followed by 3 cases (7,7%) treated with resection plus chemotherapy. Our case was optioned for only resection since we could obtain good margins and the patient had no clinical or laboratory signs of metastasis. In accordance with the literature, Spitz et al and Espat et al. suggest that resection is the best approach to treat SFT, the overall 10-year survival rate in surgical studies with clear margins ranged from 54% and 89% (ESPAT et al., 2002; SPITZ et al., 1998).

Our case has been accessed by the oncological team of our service. After 6 months after the resection, the patient maintains with no symptomatology and remains with laboratory findings in the limits of normality and no signs of recurrence on CT. Therefore, we can conclude that hepatic solitary fibrous tumor is a rare entity associated with good rates of overall survival.

REFERENCES

- ALONSO BATANERO, S. et al. A giant solitary fibrous tumor arising from the hepatic round ligament. *Digestive and Liver Disease*, v. 53, n. 3, p. 379–380, mar. 2021.
- ANDALUZ GARCÍA, I.; TAVECCHIA, M.; OLVEIRA MARTÍN, A. A solitary fibrous tumor: an entity to consider in the diagnosis of liver masses. *Revista Española de Enfermedades Digestivas*, v. 111, 2019.
- BELGA, S.; FERREIRA, S.; LEMOS, M. M. A Rare Tumor of the Liver With a Sudden Presentation. *Gastroenterology*, v. 143, n. 3, p. e14–e15, set. 2012.
- BELTRÁN, M. A. Solitary Fibrous Tumor of the Liver: a Review of the Current Knowledge and Report of a New Case. *Journal of Gastrointestinal Cancer*, v. 46, n. 4, p. 333–342, dez. 2015.

CAMERLO, A. et al. Robotic Resection of a Central Liver Solitary Fibrous Tumor (with Video). **Journal of Gastrointestinal Surgery**, v. 24, n. 12, p. 2903–2903, dez. 2020.

CHAN, G. et al. Malignant transformation of a solitary fibrous tumor of the liver and intractable hypoglycemia. **Journal of Hepato-Biliary-Pancreatic Surgery**, v. 14, n. 6, p. 595–599, 30 nov. 2007.

CHEN, N.; SLATER, K. Solitary fibrous tumour of the liver—report on metastasis and local recurrence of a malignant case and review of literature. **World Journal of Surgical Oncology**, v. 15, p. 27, 18 jan. 2017.

COHEN-INBAR, O. et al. Stereotactic radiosurgery for intracranial hemangiopericytomas: a multicenter study. **Journal of Neurosurgery**, v. 126, n. 3, p. 744–754, mar. 2017.

CONSTANTINIDOU, A. et al. Conventional anthracycline-based chemotherapy has limited efficacy in solitary fibrous tumour. **Acta Oncologica (Stockholm, Sweden)**, v. 51, n. 4, p. 550–554, abr. 2012.

DEBS, T. et al. Solitary fibrous tumor of the liver: Report of two cases and review of the literature. **International Journal of Surgery**, v. 12, n. 12, p. 1291–1294, dez. 2014.

DEMICO, E. G. et al. Solitary fibrous tumor: a clinicopathological study of 110 cases and proposed risk assessment model. **Modern Pathology: An Official Journal of the United States and Canadian Academy of Pathology, Inc**, v. 25, n. 9, p. 1298–1306, set. 2012.

DOYLE, L. A. et al. Nuclear expression of STAT6 distinguishes solitary fibrous tumor from histologic mimics. **Modern Pathology: An Official Journal of the United States and Canadian Academy of Pathology, Inc**, v. 27, n. 3, p. 390–395, mar. 2014.

EHMAN, E. C. et al. Hepatic tumors of vascular origin: imaging appearances. **Abdominal Radiology**, v. 43, n. 8, p. 1978–1990, 1 ago. 2018.

ESPAT, N. J. et al. Conventional hemangiopericytoma: modern analysis of outcome. **Cancer**, v. 95, n. 8, p. 1746–1751, 15 out. 2002.

ESTEVEZ, C. et al. Malignant Solitary Fibrous Tumor of the Liver: *AIRP Best Cases in Radiologic-Pathologic Correlation*. **RadioGraphics**, v. 37, n. 7, p. 2018–2025, nov. 2017.

FU, Z. et al. A Case of Hepatic Malignant Solitary Fibrous Tumor: A Case Report and Review of the Literature. **Case Reports in Pathology**, v. 2023, p. 1–5, 9 fev. 2023.

FUKSBRUMER, M. S.; KLIMSTRA, D.; PANICEK, D. M. Solitary Fibrous Tumor of the Liver. 2000.

GHOLAMI, S. et al. Size and Location are the Most Important Risk Factors for Malignant Behavior in Resected Solitary Fibrous Tumors. **Annals of Surgical Oncology**, v. 24, n. 13, p. 3865–3871, dez. 2017.

GUGLIELMI, A. et al. Solitary fibrous tumor of the liver with CD 34 positivity and hypoglycemia. **Journal of Hepato-Biliary-Pancreatic Surgery**, v. 5, n. 2, p. 212–216, 3 set. 1998.

HOSEINI, M. et al. A Giant Solitary Fibrous Tumor of the Liver with Metastasis and Local Recurrence. **Journal of Pharmaceutical Research International**, p. 18–23, 6 abr. 2020.

HUANG, S.-C.; HUANG, H.-Y. Solitary fibrous tumor: An evolving and unifying entity with unsettled issues. **Histology and Histopathology**, v. 34, n. 4, p. 313–334, abr. 2019.

JAKOB, M. Malignant solitary fibrous tumor involving the liver. **World Journal of Gastroenterology**, v. 19, n. 21, p. 3354, 2013.

JO, V. Y.; FLETCHER, C. D. M. WHO classification of soft tissue tumours: an update based on the 2013 (4th) edition. **Pathology**, v. 46, n. 2, p. 95–104, fev. 2014.

KALININ, P. L. et al. Endoscopic transsphenoidal resection of pituitary adenomas invading the cavernous sinus. **Voprosy neirokhirurgii imeni N.N. Burdenko**, v. 80, n. 4, p. 63, 2016.

KLEMPERER, P.; COLEMAN, B. R. Primary neoplasms of the pleura. A report of five cases. **American Journal of Industrial Medicine**, v. 22, n. 1, p. 1–31, 1992.

KORKOLIS, D. P. et al. Solitary fibrous tumor of the liver expressing CD34 and vimentin: A case report. **World Journal of Gastroenterology**, v. 14, n. 40, p. 6261, 2008.

LIN, J. et al. Multidisciplinary collaboration for the successful treatment of a giant hepatic solitary fibrous tumor protruding into the thorax: A case report. **Experimental and Therapeutic Medicine**, v. 24, n. 1, p. 461, 20 maio 2022.

LIU, Q. et al. Primary solitary fibrous tumors of liver: a case report and literature review. **Diagnostic Pathology**, v. 8, p. 195, 2 dez. 2013.

MACCIO, L. et al. Malignant metastasizing solitary fibrous tumors of the liver: a report of three cases. **Polish Journal of Pathology**, v. 1, p. 72–76, 2015.

MAKINO, Y. et al. Solitary Fibrous Tumor of the Liver from Development to Resection. **Internal Medicine**, v. 54, n. 7, p. 765–770, 2015.

NAM, H. C. et al. Solitary fibrous tumor of the liver mimicking malignancy. **The Korean Journal of Internal Medicine**, v. 35, n. 3, p. 734–735, 1 maio 2020.

NATH, D. S.; RUTZICK, A. D.; SIELAFF, T. D. Solitary Fibrous Tumor of the Liver. **American Journal of Roentgenology**, v. 187, n. 2, p. W187–W190, ago. 2006.

NOVAIS, P. et al. Solitary Fibrous Liver Tumor: Is Surgical Approach the Best Option? **Journal of Gastrointestinal and Liver Diseases**, v. 19, n. 1, p. 81–84, 1 mar. 2010.

PARK, M. S.; ARAUJO, D. M. New insights into the hemangiopericytoma/solitary fibrous tumor spectrum of tumors. **Current Opinion in Oncology**, v. 21, n. 4, p. 327–331, jul. 2009.

PENG, L. et al. Skull base metastases from a malignant solitary fibrous tumor of the liver. A case report and literature review. **Diagnostic Pathology**, v. 6, n. 1, p. 127, dez. 2011.

PERINI, M. V. et al. Solitary fibrous tumor of the liver: Report of a rare case and review of the literature. **International Journal of Surgery**, v. 6, n. 5, p. 396–399, out. 2008.

SALAS, S. et al. Prediction of local and metastatic recurrence in solitary fibrous tumor: construction of a risk calculator in a multicenter cohort from the French Sarcoma Group (FSG) database. **Annals of Oncology: Official Journal of the European Society for Medical Oncology**, v. 28, n. 8, p. 1979–1987, 1 ago. 2017.

SARANGI, S. et al. Vascular tumors of the liver: A brief review. **Annals of Hepato-Biliary-Pancreatic Surgery**, v. 27, n. 4, p. 329–341, 30 nov. 2023.

SBARAGLIA, M.; BELLAN, E.; DEI TOS, A. P. The 2020 WHO Classification of Soft Tissue Tumours: news and perspectives. **Pathologica**, v. 113, n. 2, p. 70–84, 3 nov. 2020.

SHU, Q. et al. Malignant solitary fibrous tumor of. [s.d.].

SILVANTO, A.; KARANJIA, N. D.; BAGWAN, I. N. Primary hepatic solitary fibrous tumor with histologically benign and malignant areas. **Hepatobiliary & Pancreatic Diseases International**, v. 14, n. 6, p. 665–668, 1 dez. 2015.

SONG, L.; ZHANG, W.; ZHANG, Y. 18F-FDG PET/CT Imaging of Malignant Hepatic Solitary Fibrous Tumor. **Clinical Nuclear Medicine**, v. 39, n. 7, p. 662–664, jul. 2014.

SPITZ, F. R. et al. Hemangiopericytoma: a 20-year single-institution experience. **Annals of Surgical Oncology**, v. 5, n. 4, p. 350–355, jun. 1998.

STACCHIOTTI, S. et al. Response to chemotherapy of solitary fibrous tumour: a retrospective study. **European Journal of Cancer (Oxford, England: 1990)**, v. 49, n. 10, p. 2376–2383, jul. 2013.

SUN, K. et al. Solitary fibrous tumor of the liver: a case report. **World Journal of Surgical Oncology**, v. 9, n. 1, p. 37, dez. 2011.

TERKIVATAN, T. et al. Giant solitary fibrous tumour of the liver. **World Journal of Surgical Oncology**, v. 4, n. 1, p. 81, dez. 2006.

VENNARECCI, G. et al. Solitary fibrous tumor of the liver. **Journal of Hepato-Biliary-Pancreatic Surgery**, v. 12, n. 4, p. 341–344, 22 ago. 2005.

WANG, W. et al. Two case reports of rare diseases occurring in rare parts: splenic vein solitary fibrous tumor and liver solitary fibrous tumor. **AME Case Reports**, v. 5, p. 17–17, abr. 2021.

YE, X. et al. A giant malignant solitary fibrous tumor in the liver: A case report. **Asian Journal of Surgery**, v. 46, n. 9, p. 3920–3923, set. 2023.

YILMAZ, S. et al. Giant solitary fibrous tumor of the liver with metastasis to the skeletal system successfully treated with trisegmentectomy. **Digestive Diseases and Sciences**, v. 45, n. 1, p. 168–174, jan. 2000.

YUGAWA, K. et al. Solitary fibrous tumor in the liver: case report and literature review. **Surgical Case Reports**, v. 5, n. 1, p. 68, dez. 2019.

FIGURES

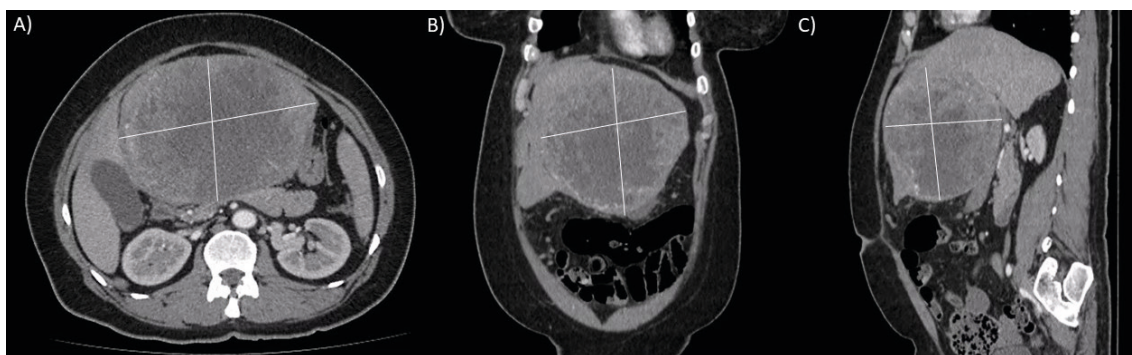


Figure 1. A) Contrasted CT in axial demonstrating a bulky solid expansive formation with heterogeneous contrast enhancement, presenting hypervascular foci with delayed washout and areas of cystic/necrotic degeneration in between, measuring approximately 15.3 x 13.7 cm (height x width) and occupying almost the entire left hepatic lobe. B) Coronal view of the mass. C) Sagittal view of the mass showing the depth measuring 11.1cm

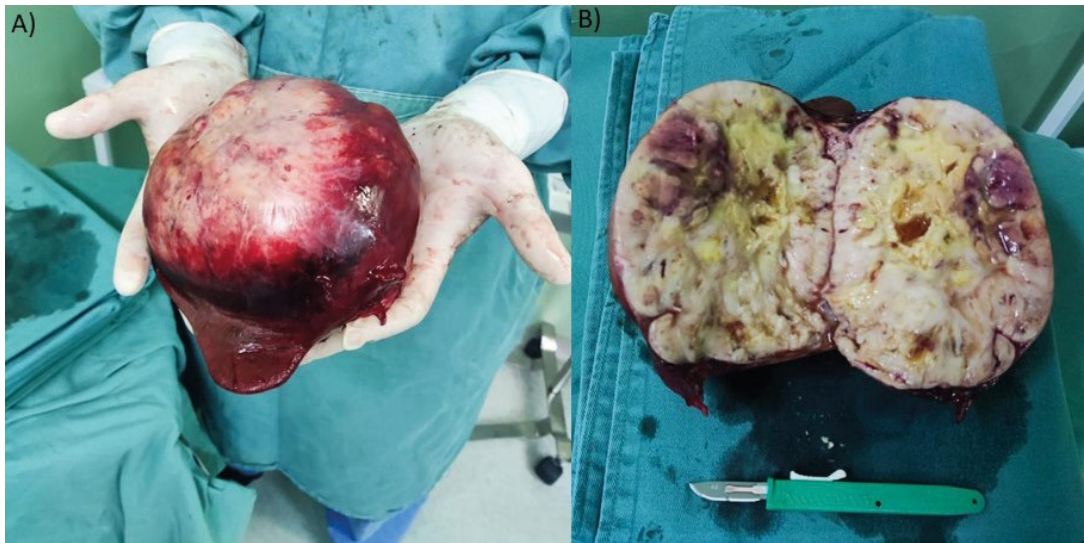


Figure 2. A) The tumor right after its extraction. B) The tumor sliced in two parts, and a scalpel was used to compare the size (The scalpel measures 15cm in length).

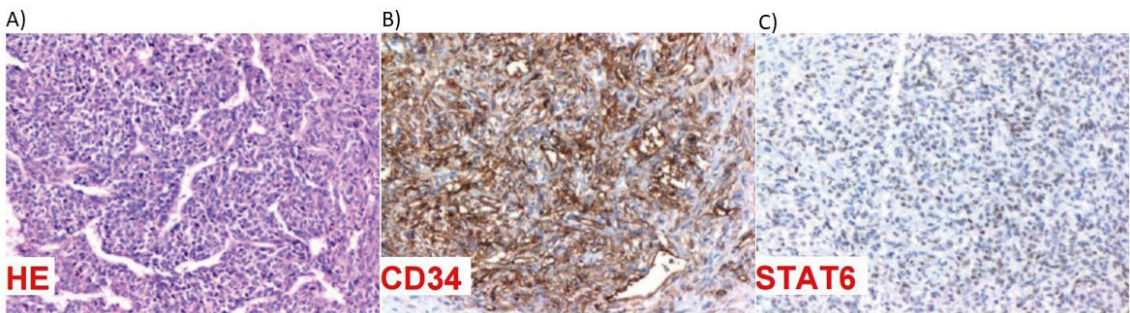


Figure 3. A) Mesenchymal neoplasm composed of spindle cells and ovoid cells with hyperchromatic and pleomorphic nuclei, with vessels with a hemangiopericytic pattern in between and areas of necrosis. B) IHC demonstrating focal expression to CD34. C) IHC demonstrating focal expression to STAT6.

TABLES

No	Author, year	Age (years)	Sex	Lobe	Size Lx Wx H (cm)	Treatment	IHC	Follow-up
1	Batanero, 2020 (ALONSO BATANERO et al., 2021)	76 y	F	HRL	31 x 30 x 17	Ressection	CD 34+; CD 99 +; Bcl-2 +; Beta-catenin +	10m
2	Belga, 2012 (BELGA; FERREIRA; LEMOS, 2012)	66y	F	R	14 cm along its diameter	Ressection	CD 34+	2,5y
3	Beltran, 2015 (BELTRÁN, 2015)	58y	M	Caudate	15 x 9 x 6	Ressection	CD 34+; Vimentin +	3y
4	Camerlo, 2020 (CAMERLO et al., 2020)	30y	M	L	9cm of diameter	Ressection	NR	NR
5	Chan, 2007 (CHAN et al., 2007)	70y	M	R	28cm of diameter	Ressection	NR	9m

6	Chen, 2017 (CHEN; SLATER, 2017)	61y	M	L	12 x 9	Resection	CD 34+; CD 99 +; Bcl-2 +;	6y
7	Debs, 2014 (DEBS et al., 2014)	87y	F	R	14.6 x 12.3 x 17	No intervention	CD 34+	6m
		65y	M	L	NR	Resection	CD 34+; Vimentin +	12m
8	Esteves, 2017 (ESTEVEES et al., 2017)	68y	F	R	13.3 x 11.6 x1 3.5	Resection	CD 34+; STAT 6 +	37m
10	Fu, 2023 (FU et al., 2023)	73y	M	L	14.6 × 13 × 10	Resection	CD 34+; STAT 6 +	13m
11	Fuksbrumer, 2000 (FUKSBRUMER; KLIMSTRA; PANICEK, 2000)	40y	F	R	NR	Resection	CD 34+; Vimentin +; Bcl-2 +	NR
12		71y	F	R	NR	Resection	CD 34+; Vimentin +; Bcl-2 +	NR
13	García, 2019 (ANDALUZ GARCÍA; TAVECCHIA; OLVEIRA MARTÍN, 2019)	56y	F	L	11 x 9 x 4	Resection	NR	NR
14	Guglielmi, 1998 (GUGLIELMI et al., 1998)	61y	F	R	20.3 x 16.3 x 10	Resection	CD 34+; Vimentin +	6y
15	Hoseini, 2020 (HOSEINI et al., 2020)	69y	M	L	10 x 10	Resection	CD 34+; Vimentin +	23m
16	Jakob, 2013 (JAKOB, 2013)	62y	F	L	15 x 10 x 20	Resection	CD 34+; Vimentin +; Bcl-2 +	NR
17	Korkolis, 2008 (KORKOLIS et al., 2008)	82y	F	L	18 x 15 x 8	Resection	CD 34+; Vimentin +; Bcl-2 +; Desmin +	21m
18	Lin, 2022 (LIN et al., 2022)	59y	F	R	14 x 8 x 7	Resection	CD 34+; STAT 6 +; Vimentin +; CD99 +; Bcl-2 +; β-catenin +	12m
19	Liu, 2013 (LIU et al., 2013)	42y	M	L	10 x 6 x 3	Resection	CD 34+; Bcl-2 +	NR
20		74y	F	R	24 x 16	Resection + chemotherapy	Vimentin +	15m
21	Maccio, 2015 (MACCIO et al., 2015)	80y	F	R	19 x 15	Palliative chemotherapy	CD 34+; STAT 6 +; Vimentin +; Bcl-2 +	4m
22		65y	M	R	3 x 2	Chemotherapy	CD 34+; STAT 6 +; Vimentin +; Bcl-2 +	5m
23	Makino, 2015 (MAKINO et al., 2015)	55y	M	R	8 x 6	Resection	CD 34+; CD99 +; Bcl-2 +	11m
24	Nam, 2020 (NAM et al., 2020)	45y	M	R	2.8cm of diameter	Resection	CD 34+; CD99 +	NR
25	Nath, 2005 (NATH; RUTZICK; SIELAFF, 2006)	61y	F	R	21 × 14.5 × 30	Resection	CD 34+; Vimentin +	10m
26	Novais, 2008 (NOVAIS et al., 2010)	34y	F	R	25 x 23 x 13	Resection	CD 34+; Vimentin +	11m
27	Peng, 2011 (PENG et al., 2011)	24y	F	R	30 × 17x15	Resection + chemotherapy	CD 34+; Vimentin +; Bcl-2 +	16m
28	Perini, 2008 (PERINI et al., 2008)	40y	F	Caudate /L	NR	Resection	CD 34+; Vimentin +	49m

29	Shu, 2019 (SHU et al., [s.d.])	17y	F	L	21 x 15 x 12	Ressection	CD99 +; Bcl-2 +; Desmin +; p53 +	14m
30	Silvanto, 2015 (SILVANTO; KARANJIA; BAGWAN, 2015)	65y	M	L	18cm of diameter	Ressection	CD 34 +; CD99 +; Bcl-2 +	16m
31	Song, 2014 (SONG; ZHANG; ZHANG, 2014)	49y	M	R/L	7.6 x 5.0 x 4.8 and 0.6 x 0.6	NR	CD 34+; Vimentin +; Bcl-2 +	3m
32	Sun, 2011 (SUN et al., 2011)	59y	M	L	9 × 7 × 6	Ressection	CD 34+; CD99 +; Vimentin +; Bcl-2 +	24m
33	Terkivatan, 2006 (TERKIVATAN et al., 2006)	74y	M	L	24 x 21 x 15	Ressection	CD 34+; CD99 +; Vimentin +; Bcl-2 +	12m
34	Vennarecci, 2005 (VENNARECCI et al., 2005)	65y	M	R	30 x 28 x 14	Ressection	CD 34+; Vimentin +	30m
35	Wang, 2021 (WANG et al., 2021)	37y	F	L	NR	Ressection	CD 34+; Vimentin +; Bcl-2 +	Up to the date of publication of the article
36		54y	M	R	NR	Ressection	CD 34 +; CD99 +; Bcl-2 +	6y
37	Ye, 2023 (YE et al., 2023)	49y	M	L	16.5 x 12 x 17	Ressection	CD 34+ STAT 6 + Desmin +	6m
38	Yilmaz, 2000 (YILMAZ et al., 2000)	25y	F	R/L	32 x 30	Ressection + chemotherapy	Vimentin +	6m
39	Yugawa, 2019 (YUGAWA et al., 2019)	49y	F	R	Maximum diameter of 14 cm	Ressection	STAT 6 + Vimentin +	12m

Legend: M male; F female; HRL hepatic round ligament; R right; L left; R/L right and left; NR not reported; IHC immunohistochemistry; y years; m months; + positive

Table 1. Literature review of the reported cases of solitary fibrous tumor in the liver.