

## OSTEOCHONDROMA DUE TO FANCONI ANEMIA: A CLINICAL CASE REPORT

---

***Lorena Faride Maggiorani Davila***

Universidad de la Sabana, Facultad de  
Medicina - Bogotá, Colombia

<https://orcid.org/0000-0003-4289-5394>

***Sofía Maldonado A***

Universidad de la Sabana, Facultad de  
Medicina - Bogotá, Colombia

<https://orcid.org/0000-0002-4402-4130>

***Fabio Antonio Espósito***

Universidad de la Sabana, Facultad de  
Medicina - Bogotá, Colombia

<https://orcid.org/0009-0009-1747-0440>

***María Camila Gomez Ruiz***

Universidad de la Sabana, Facultad de  
Medicina - Bogotá, Colombia

<https://orcid.org/0009-0005-9141-3680>

***Angélica María Vargas Durán***

Universidad de la Sabana, Facultad de  
Medicina - Bogotá, Colombia

<https://orcid.org/0009-0001-7122-0823>

***Camila Andrea Zambrano***

Universidad de la Sabana, Facultad de  
Medicina - Bogotá, Colombia

<https://orcid.org/0009-0002-9525-8946>

***María Camila Guarnizo Cardenas***

Universidad de la Sabana, Facultad de  
Medicina - Bogotá, Colombia

<https://orcid.org/0009-0006-8246-0650>

All content in this magazine is licensed under a Creative Commons Attribution License. Attribution-Non-Commercial-Non-Derivatives 4.0 International (CC BY-NC-ND 4.0).



**María Juliana Lozano**

Universidad de la Sabana, Facultad de  
Medicina - Bogotá, Colombia  
<https://orcid.org/0009-0003-3068-2591>

**Juan Sebastián Rodríguez Salazar**

Universidad de la Sabana  
Bogotá, Colombia  
<https://orcid.org/0009-0003-3879-3704>

**Luis Gustavo Celis**

Universidad de la Sabana, Facultad de  
Medicina - Bogotá, Colombia  
<https://orcid.org/0000-0002-0338-6258>

**Resume:** Fanconi anemia (FA) is a rare genetic disorder, involving all three blood cell lines. It is the most common cause of inherited bone marrow failure (IBMF) characterized by pancytopenia (1). Abnormalities of FA genes (at least 15 identified) are inherited in an autosomal recessive manner, except for *FANCB* mutations, which are inherited in an X-linked manner (2). While rare, FA is the most common IBMFS, the incidence has been estimated to be 1 in 300,000 live births, and the prevalence of 1 to 9 per million (3). Mortality in this subset of patients is associated with solid tumors and leukemia, being the leading cause of death (1). We describe the diagnosis of an osteochondroma in an 18-year-old male with FA in Colombia.

**Keywords:** Fanconi anemia, Thrombocytopenia, Pancytopenia, Genetic disease, Osteochondroma, Transplant.

## CASE REPORT

We present a case of an 18-year-old male, who presented to the clinic with the chief medical complaint of pain in the left knee associated with limited range of motion. After an initial assessment, osteochondroma of the left knee was diagnosed and during the preoperative evaluation an isolated thrombocytopenia was found and the patient was remitted for follow-up studies with hematology. After a long workup, in 2012 FA was diagnosed with a karyotype with mitomycin C, in which chromosomal fragility was evidenced with a relevant increase of cell rupture. The patient had a normal prenatal history, with evidence of polydactyly at birth, but no other major abnormalities were noted. During development, he had low weight and height for his percentile, five café au lait spots in the skin, and a urological examination showed hypospadias that was surgically corrected with no complications. The primary symptom that was frequently experienced was spontaneous

epistaxis that resolved with compression at the site. During his development, the patient was often assessed with protein electrophoresis and complete blood counts with the manual recount of platelets monitoring the risk of developing leukemia which never happened.

Thrombocytopenia continued to be the main sign that was found throughout the years. In the upcoming years, platelets continued to decrease, eventually requiring a bone marrow transplant that was performed at the age of 10 years, using a BM graft from his younger brother who shared the same parents and happened to be an HLA match and did not present the condition. Immunosuppressive therapy was begun before the transplant to prevent acute and long-term rejection, as well as graft versus host disease. The patient was required to stay as an in-patient in the hospital for 3 months and was discharged home with follow-up visits and CBC monitoring. Four years later the osteochondroma of the left knee was surgically excised without complications. Currently, the patient maintains a healthy life and goes to med school in Colombia.

This case presentation of FA is atypical due to the rapid recovery of the patient and the few clinical manifestations that he presented with.

## RESULTS

A karyotype with mitomycin C performed on the patient showed breaks per metaphase and ring chromosomes. Karyotype with chromosome complements 46, XY in the 100 mitoses analyzed. In this cytogenetic study, the presence of balanced or unbalanced translocations was NOT observed. It was also not possible to detect deletions. On the other hand, out of 50 mitoses studied for fragility analysis, a significant increase in the number of ruptures per cell was found, with a rupture index of 1/20 for the conventional one and 641/37 for the mitomycin C one. number of radial figures of 41/2 and pulverized greater

than 30% (10/1). Karyotype compatible with cytogenetic lesions seen in Fanconi anemia. This report refers exclusively to major genetic abnormalities and does not cover gene mutations, microdeletions, or microduplications (Figure 1).

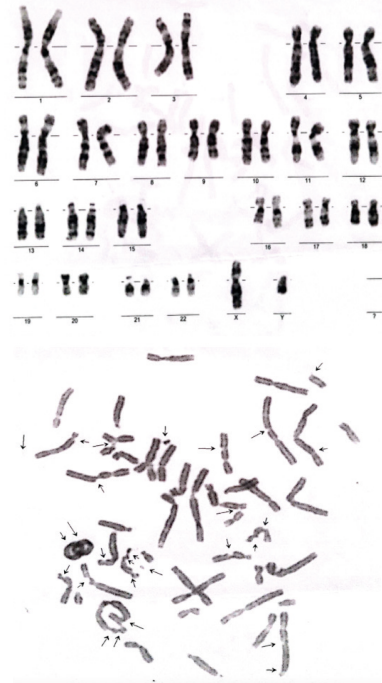
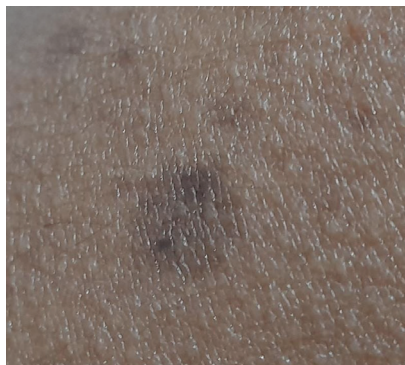

Figure 1. Karyotype with mitomycin.

## DISCUSSION

Fanconi anemia is an inherited genetic disorder that primarily affects the bone marrow's ability to produce blood cells, therefore it is considered the most frequent inherited cause of bone marrow failure. This happens due to mutations in specific genes called FANCA, among these genes, the FANCA, FANCC, FANCG, and FANCD2 are the ones with the most severe compromise shown in FA (4). In many patients, the diagnosis is made between 5 and 15 years of age, and very often presents with a merger of multiple congenital abnormalities such as deformities in the appendicular skeleton more specifically the upper extremities, skin hyperpigmentation (café-au-lait spots) (Figure 2A), also tend to present with genitourinary, renal, and cardiac

malformations, signs described can have a subtle or severe manifestation, in the majority of patients diagnosis will be made after the onset of pancytopenia (5).

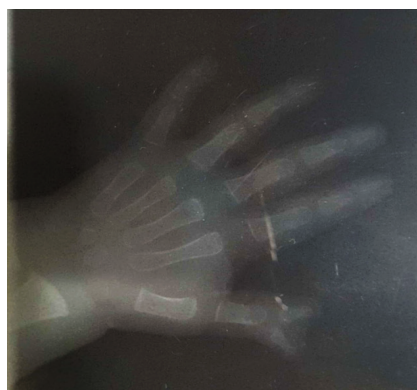

**Figure 2A.** Café-au-lait spots

The case we present is an unusual form of Fanconi Anemia due to several factors including the relatively mild clinical manifestations and rapid recovery from bone marrow transplantation. Most patients with FA tend to develop neoplastic syndromes, commonly white blood cell disorders such as leukemia during childhood. Leukemia risk is especially high in patients with biallelic mutations in *FANCD1/BRCA2*; these individuals have an 80 percent cumulative incidence of leukemia by age 10. MDS and leukemia are common with FA. In some cases, MDS or acute myeloid leukemia (AML) is the presenting finding. Lymphoid malignancies also occur, but they are much less common in most FA subtypes (3). Patients with the other genotypes (*FANCA* through *FANCC*) have cumulative risks of more than 50% marrow failure, 20% of AML, and 30% of solid tumors (usually head and neck or gynecologic squamous cell carcinoma), by age 40 (6).

As previously mentioned, a wide variety of manifestations tend to present in this subset of patients. In this particular case, he presented almost all of the common signs including from the appendicular skeleton (polydactyly) (Figure 2B), café au lait spots, hypospadias,

thrombocytopenia and osteochondroma of the knee (chief complaint). It is important to take into account that most patients tend to have a variety of manifestations, some tend to develop book manifestation but others tend to have isolated manifestations which can potentially misguide the diagnosis of FA due to not seeing the presentation as a syndrome but as separate pathologies. This patient did not debut with a malignant neoplasm, but seeing the whole picture he had most manifestations regarding the syndrome. The case demonstrates the importance of early diagnosis and early appropriate medical management to improve outcomes for individuals with FA.



**Figure 2B.** Polydactyly

## CONCLUSIONS

It is concluded that FA is an inherited bone marrow failure in which cells cannot properly repair interstrand crosslinks in DNA. This results in increased sensitivity to cytotoxic therapies, predisposition to malignancies, characteristic congenital abnormalities, and bone marrow failure (3). It is important to take into account that not all patients present with all the manifestations described but can, sometimes, have what seem like isolated manifestations. That is the reason why FA might not always be the first diagnosis. Care must be taken to correctly identify this subset of patients and improve outcomes and survival.

## REFERENCES

- Bhandari J, Thada PK, Puckett Y. **Fanconi Anemia**. [Updated 2022 Aug 10]. In: StatPearls [Internet]. Treasure Island (FL): StatPearls Publishing; 2023 Jan-. Available from: <https://www.ncbi.nlm.nih.gov/books/NBK559133/>.
- Lee HJ, Park S, Kang HJ, Jun JK, Lee JA, Lee DS, Park SS, Seong MW. **A case report of Fanconi anemia diagnosed by genetic testing followed by prenatal diagnosis**. *Ann Lab Med*. 2012 Sep;32(5):380-4. doi: 10.3343/alm.2012.32.5.380. Epub 2012 Aug 13. PMID: 22950077; PMCID: PMC3427829.
- Olson, T.S. (2022) **Clinical manifestations and diagnosis of Fanconi anemia**, UpToDate. Available at: <https://www.uptodate.com/contents/clinical-manifestations-and-diagnosis-of-fanconi-anemia> (Accessed: 09 August 2023).
- Soulier J. (2011). **Fanconi anemia**. *Hematology*. American Society of Hematology. Education Program, 2011, 492–497. <https://doi.org/10.1182/asheducation-2011.1.492>.
- Foreman J. W. (2019). **Fanconi Syndrome**. *Pediatric clinics of North America*, 66(1), 159–167. <https://doi.org/10.1016/j.pcl.2018.09.002>
- Alter B. P. (2014). **Fanconi anemia and the development of leukemia. Best practice & research**. *Clinical haematology*, 27(3-4), 214–221. <https://doi.org/10.1016/j.beha.2014.10.002>.