

EPIDEMIOLOGICAL AND RADIOLOGICAL PATTERNS OF LABYRINTITIS OSSIFICANS: A RETROSPECTIVE STUDY

Renan Machado Martins

Institution: Centro Estadual de Reabilitação e
Readaptação Dr. Henrique Santillo (CRER)
Goiânia - Goiás
<http://lattes.cnpq.br/6034170654764319>

Isabela de Freitas Dias

Institution: Centro Estadual de Reabilitação e
Readaptação Dr. Henrique Santillo (CRER)
Goiânia - Goiás
<http://lattes.cnpq.br/9518501540544285>

Vitor Oliveira Machado

Institution: Centro Estadual de Reabilitação e
Readaptação Dr. Henrique Santillo (CRER)
Goiânia - Goiás
<http://lattes.cnpq.br/7047452437259016>

Brainner Vinnicius Campos Barbosa

Institution: Centro Estadual de Reabilitação
e Readaptação Dr. Henrique Santillo (CRER)
Goiânia - Goiás
<http://lattes.cnpq.br/7123452132385323>

Thiago Oliveira Costa

Institution: Centro Estadual de Reabilitação e
Readaptação Dr. Henrique Santillo (CRER)
Goiânia - Goiás
<http://lattes.cnpq.br/9990427425642115>

Daniela Pereira de Azevedo

Institution: Centro Estadual de Reabilitação e
Readaptação Dr. Henrique Santillo (CRER)
Goiânia - Goiás

All content in this magazine is
licensed under a Creative Com-
mons Attribution License. Attri-
bution-Non-Commercial-Non-
Derivatives 4.0 International (CC
BY-NC-ND 4.0).



Danilo Alvin de Paiva Gonçalves Filho

Institution: Centro Estadual de Reabilitação e Readaptação Dr. Henrique Santillo (CRER)
Goiânia - Goiás
<http://lattes.cnpq.br/2827085563718121>

Felipe Andrade de Paula

Faculdade de Medicina da Universidade de Rio Verde (UniRV)
Aparecida de Goiânia - Goiás
<http://lattes.cnpq.br/6367420743039992>

Rafael Oliveira de Sousa

Faculdade de Medicina da Universidade de Rio Verde (UniRV)
Aparecida de Goiânia - Goiás
<http://lattes.cnpq.br/0643929423114103>

André Luiz Porto Bizinoto

Faculdade de Medicina da Universidade de Rio Verde (UniRV)
Aparecida de Goiânia - Goiás
<http://lattes.cnpq.br/3968569658923490>

Abstract: Labyrinthitis ossificans represents the pathological ossification of the membranous labyrinth. Although best evaluated by Magnetic Resonance Imaging, Computed Tomography also represents a form of diagnosis. This study aims to evaluate the findings of the disease in tomographic examinations in a public institution, evaluating its radiological and epidemiological profile, with the aim of assisting in future diagnoses, while early evaluation of these cases can favor surgical success.

We selected 17 patients with a confirmed diagnosis, with a retrospective analysis of their medical records and reevaluation of tomographic images, paying attention to the laterality of the involvement, sex, age and presumed etiology. In all cases, calcified material or bone density was found compromising the membranous labyrinth in a focal or diffuse manner, compatible with a diagnosis of labyrinthitis ossificans.

Of the 17 patients, 7 were female and 10 were male. The age range ranged from 31 years to 69 years, with an average presentation of 50 years of age.

Of the presumed etiologies, 5 cases were due to head trauma, 1 case was due to a previous history of neurosurgery to remove a neoplastic lesion and 8 cases were due to middle ear infection. Another 3 cases were related to sequelae of bacterial meningitis.

In cases related to middle ear infection, the involvement was always ipsilateral to the underlying condition, as well as in cases of trauma or previous surgery. This was not observed in cases of bacterial meningitis sequelae.

Although the findings are shared in the reported cases, with a mean age of presentation of 50 years, with the majority being male patients, important differences were noted in relation to the affected side, in turn with a direct relationship with the

presumed etiology. Knowing this radiological and epidemiological behavior profile can be useful in tomographic evaluation, improving diagnostic accuracy.

Keywords: labyrinth; imaging diagnosis; labyrinth diseases; inner ear; otolaryngology.

INTRODUCTION

Labyrinthitis ossificans is an extremely rare condition characterized by pathological ossification of the membranous labyrinth in response to insults to the inner ear. This challenging otologic pathology is of significant clinical interest, as accurate and detailed diagnosis is critical for appropriate selection of therapeutic interventions.

In clinical practice, evaluation of labyrinthitis ossificans generally requires the use of imaging techniques to document the extent and nature of ossification. Although Magnetic Resonance Imaging (MRI) is often considered the imaging modality of choice due to its excellent soft tissue resolution and ability to differentiate between the different components of the inner ear, Computed Tomography (CT) also plays a relevant role in this context. CT offers substantial advantages in terms of accessibility, cost and speed, making it a useful tool for initial diagnosis and monitoring of disease progression.

METHODOLOGY AND OBJECTIVES

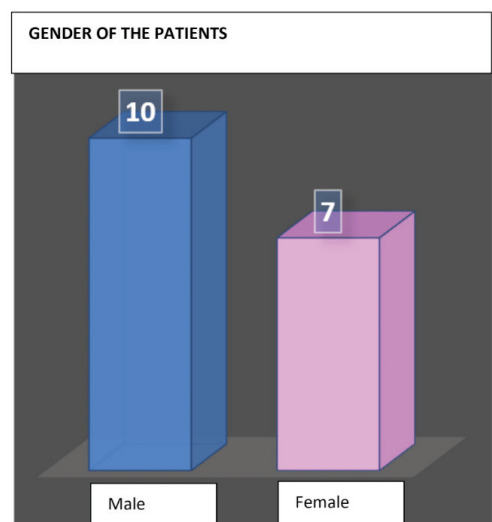
This study, conducted at a public health institution, aims to fill a knowledge gap in the field of otologic radiology by providing a valuable contribution to a deeper understanding of labyrinthitis ossificans. The main objective is to characterize the radiological and epidemiological profile of this condition, with the aim of improving diagnostic accuracy and increasing awareness about this rare pathology.

17 patients with a confirmed diagnosis of

labyrinthitis ossificans were included in this study. Data collection included a retrospective analysis of their medical records and a detailed re-evaluation of the tomographic images. During this process, the researchers focused their attention on the imaging findings, the laterality of the involvement, gender, age and presumed etiology.

RESULTS AND DISCUSSION

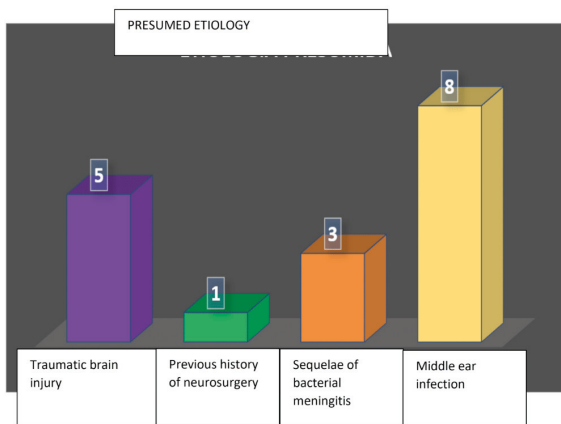
Among the 17 patients included in the study, seven were female and ten were male. The age range varied between 31 and 69 years old, with an average presentation of around 50 years old. These epidemiological characteristics are in line with previous reports, highlighting the predominance of the disease in men and the common age range of presentation.



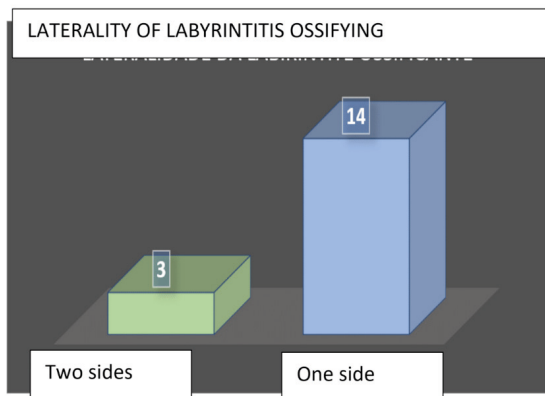
Graph 1: Sex of patients diagnosed with labyrinthine ossificans.

The presumed etiologies for labyrinthitis ossificans varied among the patients studied. Five cases were related to head trauma, one case was associated with a previous history of neurosurgery to remove a brain neoplastic lesion and eight cases were attributed to middle ear infection. Another three cases were related to sequelae of bacterial meningitis. It is worth

mentioning that in cases associated with middle ear infection, the involvement always occurred on the same side as the baseline, as in cases of trauma or previous surgery. This observation did not apply to cases of sequelae of bacterial meningitis, where there was bilateral involvement. Such data are further detailed in the graphs below and exemplified in the images that follow.



Graph 2: Presumed etiology of patients diagnosed with labyrinthine ossificans.



Graph 3: In cases of labyrinthitis ossificans related to middle ear infection, trauma or previous surgery (14 cases), the involvement was always ipsilateral to the underlying event. However, in cases of sequelae of bacterial meningitis (3 cases), the involvement was bilateral.

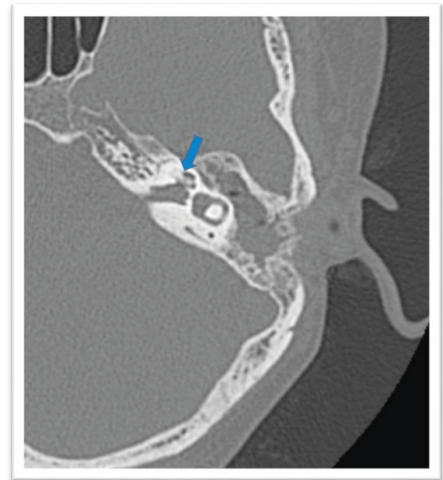

Figure 1: Computed tomography of the temporal bones, in axial section, without intravenous contrast, of a female patient, 52 years old, with a history of otitis media on the left, in the late postoperative period of radical mastoidectomy. Hyperdense material can be seen almost completely obliterating the basal and middle turns of the cochlea (blue arrow), compatible with labyrinthitis ossificans (LO), ipsilateral to the previous infection.

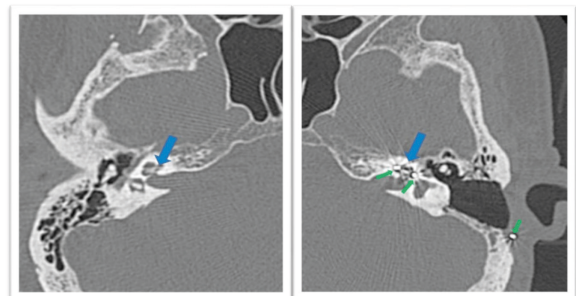


Figure 2: Computed tomography of the temporal bones, in axial section, without intravenous contrast, of a 68-year-old male patient, with a history of meningitis for six years, using a cochlear implant (green arrows) on the left. Hyperdense material can be seen almost completely obliterating the basal and middle turns of the cochlea (blue arrows), bilaterally, compatible with labyrinthitis ossificans (LO).

Analysis of the results of this study revealed that, although the radiological findings were similar between the cases

studied, with an average presentation around 50 years of age and a predominance of male patients, important differences were noted in relation to the affected side, directly related to the presumed etiology. These observations reinforce the importance of a careful and comprehensive assessment when considering the diagnosis of labyrinthitis ossificans, as the underlying etiology can vary considerably and affect treatment decisions.

CONCLUSION

This study provides a comprehensive analysis of the radiological and epidemiological findings of labyrinthitis ossificans in a population of patients treated at a public health institution. Understanding these patterns is essential to improve diagnostic accuracy and the quality of care provided to patients with this rare otological condition. Furthermore, it highlights the importance of strategically utilizing imaging techniques such as CT in diagnosing and monitoring labyrinthitis ossificans, especially in clinical settings where MRI may not be readily available.

REFERENCES

- AGARWAL, Amit; KANEKAR, Sangam. **Headache Attributed to Disorder of the Cranium and Base of the Skull**. *Neurologic clinics*, v. 40, n. 3, p. 563-589, 2022.
- ARALASMAK, Ayse et al. **Posttraumatic labyrinthitis ossificans with perilymphatic fistulization**. *Diagnostic and Interventional Radiology*, v. 15, n. 4, p. 239, 2009.
- BUCH, Karen et al. **Etiology-specific mineralization patterns in patients with labyrinthitis ossificans**. *American Journal of Neuroradiology*, v. 40, n. 3, p. 551-557, 2019.
- PHILIPPON, Daniel et al. **Cochlear implantation in postmeningitic deafness**. *Otology & Neurotology*, v. 31, n. 1, p. 83-87, 2010.
- SWARTZ, Joel D. et al. **Labyrinthine ossification: etiologies and CT findings**. *Radiology*, v. 157, n. 2, p. 395-398, 1985.