

## INTRATHORACIC GASTRIC PERFORATION IN RECURRENT HIATAL HERNIA: CASE REPORT

---

*Pedro Henrique Salgado Rodrigues*  
General Surgery Service of the Federal  
Hospital of Andaraí - RJ

*Priscila Fonseca de Sousa*  
General Surgery Service of the Federal  
Hospital of Andaraí - RJ

*André Maciel da Silva*  
General Surgery Service of the Federal  
Hospital of Andaraí - RJ

*Adriana de Freitas Fantinelli*  
General Surgery Service of the Federal  
Hospital of Andaraí - RJ

*Felipe Chinaidre Eyer*  
General Surgery Service of the Federal  
Hospital of Andaraí - RJ

All content in this magazine is licensed under a Creative Commons Attribution License. Attribution-Non-Commercial-Non-Derivatives 4.0 International (CC BY-NC-ND 4.0).



**Abstract:** With up to 57% radiological recurrence rate in some studies, the management of hiatal hernia still lacks consistency in the literature. Among the complications of recurrence, intrathoracic gastric perforation secondary to strangulation of the herniated content can lead to ventilatory instability and offer high morbidity and mortality to the patient. **Clinical case:** Female patient, 78 years old, with a history of hiatal hernia and GERD, approached six months ago with videolaparoscopic fundoplication, evolving with abdominal pain, dyspnea and hemodynamic instability. Diagnosed with recurrent and perforated hernia in the left hemithorax, she underwent total gastrectomy with peritoneostomy, with revision and reconstruction of the Roux-en-Y transit in a second moment. Despite intensive support, the patient died after seven days. **Conclusion:** Although several surgical strategies have been incorporated in recent years in the management of hiatal hernia cases, the subject remains controversial, requiring constant updating, especially in relation to serious complications, even if they appear late in the procedure.

**Keywords:** Recurrent Hiatal Hernia, Laparoscopic Fundoplication, Intrathoracic Gastric Perforation

## INTRODUCTION

The causes of hiatal hernia recurrence after surgical correction for the treatment of Gastroesophageal Reflux Disease remain poorly understood, and are believed to be related to multiple factors.<sup>1</sup> The distribution of the location of hiatal hernia recurrence suggests that there are two possibilities: early posterior recurrence (associated with failure of posterior crural closure), and progressive late anterior enlargement of the hiatus, related to increased transhiatal pressure<sup>2</sup>. Thanks to the relatively high recurrence rate, several

strategies are studied to improve the results. Among them, in addition to the classically described fundoplication, examples such as mesh fixation, anterior crural closure, gastropexy, gastrostomy, relaxation incision and Collis esophageal stretching<sup>3,4</sup>. However, there is no consensus in the literature that such practices, adopted routinely, alone or in association, establish a real decrease in the number of patients with disease recurrence in the long term.

## CASE REPORT

Female patient, 78 years old, with a history of hiatal hernia and GERD, treated with videolaparoscopic fundoplication (Floppy Nissen, without the use of a mesh, with anterior and posterior narrowing of the diaphragmatic pillars with non-absorbable suture performed in separate stitches), returns to the Hospital Federal do Andaraí six months after surgery. She reported dyspnea, abdominal pain, postprandial nausea and vomiting. Computed tomography performed on an urgent basis (Figure 1) revealed recurrence of the hiatal hernia, with signs suggestive of suffering and perforation. The patient evolves with worsening dyspnea, hemodynamic instability and metabolic acidosis. Intubated, she underwent upper digestive endoscopy, with visualization of gastric necrosis.

During exploratory laparotomy, after reducing the abdominal contents that had herniated into the left chest, extensive vascular involvement of the stomach was identified (Figure 2), with perforation and gross contamination of the thoracic cavity with gastric residue. The patient underwent total gastrectomy (Figure 3) with repair of the esophageal stump in the diaphragmatic pillars (Pinotti) + jejunostomy. Copious lavage of the left hemithorax was performed through the diaphragmatic hiatus, followed by anterior and posterior drainage of the left lung in a water

seal, with the creation of a peritoneostomy (Figure 4) and vacuum dressing for a second look.

With improvement in ventilatory and hemodynamic parameters after 96 hours, the patient was approached for Roux-en-Y reconstruction of the gastrointestinal tract, with drainage of the cavity and closure of the peritoneostomy. Despite intensive postoperative care and broad-spectrum antibiotic therapy, the patient evolved with hemodynamic worsening, instability and death on the seventh postoperative day.

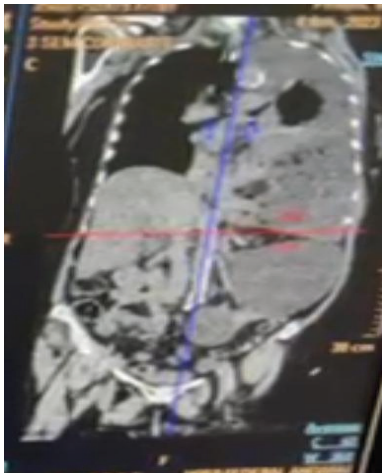


Figure 1: Non-contrast-enhanced computed tomography, coronal section, with a finding suggestive of recurrent hiatal hernia perforated in the left hemithorax.

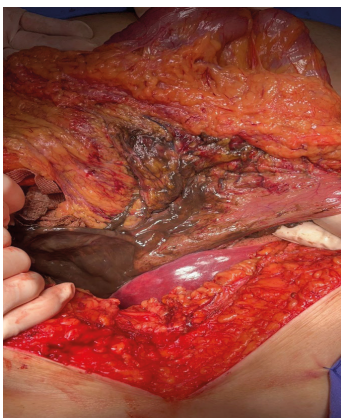


Figure 2: Nasogastric tube passed during EDA showing the site of gastric perforation. Complete necrotic liquefaction of the greater curvature of the stomach.

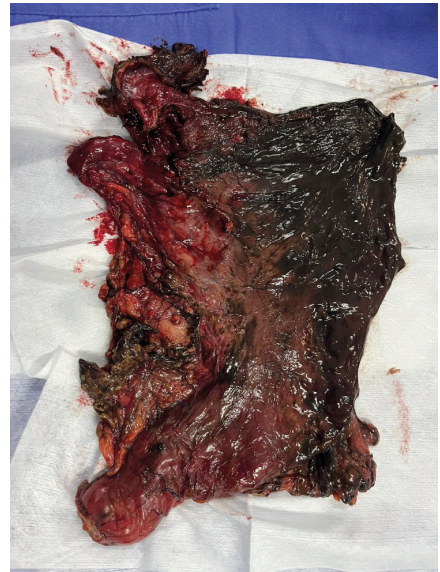

Figure 3: Total gastrectomy product

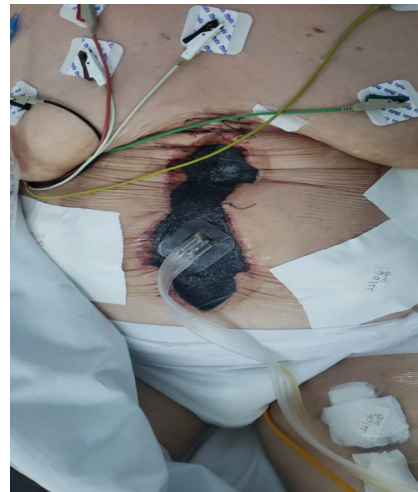

Figure 4: Peritoneostomy with vacuum dressing for second look

## DISCUSSION

Despite the number of cases of recurrence (mainly those incidentally diagnosed in imaging tests performed in the postoperative period) of hiatal hernia being notorious, many studies have shown the effectiveness of laparoscopic surgery for the treatment of gastroesophageal reflux disease. The results point to 90% satisfaction among these patients<sup>5</sup>, with a short hospital stay and quick return to activities, which justifies the continuity of this surgical practice.

During revision surgery for hiatus hernia recurrence, it is possible to classify<sup>7</sup> the defect primarily into:

1. Intact hiatus (fibrosis/narrow hiatus).
2. Hernia with intussusception (“Telescope”)
3. Paraesophageal hernia, often lateral/posterior to the defect
4. Crural insufficiency with intact herniation
5. Crural failure with herniation and ruptured valve.
6. Valve rupture only (intact hiatus and maintained intra-abdominal position).

According to Suppiah et al<sup>7</sup>, anterior recurrence was the most common type found in their patients. There is also an association between the time elapsed between surgery and the topography of the defect, with “anteroposterior” defects being the most common in those who presented recurrence in less than one year after the surgical approach. On the other hand, exclusively anterior defects have become more common in patients with older surgeries. This suggests that early recurrence would be related to rupture of the posterior crural repair, while late recurrence would be the result of progressive enlargement of the hiatus, which would occur secondary to the maintenance of the transhiatal pressure gradient.

This theory of anterior widening of the hiatus could help explain the failure of mesh reinforcement in posterior crural repair. Oelschlager et al<sup>8</sup> published a randomized

study on paraesophageal hernia repair with posterior reinforcement using a biological mesh with the letter “U”. At six months postoperatively, there was a significant difference in recurrence rates between reinforced and primary repairs. This evidences that the mesh reduced the rate of early posterior suture closure failures. However, after five years, there was no difference<sup>9</sup>, with progression of the hiatal defect due to anterior enlargement also occurring in the patients followed. For Koch et al<sup>10</sup>, this controversy stems mainly from the lack of evidence from well-designed studies using long-term functional outcomes.

## CONCLUSION

Recurrence of hiatus hernia after videolaparoscopic fundoplication, even if late, may evolve with intrathoracic gastric perforation and rapidly progress to ventilatory and hemodynamic instability. The best chances of proper management reside in early diagnostic suspicion, individualized approach and intensive postoperative care. Given the increasing number of hiatalplasties, studies are increasingly needed to establish consistency in the literature, with levels of evidence that allow the reproducibility of positive results. The association of biological mesh for reinforcement has no proven long-term benefit, and would not necessarily have changed the outcome of this patient.

## REFERENCES

1. Lidor AO, Steele KE, Stem M, et al. Long-term quality of life and risk factors for recurrence after laparoscopic repair of paraesophageal hernia. *JAMA Surg* 2015; 150:424e431.
2. Adham R Saad, Vic Velanovich, Anatomic Observation of Recurrent Hiatal Hernia: Recurrence or Disease Progression? *J Am Coll Surg*. Vol. 230, No. 6, June 2020
3. Zama J, Lidor AO. The optimal approach to symptomatic paraesophageal hernia repair: important technical considerations. *Curr Gastroenterol Rep* 2016;18:53.
4. Johnson AB, Oddsdottir M, Hunter JG. Laparoscopic Collis gastroplasty and Nissen fundoplication. A new technique for the management of esophageal foreshortening. *Surg Endosc* 1998;12:1055e1060.
5. Dallemagne B, Weerts J M, Jehaes C, Markiewicz S. Causes of failures of laparoscopic antireflux operations. *Surg Endosc* 1996; 10: 305-10.
6. Peters J H, DeMeester T R. Indications, benefits and outcome of laparoscopic Nissen fundoplication. *Dig Dis* 1996; 14: 169-79.
7. Suppiah A, Sirimanna P, Vivian SJ, et al. Temporal patterns of hiatus hernia recurrence and hiatal failure: quality of life and recurrence after revisional surgery. *Dis Esophagus* 2017;30: 1e8.
8. Oelschlager BK, Pellegrini CA, Hunter J, et al. Biologic prosthesis reduces recurrence after laparoscopic paraesophageal hernia repair: a multicenter, prospective randomized trial. *Ann Surg* 2006;244:481e490.
9. Oelschlager BK, Pellegrini CA, Hunter JG, et al. Biologic prosthesis to prevent recurrence after laparoscopic paraesophageal hernia repair: long-term follow-up from a multicenter, prospective, randomized trial. *J Am Coll Surg* 2011;213:461e468.
10. Koch OO, Asche KU, Berger J, Weber E, Granderath FA, Pointner R. Influence of the size of the hiatus on the rate of reherniation after laparoscopic fundoplication and refundoplication with mesh hiatoplasty. *Surg Endosc*. 2011;25(4):1024-1030.