

OSTEOCHONDRITIS DISECANTS IN A BRAZILIAN EQUESTRIAN BREED FOAL - CASE REPORT

Bernardo Câmara de Freitas

Graduated in Veterinary Medicine at
UNIFESO

Daniela Melo Vianna Ferrer

Teacher of the Veterinary Medicine course at
UNIFESO

Fernando Luís Fernandes Mendes

Teacher of the Veterinary Medicine course at
UNIFESO

Bianca Cascardo

Autonomous Veterinarian

Agildo Shirlan de Araujo

Veterinarian

All content in this magazine is licensed under a Creative Commons Attribution License. Attribution-Non-Commercial-Non-Derivatives 4.0 International (CC BY-NC-ND 4.0).



Abstract: Osteochondritis dissecans (OCD) are lesions in joints where there are osteochondral fragments favoring inflammation in the affected region. This is considered a very important condition, since it impairs the performance of these animals, and when it is observed in equine herds, it can result in severe economic losses, since its treatment is expensive, and this causes the animal to be retired or discarded. The objective of this study is to report a case of osteochondritis dissecans in a Brazilian horse foal, in addition to evaluating the effectiveness of the surgical treatment used in the reported case. The male horse, of the Brazilian Equestrian breed, pampa coat, one year old, who was admitted to a Veterinary Clinic of Equine Medicine to perform a surgical procedure of arthroscopy of the right Tarsus. As preoperative exams, complete blood count, serum biochemistry and simple radiography of the affected region were performed. After the examinations, an arthroscopic surgical procedure was performed, in which consolidation of the fragment was observed, therefore, there was only a diagnostic effect, and the use of Phenylbutazone (Equipalazone®), enriched vitamin and mineral supplement (Artroplus®) and Pentosan Polysulfate Sodium (Cartophen®), in addition to the indication that the foal must rest in the stable for 30 days. It is concluded that osteochondritis dissecans is a recurrent pathology in the equine clinic, and in the current case report there was a fundamental role of arthroscopy for decision-making regarding the treatment employed, with consolidation of the osteochondral fragment being the preponderant factor for carrying out conservative treatment.

Keywords: Arthroscopy. Developmental orthopedic disease. Equine.

INTRODUCTION

Osteochondritis dissecans (OCD) is

considered a very important condition, as it impairs the performance of these animals, causing damage at all stages of the production chain in the equine market. When OCD is located in equine herds, it can result in severe economic losses, as its treatment is expensive, and this causes the animal to be retired or discarded many times. Joint effusion is the predominant clinical sign of OCD. In cases where the fragment is free in the joint space or when there are large lesions seen on radiographs, claudication may or may not be present in different degrees and is generally linked to the manifestation of joint effusion, manifesting itself more frequently in the joints. animals that start the practice of physical exercises (1). You can diagnose this joint pathology with imaging tests such as computed tomography, magnetic resonance, radiography and ultrasound, the latter two being the most used, in addition to other complementary methods such as the use of molecular biomarkers for early diagnosis. Factors such as clinical symptomatology, patient's age, work performed by him, degree in which the OCD is found and evaluation of the joints involved vary for the choice of treatment, which can be clinical, conservative or surgical (2). The objective of this study is to report a case of osteochondritis dissecans in a Brazilian horse foal, in addition to evaluating the effectiveness of the surgical treatment used in the reported case.

CASE REPORT

Male equine, Brazilian Equestrian, pampa coat, one year old, was admitted to the Veterinary Clinic of Equine Medicine to perform a surgical procedure of arthroscopy of the right tarsus. It is seen in the athletic potential animal, due to its pedigree. The patient had a history of osteochondritis dissecans (OCD) on the intermediate crest of the tibia, on the right joint, with diagnosis

based on the radiographic examination performed on 11/15/2021 (Figure 1), after the animal started to limp, being performed on the own stud farm where he stays. Therefore, the animal was referred to the Veterinary Clinic of Equine Medicine to perform a surgical procedure of arthroscopy of the right tarsus. It is worth mentioning that the animal is kept under the semi-intensive breeding system, staying in the stall during the night and in the paddock during the day. The animal receives daily alfalfa hay and supplementation with concentrate. After the animal arrived at the veterinary clinic, its physical examination was performed, through routine semiological examinations of the locomotor system, both in station and in exercise, at the walk and at the trot. During the examination, the presence of effusion in the right tarsocrural joint was observed. At the end of the clinical examination, the animal was referred to undergo a new radiographic examination (17/03/2022), in the laterolateral, lateral oblique, medial oblique and dorsal plantar positions, where the presence of an osteochondral fragment in the crest was visualized. intermedia of the tibia, confirming the OCD. Therefore, arthroscopic surgery was recommended as a form of treatment to remove the fragment. However, for unknown reasons, the animal was only referred for surgical treatment four months after the diagnosis of OCD. In addition to the radiographic examination, screening tests were performed, such as a complete blood count and serum biochemistry to assess the general condition of the patient, which presented results within normal parameters, therefore, the animal was able to undergo the anesthetic and surgical procedure necessary for the treatment. On the day of surgery (03/18/2022), a previous physical examination of the patient was performed, where the following results were observed: good general condition, heart rate

44 beats per minute (BPM), respiratory rate 24 movements per minute (MPM), body temperature 38 °C, capillary perfusion test (CPT) 2 seconds, pink mucous membranes, hydrated, no pain and normal motility. Then, the animal was submitted to general anesthesia for later performance of the surgical procedure of arthroscopy of the right tarsus. Therefore, the patient was placed in dorsal decubitus, prior antisepsis and preparation of the surgical field were performed. An access door for the optics and another access door for the working channel were made. After evaluating the joint, a process of consolidation of the osteochondral fragment was observed. For this reason, the osteochondral fragment was not removed, only the joint was evaluated. At the end, dermarrhaphy was performed with PDO (Polydioxanone) 3-0 thread. The foal recovered uneventfully and the day after the procedure another physical examination of the patient was performed, where the following results were found: good general condition, heart rate (HR) 36 BPM, respiratory rate 16 MPM, temperature 37.3 °C, pink mucous membranes, hydrated, digital pulse and hoof temperature within normal limits, normal motility and normal stools. In addition, an occlusive dressing was applied to the wound after this clinical evaluation. The horse was discharged on the same day with the following instruction to the owner: application of 2 g/kg Phenylbutazone (Equipalazone®) orally for two days; 10 g/kg of chondroitin and glucosamine (Artroplus®) orally twice a day for three months, and keep the occlusive dressing for five days. It was recommended that the foal also rest in the stable for thirty days, being allowed to walk daily for ten minutes. The use of 10 mL Pentosan Polysulfate Sodium (Cartophen®) intramuscularly once a week was also prescribed for the animal, with a total of five applications. After thirty days, it was recommended to carry out a new

radiographic examination of the affected region for radiographic monitoring of the site, and thus, it was recommended to repeat this procedure monthly for one year. Currently, the animal is stable with no apparent clinical symptoms.

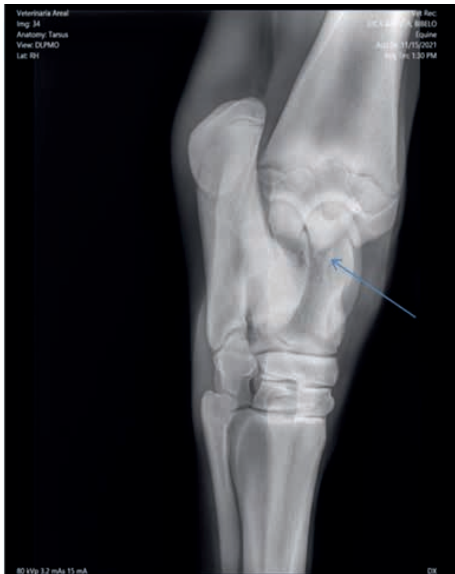

Figure 1 - X-ray of the tarsocrural joint in a BH foal diagnosed with OCD. Laterolateral projection.

Source: Personal archive, 2021.

DISCUSSION

In the present report, the foal was diagnosed at more than one year of age, disagreeing with Mantovani (1), who reports that the characteristic diagnosis of osteochondritis dissecans (OCD) occurs in foals aged approximately two years, which are commercialized and undergo tests radiographic examinations for purchase evaluation, and, as findings of these radiographic examinations, osteochondral fragments are found, even without clinical symptoms present, or in foals of approximately three years old, which, after starting training, begin to present joint effusion and subtle lameness. However, it agrees with Cruz (3) who say that this pathology has a higher occurrence in young animals. The foal in this

report is from the Brasileiro de Equestrian breed, has the potential to become an athlete. There is agreement with Bueno et al. (4) when describing which athlete foals are most affected, however the breed in question is not cited by the authors, who cite as examples the Thoroughbred Racing, Quarter Horse and Thoroughbred Arabian breeds. In the present study, the patient was diagnosed with OCD in the intermediate crest of the tibia, in the right joint, consistent with the information presented by Machado (5) and Cruz (3), who report that the joints commonly involved in OCD are the tibiotarsal, metacarpal/metatarsophalangeal and femorotibiopatellar. In this case, during the physical examination of the foal, the presence of effusion in the tarsocrural joint was observed, in agreement with Pereira et al. (6) who point out that joint effusion is present when dealing with fragments of the distal intermediate crest of the tibia by OCD. In the current report, a radiographic examination was performed to confirm the existence of OCD, where the existence of an osteochondral fragment was observed, in agreement with Caron (7) when describing that radiographs are able to identify severe cases of OCD in addition to detecting discrete changes of joint irregularities that can be observed as radiolucent lesions (subchondral cysts). In this report, performing arthroscopy of the right tarsus (figure 2) was fundamental for the evaluation of the joint, in addition to considering the rapid recovery of the horse after the procedure a positive point, therefore, it is in accordance with Muttini, Vantini and Cuono (8), when they point out that arthroscopic surgery results in low damage to soft tissues, low risk of complications, shorter rest time, effective functional and aesthetic result. In the present case, the existence of a process of consolidation of the osteochondral fragment was verified at arthroscopy, which was not removed due to this consolidation,

agreeing with McilWraith (9) and Van Weren, Jeffcott (10), when reporting that in cases of lesions smaller than two centimeters in length and five millimeters in depth, with no fragmentation, the indication is a conservative approach. For the foal of the present case report, rest was prescribed for thirty days, keeping the occlusive dressing for five days, Equipelazone® 2 g/kg administered orally for two days, Artroplus® 10 g/kg orally, twice per day for three months and Cartophen®, being applied 10 mL intramuscularly, once a week, with a total of five applications, similarly described by Bergin et al. (11) and McilWraith

et al. (12) who describe conservative treatment as rest and reduction of physical exercises. Diet must also be regulated, in addition to instituting nonsteroidal anti-inflammatory therapy for pain relief. After performing the postoperative period properly, the patient was discharged and until the present moment of this case report, the clinical signs have ceased, agreeing with Foerner (13) who says that the prognosis in general is good, but it depends on the postoperative period, where the animal needs to stay at least seven days of rest, being able to return to the practice of exercises gradually.

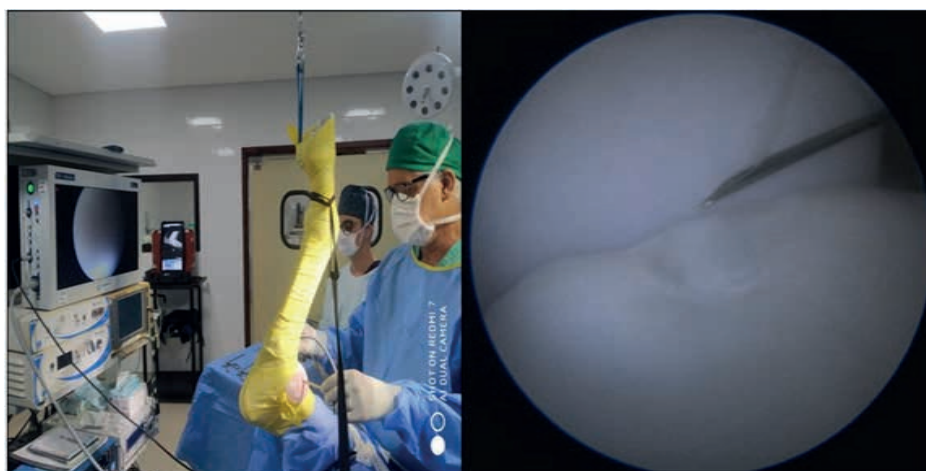


Figure 2 - Arthroscopy of the right tarsus in the BH foal with Osteochondritis Dissecans (OCD)

Fonte: Arquivo pessoal, 2022.

FINAL CONSIDERATIONS

This way, it is considered that osteochondritis dissecans causes economic losses for the breeder, due to expenses with exams and treatment of the pathology, however in the present case report the resolution was simple and, therefore, did not compromise the future athletic life of the patient. In addition, it is concluded that osteochondritis dissecans is a recurrent pathology in the equine clinic, and in the current case report there was a fundamental role of arthroscopy surgery as an important form of inspection for decision-making in relation to the treatment employed,

because the consolidation of the osteochondral fragment was the preponderant factor for its non-removal and, thus, only carrying out the conservative treatment later.

ACKNOWLEDGMENTS

I thank God for absolutely everything. To my teacher advisor, Daniela Mello Vianna Ferrer, who oriented and guided me to overcome my difficulties. My thanks to my teaching institution Centro Universitário Serra dos Órgãos – UNIFESO. Thanks to my family for all the support.

REFERENCES

1. Mantovani CF. Análise metabólica (1H RMN) do líquido sinovial de equinos hígidos e acometidos por osteocondrite dissecante. 2013. 113f. [Dissertação] Mestrado em Ciências - Universidade de São Paulo, Faculdade de Medicina Veterinária e Zootecnia, São Paulo, 2013.
2. Baxter GM. Adam's and Stashak's lameness in horses. 6ªed. Oxford: Wiley-Blackwell; 2020.
3. Cruz RS. Tratamento cirúrgico da osteocondrite dissecante em equinos: estudo retrospectivo e análise crítica. 2011. 95f. [Dissertação] Mestrado em Ciências - Universidade de São Paulo, Faculdade de Medicina Veterinária e Zootecnia, São Paulo, 2011.
4. Bueno A, Beal J, Oliveira LSS, Corte FD. Osteocondrose de articulação fêmoro-tíbio-patelar em potro da raça Crioula. *Ciência Rural*. 2008;38(6):1784-1786.
5. Machado TSL. Análise clínica e estrutural de processos de osteocondrite dissecante da articulação tíbio-társica de equinos. 2010. 139f. [Dissertação] Doutorado em Ciências - Universidade de São Paulo, Faculdade de Medicina Veterinária e Zootecnia, São Paulo, 2010.
6. Pereira LF, Geraldo L, Alves RM, Carvalho LL, Costa ML, Jorge AT, Dias FGG. Osteocondrite dissecante em equinos – revisão de literatura. *Revista Científica de Medicina Veterinária*. 2019;32(15):1-14.
7. Caron JP. Osteoarthritis. In Ross MW, Dyson SJ. *Diagnosis and Management of Lameness in the horse*. 2ª ed. Rio de Janeiro: Elsevier; 2011.
8. Muttini RA, Vantini C, Cuomo A. Arthroscopy in the Horse. *Veterinary Research Communications*. 2003;1(27):79-83.
9. McIlwraith CW. Surgical versus conservative management of osteochondrosis. *Veterinary Journal*. 2013;197(1):19-28.
10. Van Weeren PR, Jeffcott LB. Problems and pointers is osteochondrosis: twenty years on the veterinary journal. *Equine Veterinary Journal*. 2013; 197(1):96-102.
11. Bergin BJ, Pierce SW, Bramlage LR, Stromberg AS. Oral hyaluronan gel reduces post operative tarso crural effusion in the yearling Thoroughbred. *Equine Veterinary Journal*. 2006;38(4):375-378.
12. Brasil, Ministério da Agricultura, Abastecimento e Reforma Agrária (MAPA). Instrução Normativa N°45, de 15 de junho de 2004. Normas para Prevenção e Controle da Anemia Infecciosa Equina - A.I.E. Brasília: Diário Oficial da União. 07 de julho de 2004; Seção 1: 7-9.
13. Foerner JJ. Osteochondrosis in the horse. *Journal of Equine Veterinary Science*. 2003;23(4):142-145.