

# **MONKEYPOX: CLINICAL CHARACTERISTICS, DIFFERENTIAL DIAGNOSIS AND IMPLICATIONS FOR DENTAL PRACTICE: AN INTEGRATIVE REVIEW**

---

***Wagner José Sousa Carvalho***

Dentistry course, Centro Universitário do Sagrado Coração, (UNISAGRADO).

ID Lattes: 2593421070768963

ORCID: 0000-0002-3184-085X

***Sebastião Pires Ferreira Filho***

Medicine Course, Faculdade de Medicina de Botucatu (FMB-UNESP).

ID Lattes: 3609974334123093

ORCID: 0000-0002-0024-0763

***Camila Lopes Cardoso***

Dentistry course, Centro Universitário do Sagrado Coração, (UNISAGRADO).

ID Lattes: 2409547375958396

ORCID: 0000-0001-9545-6809

All content in this magazine is licensed under a Creative Commons Attribution License. Attribution-Non-Commercial-Non-Derivatives 4.0 International (CC BY-NC-ND 4.0).



**Abstract:** Introduction: Monkeypox is an endemic viral zoonosis in several countries in central and western Africa. With an average incubation period of between 6 and 13 days, it is characterized by a period that can vary from 0 to 5 days of fever, headache, lymphadenopathy, asthenia and myalgia, followed by a rash about one to three days after onset. of the disease. fever. Rashes tend to be more localized to the face and limbs and may also appear on the mucous membranes of the oral cavity, genitals, conjunctiva and cornea. The illness is usually self-limiting and tends to resolve within two to four weeks. Objective: To analyze and elucidate important aspects of Monkeypox in the current world scenario, with emphasis on clinical characteristics, etiology, prevention, clinical picture, differential diagnosis, as well as its implications for dental care. Method: Fundamental concepts were used as a basis for formulating the necessary methods and procedures. The steps covered corresponded to: identification of the theme and elaboration of the research question; definition of inclusion and exclusion criteria; determine the information that must be obtained from the selected studies; the qualification of the study involved; evaluation and interpretation of results and exposure to review. The PICO strategy, a model derived from the PICO, was used. Thus, the first element (P = population) was the determination of patients with Monkeypox, the second (I = phenomenon of interest) the differential diagnosis and the third (Co = context) epidemiology and implications for dental care. The research question stated "What are the clinical characteristics of Monkeypox, differential diagnosis and implications for dental care? Searches were carried out in the main databases Scientific Electronic Library Online (SciELO), in the Virtual Health Library (BVS), Pubmed, Web of Science, Scopus and Google Scholar, initially 19 articles were selected, of

which 10 corresponded to the relevance of the research. Because it is a current epidemic, installed for several months, recent research is still rare in the world literature. Due to the increase in the number of cases, preventive measures must be implemented worldwide, as well as new studies on specific therapies and vaccines must be carried out in the coming months. Results: The obtained results indicate that the failures in the eradication campaign stimulated the creation of projects whose objective was to apply the same procedure to other infectious agents. Conclusion: Oral lesions appear in most cases. Thus, a careful anamnesis becomes indispensable at each dental appointment, as it is necessary to check whether the patient has any of the symptoms, whether there has been the appearance of skin lesions and other symptoms.

**Keywords:** Monkeypox, Etiology, Clinical characteristics, Epidemiology, Dental practices.

## INTRODUCTION

Monkeypox or monkeypox (MPX), a rare zoonosis of viral etiology and very similar to the smallpox virus, was first described in humans in the 1970s in the Democratic Republic of Congo. Sporadic outbreaks of this infection were initially limited only to the African continent, where it is considered endemic, being related to direct contact with wild reservoirs, mainly rodents <sup>1</sup>.

The monkeypox virus was first described in 1958, isolated from monkeys. It is a double-stranded enveloped DNA virus that belongs to the genus Orthopoxvirus, family Poxviridae, the same family as the virus that causes smallpox. There are two genetic clades of monkeypox virus, named after the region in which they were originally found: the Central African (Congo Basin) clade and the West African clade. The Congo Basin clade historically caused more severe disease and

was considered more transmissible.<sup>(2-3)</sup>.

Although smallpox no longer occurs naturally, in May 2022, some non-endemic countries of the disease reported the presence of MXP and, after investigating the cases, it was attributed to infected animals that were displaced from their origins. Currently, in non-endemic countries with detection of the disease, the mortality rate is 0.022%<sup>5</sup>.

The virus is usually acquired through contact with bodily fluids (such as saliva or blood) from an infected animal or through wounds caused by bites or scratches. There is a description of acquisition of the virus by eating raw or minimally cooked meat from wild animals in some areas of Africa<sup>(6-7)</sup>.

Person-to-person transmission can result from close contact with respiratory secretions or skin lesions from an infected person, such as skin-to-skin contact during sex, including kissing, touching, oral sex, and penetration with someone who has symptoms. Transmission also occurs indirectly through contact with recently contaminated items, such as clothing or bedding containing infectious material from skin lesions or body fluids. The persistence of a virus particle on surfaces of various types varies from one to 56 days, depending on the temperature and humidity conditions of the environment<sup>(8-9)</sup>.

It is a self-limited illness, which lasts from 2 to 4 weeks and is classically characterized by a predominance of fever, accompanied by skin eruptions. Chart 1 shows the evolutionary forms of the cutaneous manifestations of MXP.

Internship	Duration	Characteristics
Enantema		Initially observed on the tongue and mouth.
Stains	1 to 2 days	After the enanthema, a macular rash appears, initially on the face, which, within 24 hours, spreads to the upper and lower limbs and then to the hands and feet, including the palmar and plantar surface (centrifugal distribution).
Papules	1 to 2 days	From the 3rd day of the exanthema, the lesions progress from macules to papules.
vesicles	1 to 2 days	Between the 4th and 5th day, the lesions become vesicular.
Pustules	5 to 7 days	Around the 6th to 7th day, the lesions become pustular, markedly raised, generally round and firm to the touch. There may be central umbilication. They keep for 5 to 7 days before they begin to scab.
Crusts	7 to 14 days	By the end of the second week, pustules develop into scabs and there may be scarification after 1 week.

Table 1– Evolutionary stages of the Monkeypox rash

Because it is a disease whose clinical manifestation is the appearance of vesicles, some differential diagnoses must be elucidated, such as Chickenpox, Herpes Zoster, Herpes simplex, bacterial skin infection, disseminated gonococcal infection, primary or secondary syphilis, chancroid, lymphogranuloma venereum, granuloma inguinis, molluscum contagiosum, allergic reaction and any other causes of papular or vesicular rash. Although not all in some cases, lymphadenopathy during the prodromal stage of monkeypox may aid in the differential diagnosis. A differential diagnosis of malaria must be made in patients with febrile illness. or other infectious diseases according to local context and epidemiology<sup>(10-11)</sup>.

In children and adolescents, monkeypox skin lesions can be confused with other

disease outbreaks commonly identified in this age group, including chickenpox, hand-foot-and-mouth disease, measles, scabies, molluscum contagiosum, herpes, syphilis (including congenital syphilis), allergy and drug rashes<sup>(12-13)</sup>.

The disease becomes more challenging when it initially manifests itself in the oral cavity. Due to the richness of manifestations, the dental surgeon must pay attention to the early recognition and investigation of the differential diagnoses already listed above. In the oral cavity, the lesion is classically a painful, deep rash, usually on the face and oral cavity, before spreading throughout the body. These oral lesions are clinically punctate, deep, well-circumscribed, and may have an ulcerated surface or the presence of a crust<sup>13</sup>.

Dental practices can reduce Monkeypox infection through awareness, screening, and infection control. Therefore, all dental care is very important, as well as educating the population about the forms of contagion<sup>14</sup>.

## METHODOLOGICAL PROCEDURES

This chapter aims to present the steps and procedures that guide this work. In addition, the contents of the choices, analyzes and interpretations that will be necessary to reach the real objective proposed by the research were described. Fundamental concepts were used as a basis for formulating the necessary methods and procedures.

## QUANTIFICATION OF RESEARCH

In order to gather scientific publications relevant to the theme proposed in the present work, a quantification of these publications was developed, searching from scientific portals consecrated at an international level. Furthermore, the search took place in the abstract of the scientific publication, however when it was not possible to carry out it through

the abstract, the title of the publication was searched. In view of this, Table 1 shows the portals and their search field.

Element on which the search was performed	Name of searched portals
Summary	SCOPUS
Title	Web of Science
Summary	Pub Med
Summary	SciELO
Summary	Google Scholar
Summary	BVS

Table 2 – Search field scientific publication portals where they were researched

In order to characterize the subject under study, four combinations of keywords were chosen to compose the research, namely:

- 1) “Monkeypox” AND Oral Lesions;
- 2) “Monkeypox I” AND Dentistry;
- 3) “Monkeypox” AND Epidemiology
- 4) “Monkeypox” AND diagnosis

In addition to the criteria presented above, another method of requirements was used, the election only of scientific articles that are published in journals that have the peer review process or *peer review*<sup>14</sup>. The adoption of this criterion is justified because, for many scientists and editors, scientific journals that have a peer review process are the best available approach to guarantee scientific quality<sup>15</sup>. Subsequently, one must identify which identical scientific articles appear more than once, that is, which of them are repeated. This allows you to read the article only once, quantifying the repetitions. Next, we quantify which articles do not have full access, that is, which are not available for reading.

Finally, it is possible to quantify studies that guide the theme, which helps to verify trends in the literature, in addition to helping to guide the methodological procedures adopted.

## CARACTERIZAÇÃO DA PESQUISA CHARACTERIZATION OF RESEARCH

It is a bibliographic review of the integrative review type, which defines current concepts for specific topics, describes knowledge in its current state, allows separating scientific knowledge from concepts and also subsidizes the research response to professional practice<sup>16</sup>.

The steps covered corresponded to: identification of the theme and elaboration of the research question; definition of inclusion and exclusion criteria; determine the information that must be obtained from the selected studies; the qualification of the study involved; evaluation and interpretation of results and exposure to review<sup>17</sup>.

The PICO strategy was used, a model derived from PICO<sup>(9-10)</sup>. Thus, the first element (P = population) was determined by patients with MokeyPox, the second (I = phenomenon of interest) the differential diagnosis and the third (Co = context) impact on dental care. The research question stated “What are the clinical characteristics of Monkeypox, differential diagnosis and implications for dental care?”

The health sciences descriptors (DeCS) and medical subject headings (MeSH) used to search for studies were: Diagnosis, Monkeypox, dental services. The searches were carried out from January to April 2023 in the Scientific Electronic Library Online (SciELO), in the Virtual Health Library (VHL), Pubmed, Web of Science, Scopus and Google Scholar.

Initially, the title and abstract of all screened articles were read; then, a detailed reading of the selected articles was carried out and those chosen to compose the final sample.

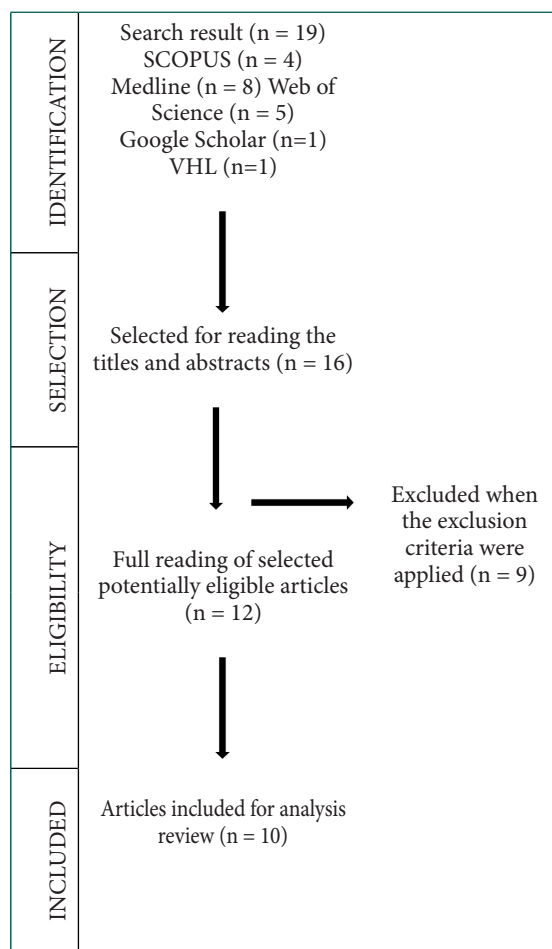


Table 3 - Flowchart of the selection process of articles to compose the sample

Articles that addressed the main question proposed for the research were selected as inclusion criteria. Duplicate articles, those that did not fit the established thematic framework, as well as undergraduate dissertations or theses were excluded. 19 studies were obtained from the combination of descriptors. After a more careful evaluation of the abstracts, 10 articles were finally selected, which structured the integrative review, applying the established inclusion criteria.

The data collection of the articles was carried out through files containing: article identification (author and year of publication), the journal in which it was published and the main contributions of the studies. In addition, the analysis of the information was descriptive.

## RESULTS AND DISCUSSION

Based on searches in the databases, 19 articles were found and, applying the inclusion and exclusion criteria and reading the titles, abstracts, objectives, methods, results and conclusions, 10 articles could be obtained. Chart 4 presents a summary of the articles used in this integrative review.

Year	Author	Title	Main results
2022	Lakshman et al	The Monkeypox Outbreak and Implications for Dental Practice.	Present the initial signs of MPX during the prodromal period, in the oral cavity as single or multiple macular lesions in the oral mucosa.
2022	Pisano et al	Atypical oral presentation of monkeypox virus: A report of two cases from Florence, Italy.	Clinical presentation of MPXV infection is similar to that of smallpox, but generally less severe, with lower rates of complications and fatality.
2022	Massimo, et al	Human Monkeypox: Oral Implications and Recommendations for Oral Screening and Infection Control in Dental Practice.”	Oral implications and recommendations for oral screening and infection control in dental practice
2022	Benslama, et al	Monkeypox oral lesions.”	Clinical case on manifestation of Monkeypox in the oral cavity.
2022	Bigaran et al	A literature review on the clinical and epidemiological aspects of Monkeypox	Review the epidemiology of smallpox, its history in Brazil and in the world, in addition to the clinical picture of the disease and the importance of vaccination
2022	Kreutz et al	Monkey pox (monkeypox virus - poxviridae): a brief review	Elucidate the important aspects of the Monkeypox virus and its different hosts, in addition to its historical and epidemiological aspects

2022	Rocha et al.	The 2022 human Monkeypox outbreak and dentistry: The relevance of oral mucosal and facial skin lesions.	Present the initial signs during the, in the oral cavity as single or multiple macular lesions in the oral mucosa as well as therapeutic options.
2022	Qiang Guo1 Yan Zhou1, Haiyang Wu	Concern over monkeypox outbreak: What can we learn from the top 100 highly cited articles in monkeypox research?	This work collects data on the 100 most cited articles when discussing monkeypox and provides epidemiological data collected in 19 countries.
2022	Petersen et al.	Human Monkeypox Epidemiologic and Clinical Characteristics, Diagnosis, and Prevention	This work elucidates data on the epidemiology, discovery, transmission, diagnosis, prevention and treatment of monkeypox. As well as, it presents clinical data on the disease in question, consisting of images and data of general relevance.
2022	Kumar et al.	The 2022 outbreak and the pathobiology of the monkeypox virus	This work elucidates data on transmission, diagnosis, prevention, mutations, pathogenesis and signs and symptoms of monkeypox. As well as, it portrays the epidemiological scenario in the USA.

Table 4– Search field portals of scientific publications where they were researched

The epidemiological pattern of monkeypox infection has undergone considerable changes since the 1970s. In addition to the decentralization of the disease, which started to be detected not only in African countries, there was also a change in the average age group with the highest incidence of 4 years in 1970s for a 10-year average from 2000 to 2009 and 21 years from 2010 to 2019. These

data correlate with a vaccination program to eradicate smallpox that started in 1967 and ended in the 1980s, after the disease was eradicated. It has been observed that 80 to 96% of cases of monkeypox occur in unvaccinated individuals. In addition, there was an increase in the secondary form of the disease, when an infected individual has a history of contact with other infected people.

Due to the numerous possibilities of differential diagnosis, the confirmation of the disease in Brazil still faces many obstacles. The main differential diagnosis is severe chickenpox, which presents skin lesions on the palms of the hands and soles of the feet, but with greater superficiality. In addition to severe chicken pox, other diagnoses that can confuse doctors and dentists include molluscum contagiosum, measles, bacterial skin infections, scabies, syphilis, and drug reactions. While the ongoing MPX outbreak is of great public health importance, the number of cases is small compared to the millions of dental patients treated annually<sup>27</sup>. Consequently, in geographic regions with low prevalence of MPX, the probability of oral health professionals encountering a case of MPX remains proportionately low, in contrast to countries with high rates of transmission in the general population, where the risk of viral transmission and cross-infection in the dental area configuration can be increased<sup>26</sup>.

Furthermore, MPX-positive individuals are considered potentially infectious during the prodromal or acute phase, hypothetically reducing the likelihood of viral transmission to oral health professionals. However, the exact spillage of MPX and the related risk of transmission in dental settings remains unknown<sup>(28-29)</sup>.

However, a large percentage of the population visits dental offices, so some monkeypox patients may seek dental care during periods of increased risk of infection in

the general population. In addition, reinfected individuals can also spread the infection, even if they are asymptomatic carriers. Therefore, oral health professionals need to be aware not only of the clinical presentation of the disease, but also of the associated preventive measures for infection control in dental settings.

Assuming that the risk of transmission of monkeypox in dental offices is low, dentists and staff must take steps to minimize the spread of the virus, being aware that the disease can be spread by respiratory droplets over close range and through face-to-face physical contact. They also collaborate by keeping themselves informed about cases in their community, attentive to announcements from the local Health Departments and carrying out adequate screening of patients and employees<sup>18</sup>

## FINAL CONSIDERATIONS

The results obtained indicate that the failures in the eradication campaign stimulated the creation of projects whose objective was to apply the same procedure to other infectious agents. Anyway, the results are relevant and highlight the need to take into account the main aspects of the infection and the way it is currently perceived for a better understanding and eradication, especially in potentially reproductive sites of the disease.

The prevention of MonkeyPox is similar to the prevention of other viral infections caused by viruses of the orthopoxvirus genus and consists of preventive measures for contact with infected individuals or animals, since any direct or indirect contact can lead to infection. In addition, the introduction of vaccines against the virus depends on the development of new research on the subject, but it is believed that such a measure would be effective in reducing the progression of transmission of the infection.

Oral lesions appear in most cases. Thus, a

careful anamnesis becomes indispensable at each dental appointment, as it is necessary to check whether the patient has any of the symptoms, whether there has been the appearance of skin lesions and other symptoms. If the patient has vesico-bullous orofacial lesions, the most prudent thing is for the dentist to include the hypothesis of smallpox in the differential diagnosis and the professional can help reduce the spread of the virus.

Future studies must draw attention to the possible existence of a pre/asymptomatic phase of MPX, which, like asymptomatic carriers, could extend the transmission of the virus to the dental environment, clarify the transmission and excretion routes of the virus and increase knowledge of risk factors. MPX complications. and co-infection rates. These

findings may be important for identifying high-risk individuals and for early diagnosis and containment.

More research is needed to understand the potential role of the MPX saliva test and general preventive measures in reducing the risk of emerging and re-emerging viral infectious diseases in dental practice.

Reported findings and related recommendations may be updated as new evidence becomes available and as the epidemic evolves.

It is worth mentioning the importance of vaccination for proper management in society. Therefore, it is important to recognize the enormous morbidity and mortality potential of smallpox and train professionals to recognize this pathology and institute appropriate treatment.

## REFERENCES

1. World Health Organization (WHO). Monkeypox: key facts. 2022. Available from: <https://www.who.int/news-room/fact-sheets/detail/monkeypo> » <https://www.who.int/news-room/fact-sheets/detail/monkeypox>
2. THORNHILL, J. P. et al. Monkeypox virus infection in humans across 16 countries – April-June 2022. *The New England Journal of Medicine*, v. 387, p. 679-691, 2022. Acesso em: 04 abr. 2023.
3. World Health Organization (WHO). Monkeypox: public health advice for gay, bisexual and other men who have sex with men. 2022. Available from: <https://www.who.int/news/item/25-05-2022-monkeypox--public-health-advice-for-gay--bisexual-and-other-men-who-have-sex-with-men>» <https://www.who.int/news/item/25-05-2022-monkeypox--public-health-advice-for-gay--bisexual-and-other-men-who-have-sex-with-men>. Acesso em: 03 mar. 2023.
4. CENTERS FOR DISEASE CONTROL AND PREVENTION (CDC). Poxvirus. Monkeypox. How it spreads. Georgia, 18 out. 2022 Disponível em: <https://www.cdc.gov/poxvirus/monkeypox/transmission.html>. Acesso em: 03 mar. 2023.
5. European Centre for Disease Prevention and Control (ECDC). Hepatitis A outbreaks in the EU/EEA mostly affecting men who have sex with men[Internet]. 2017[cited 2022 Jun 20]. Available from: <https://www.ecdc.europa.eu/sites/default/files/media/en/publications/Publications/16-02-2017-RRA%20UPDATE%201-Hepatitis%20A-United%20Kingdom.pdf>
6. RIZK, J. G. et al. Prevention and Treatment of Monkeypox. *Drugs*, v. 82, p. 957-963, 2022.
7. Giulio DB, Eckburg PB. Human monkeypox: an emerging zoonosis. *The Lancet Infectious Diseases*, 2004;4(1):15-25. DOI: [https://doi.org/10.1016/S1473-3099\(03\)00856-9.2](https://doi.org/10.1016/S1473-3099(03)00856-9.2).
8. Petersen E, Kantele A, Koopmans M, Asogun D et al. Human Monkeypox Epidemiologic and Clinical Characteristics, Diagnosis, and Prevention. *Infectious Disease Clinics of North America*, 2019;33(4):1027–1043. DOI : <https://doi.org/10.1016/j.idc.2019.03.001>.



9. Sousa, L. M. M. S., Marques, J. M., Firmino, C. F., Frade, F., Valentim, O. S., & Antunes, A. V. (2018). Modelos de formulação da questão de investigação na prática baseada na evidência.
10. Yinka-Ogunleye, A., Aruna, O., Dalhat, M., Ogoina, D., McCollum, A., Disu, Y., & Satheshkumar, P. S. (2019). Outbreak of human monkeypox in Nigeria in 2017–18: a clinical and epidemiological report. *The Lancet Infectious Diseases*, 19(8), 872-879.
11. Mendes, K. D. S., Silveira, R. C. D. C. P., & Galvão, C. M. (2008). Revisão integrativa: método de pesquisa para a incorporação de evidências na saúde e na enfermagem. *Texto & contexto-enfermagem*, 17, 758-764.
12. Bigaran, L. T., Barbosa, T. C., Barrachi, B. M., de Souza Fuza, P. F. N., Alssuffi, J. E. A., Alssuffi, M. E. A., & de Paula, E. C. (2022). Uma revisão de literatura sobre os aspectos clínicos e epidemiológicos da Monkeypox. *Research, Society and Development*, 11(9), e23411931612-e23411931612.
13. Brasil, P., Martins, E. B., Calvet, G. A., & Werneck, G. L. (2022). O que precisamos saber sobre a infecção humana pelo vírus monkeypox?. *Cadernos de Saúde Pública*, 38.
14. Conselho Regional de Odontologia do Distrito Federal, CRO/DF. Mas afinal o que é a varíola dos macacos? Disponível em <https://cro-df.org.br/mas-afinal-o-que-e-a-variola-dos-macacos/> Acesso em: 04 abril. 2023.
15. Cheng, K., Guo, Q., Zhou, Y., & Wu, H. (2022). Concern over monkeypox outbreak: What can we learn from the top 100 highly cited articles in monkeypox research?. *Travel Medicine and Infectious Disease*, 49, 102371.
16. De Paula, R. A. C., Campos, K. R., Sacchi, C. T., Amarante, A. F., Taniwaki, N. N., Nishina, G. M. N., & Abbud, A. (2022). Informe epidemiológico: primeiros casos confirmados de monkeypox. *BEPA. Boletim Epidemiológico Paulista*, 19, 1-18.
17. Dos Santos Batista, L., & Kumada, K. M. O. (2021). Análise metodológica sobre as diferentes configurações da pesquisa bibliográfica. *Revista brasileira de iniciação científica*, 8, e021029-e02102
18. Mendes, K. D. S., Silveira, R. C. D. C. P., & Galvão, C. M. (2008). Revisão integrativa: método de pesquisa para a incorporação de evidências na saúde e na enfermagem. *Texto & contexto-enfermagem*, 17, 758-764.
19. Petersen, E., Kantele, A., Koopmans, M., Asogun, D., Yinka-Ogunleye, A., Ihekweazu, C., & Zumla, A. (2019). Human monkeypox: epidemiologic and clinical characteristics, diagnosis, and prevention. *Infectious Disease Clinics*, 33(4), 1027-1043.
20. Silva, R. F., Santoro, D. C., Sanches, F., Nogueira, M. M. P., Freitas, L. A. D., Bittencurt, D. A. P., & Ribeiro, A. D. S. (2022). O que precisamos saber sobre Monkeypox em humanos: fatos, não fakes.
21. Simpson, K., Heymann, D., Brown, C. S., Edmunds, W. J., Elsgaard, J., Fine, P., & Wapling, A. (2020). Human monkeypox—After 40 years, an unintended consequence of smallpox eradication. *Vaccine*, 38(33), 5077-5081.
22. Sousa, Á. F. L. D., Sousa, A. R. D., & Fronteira, I. (2022). Varíola de macacos: entre a saúde pública de precisão e o risco de estigma. *Revista Brasileira de Enfermagem*, 75.
23. Sousa, L. M. M. S., Marques, J. M., Firmino, C. F., Frade, F., Valentim, O. S., & Antunes, A. V. (2018). Modelos de formulação da questão de investigação na prática baseada na evidência.
24. World Health Organization. (2022). Vaccines and immunization for monkeypox: interim guidance, 24 August 2022 (No. WHO/MPX/Immunization/2022.2). World Health Organization.
25. Yinka-Ogunleye, A., Aruna, O., Dalhat, M., Ogoina, D., McCollum, A., Disu, Y., & Satheshkumar, P. S. (2019). Outbreak of human monkeypox in Nigeria in 2017–18: a clinical and epidemiological report. *The Lancet Infectious Diseases*, 19(8), 872-879.
26. Samaranyake, Lakshman, and Sukumaran Anil. “The monkeypox outbreak and implications for dental practice.” *international dental journal* (2022).

27. Pisano, Luigi, et al. "Atypical oral presentation of monkeypox virus: A report of two cases from Florence, Italy." *Travel Medicine and Infectious Disease* (2022): 102457-10245
28. Amato, Massimo, et al. "Human Monkeypox: Oral Implications and Recommendations for Oral Screening and Infection Control in Dental Practice." *Journal of Personalized Medicine* 12.12 (2022): 2000.
29. Benslama, Lotfi, Jean-Philippe Foy, and Chloé Bertolus. "Monkeypox oral lesions." *Journal of Stomatology, Oral and Maxillofacial Surgery* (2022).
30. Gonçalves, M. R., Hennigen, A. W., Martins, A. C. M., Cornely, A. F. H., Kinalski, D. D. F., Rados, D. R. V.,... & Kupstaitis, L. C. Coordenação Geral: Roberto Nunes Umpierre Natan Katz Coordenação Científica.
31. Monte, Gabriella Silva, et al. "Diagnóstico tardio dos casos de varíola dos macacos nos serviços de saúde do Brasil: reflexos e impactos." *Research, Society and Development* 12.2 (2023): e20712239718-e20712239718.
32. Pereira, Victória Santos Marques, et al. "Varíola dos macacos: uma visão geral da doença reemergente no contexto atual: Human Monkeypox: an overview of the emerging disease in 2022." *Brazilian Journal of Development* 8.10 (2022): 68071-68081.
33. Sousa, Á. F. L. D., Sousa, A. R. D., & Fronteira, I. (2022). Varíola de macacos: entre a saúde pública de precisão e o risco de estigma. *Revista Brasileira de Enfermagem*, 75.
34. Pascom, A. R. P., Souza, I. N. D., Krummenauer, A., Duarte, M. M. S., Sallas, J., Rohlf, D. B.,... & Miranda, A. E. (2022). Características epidemiológicas e clínicas dos casos de monkeypox no Brasil em 2022: estudo transversal. *Epidemiologia e Serviços de Saúde*, 31, e2022851.