

**THE DIFFERENTIAL
DIAGNOSIS FOR
COVID-19 IN UPPER
RESPIRATORY TRACT
INFECTION**

Paula Santos

Beevi, Ribeirão Preto - São Paulo

All content in this magazine is licensed under a Creative Commons Attribution License. Attribution-Non-Commercial-Non-Derivatives 4.0 International (CC BY-NC-ND 4.0).



Abstract: A 43-year-old man initially with gastritis, persistent cough, and hyperemic pharynx, without symptoms of fever, shortness of breath, or body aches. Four days after the clinical examination, the patient complained of tiredness, deltoid pain, and an unusual headache without fever or cough. The patient describes pain in the region of the maxillary sinuses with greater sensitivity on the right, but the clinical evaluation ruled out sinusitis. Thus, the serological test was performed, which indicated negative IGG, and then the face X-ray and X-ray were performed and examined with artificial intelligence software.

INTRODUCTION

China's health authorities detected the first cases of COVID-19 in November 2019. In March, the World Health Organization declared COVID-19 infection to be a global pandemic.

In Brazil, the Ministry of Health divided the pandemic into two phases for better management: phases of containment and mitigation. The first phase cases were attributed to international travel or contact with sick people who traveled abroad. In the mitigation phase, the Ministry of Health recognized the occurrence of community-based transmission, from person to person, in the country - a late recognition, since deaths unrelated to transmission chains involving travelers had already occurred¹.

In all states of Brazil, there was an exponential growth in the number of infected individuals from January 2021, after confirming the new variations of Covid-19 in Manaus. The number of cases has exceeded 1.500 daily deaths. Concomitantly there has also been an exponential increase in the health system in the private and public sector in several municipalities in Brazil.

In this context, one of the first steps towards adopting measures of social isolation

and hospitalizations is to know who was infected by COVID-19. Currently, the PCR-RT test is the gold standard for the diagnosis of COVID-19, but its results may take 24 to 48 hours to be performed. In pandemic conditions, this period can take 5 to 10 days due to many requests. Thus, the protocols were established, which combine clinical assessment and radiological exams to carry out a more detailed assessment of COVID-19².

CASE REPORT

A patient diagnosed with COVID-19 contracted on a community basis, presenting different signs and symptoms within 30 days. The first suspected diagnosis was made with the clinical evaluation and the aid of an artificial intelligence platform³ and confirmed by the PCR-RT exam.

Patient B.F.S., 43 years old, a half years ago, a picture of gastritis and sporadically presented with a cough. However, in October, 30 days before the final confirmation by the PCR-RT exam, the cough condition worsened, but there were no symptoms such as fever, shortness of breath, or body pain. Still observing his symptoms, the patient reports that two days after the frequent presence of cough, he had a sore throat, and when performed the clinical examination he had a very hyperemic pharynx and treatment with nimesulide 100mg 8 was started in 8 hours and with the treatment of patient no longer complained of pain. After one week, the clinical examination was performed, and despite not showing any symptoms, the pharynx showed signs of hyperemia but without cough. Four days after the clinical examination, the patient had tiredness and pain in both deltoids and had no fever or cough. The day after rest, pain in the deltoids and tiredness was no longer present, but two days after rest, the patient described an unusual headache, which he had previously

presented, described as a tension headache, so treatment was started. With paracetamol 500mg 6 in 6 hours and even with medication, the condition persisted the next day. Besides, the patient had pain in the maxillary sinuses region with greater sensitivity on the right. In this way, the serological test was performed, which indicated a negative IGG, and then the face and chest radiography was performed. Subsequently, these images were submitted to an evaluation in the software recently acquired by the municipality. The Marie platform³ is software for diagnosing patients with COVID-19, tuberculosis, Malaria, and H1N1. The face images were inserted into the software and, as a result, indicating the virus's presence on the face radiography (Figure 1) and in the trachea and cardiovascular region on the chest radiography (Figure 2).

In the evaluation of the face P.A. image, frontal sinuses were observed, the edges of the sinuses are well delineated, without blurring and with darkening (dark gray tone), showing that there are no changes in the frontal sinuses—the radiolucent ethmoid sinuses highlighting the region without changes in the edges and without blurring. The region of the maxillary sinuses has blurred edges and altered radio transparency. During the evaluation of signs and symptoms and radiological examination, maxillary sinusitis was ruled out, as it did not present dental pain, pain around the eyes, a feeling of pressure when the head is lowered, and clogged ears⁴. In the face radiography examination, we excluded the presence of sinusitis in the sinuses (Figure 1 (A)). In figure 1 (B), we evaluated the software, which indicated the suggestion of diagnosis for COVID-19 corroborating the PCR-RT exam. The algorithm highlighted the right maxillary sinus region with more significant characteristics for COVID-19.

For the imaging exam, the algorithm detected changes in the trachea region and

cardiovascular changes, which corroborates the sporadic symptoms of tiredness during professional activity generating discomfort since the professional did not perform an activity that requires great efforts, such as running, weight lifting, or other related activities.

The oropharyngeal swab test rapid was performed, with a negative result. The gold standard exam for the detection of COVID-19 consists of collecting a PCR sample, in which the positive result of the sample was obtained.

DISCUSSION

Bearing in mind that the number of tests performed is still lower than expected and that use of images such as Chest X-Rays is frequently used to guide the diagnosis, intelligent computational models can help isolate the patient and avoid community spread. A clear example is what occurred in this case, and the patient is a doctor of a Basic Health Unit, one general practitioner. Currently, the average daily attendance in Itapeva-MG is between 20-40 patients. Given that it was removed before the result of PCR-RT, we have that in 11 days which remained on suspicion of COVID-19, we have on average than during the 11 days until the result of PCR-RT, the removal prevented community spread between 220-440 patients.

In this context, we can observe that the professional's removal provided the removal at an appropriate time so that he could recover and prevent community contamination. Still, we can emphasize that the descriptions of signs and symptoms collaborate for clinical investigation, in addition to the typical symptoms. The subtle change in the frequency of cough one month before the conclusion of the diagnosis shows evidence in this case that the infection by COVID-19 may even occur initially before 20 days and suggests that in the case of a pre-existing disease, small

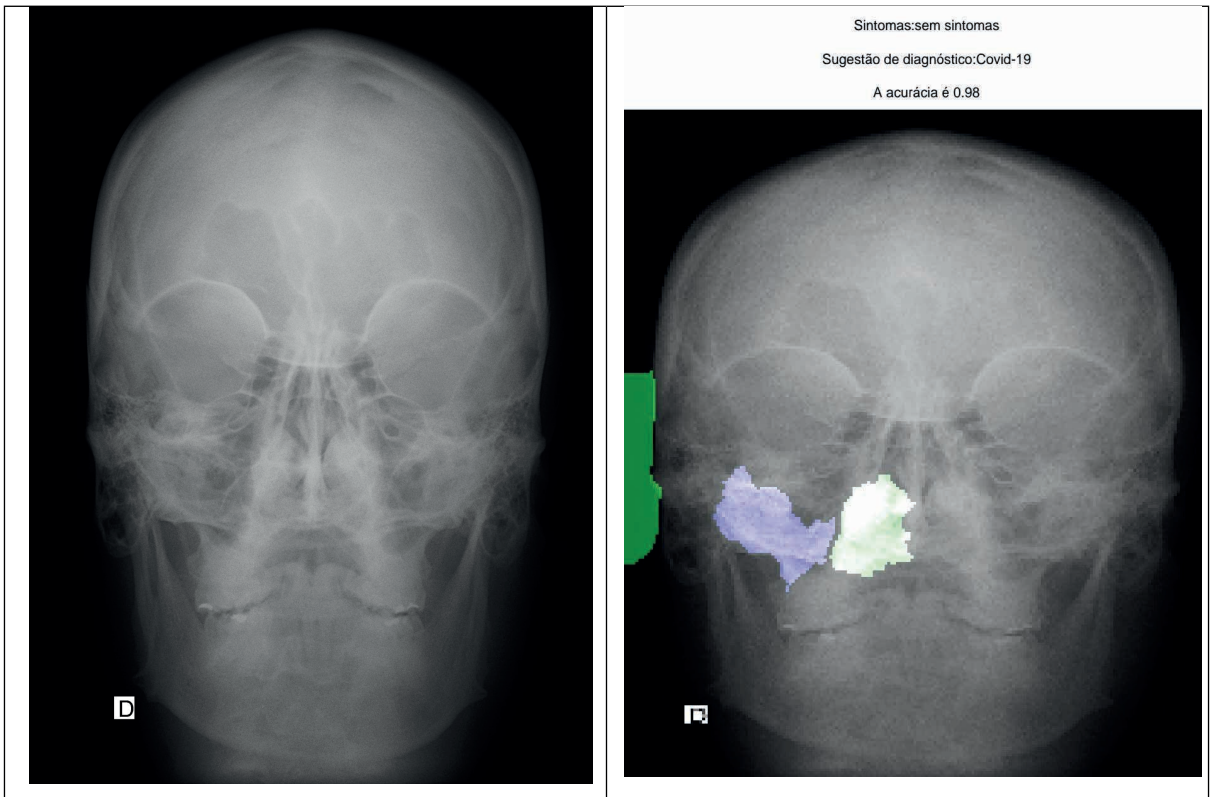


Figure 1. (A) Chest X-Ray image of skull PA: front; (B) Identification of Covid-19 changes in maxillary sinuses.

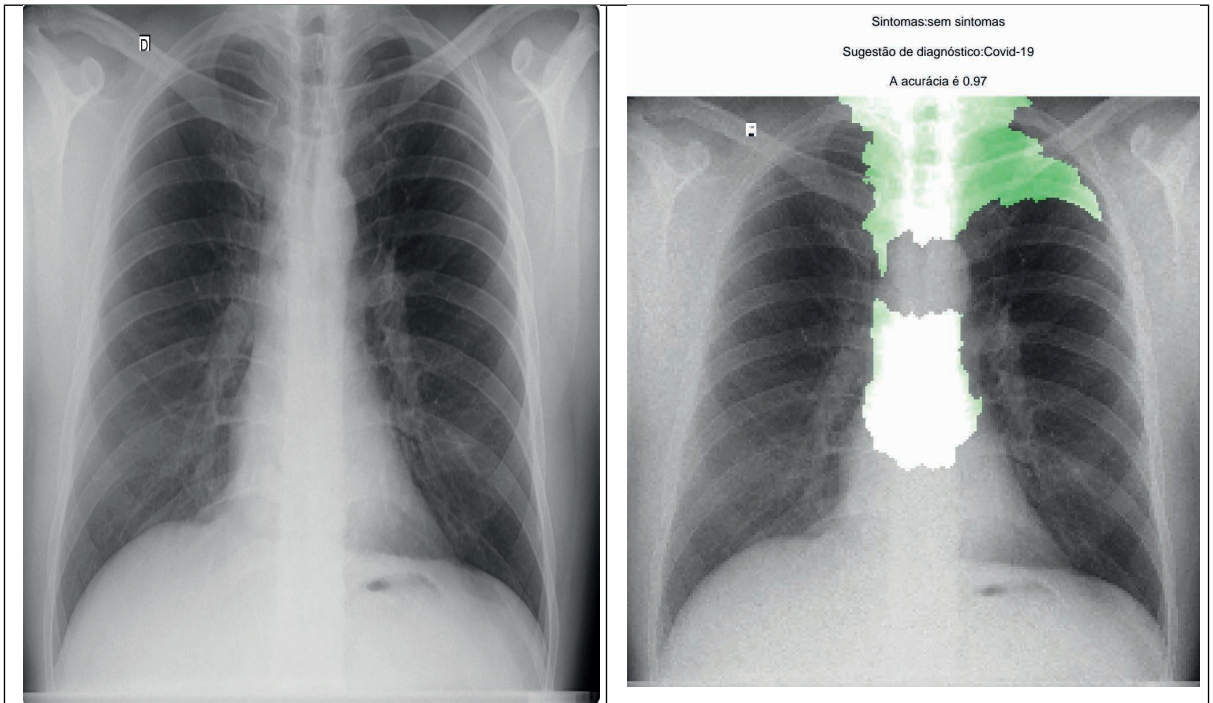


Figure 1. (A) Image of the Chest X-Ray; (B) Identification of Covid-19 changes in the upper respiratory system.

signs daily results presented may indicate the onset of COVID-19 infection. The other signs became more evident 20 days before the final diagnosis and even appearing infrequently, such as tiredness. This aspect indicated cardiorespiratory changes, reported, however, not measured. However, the virus's presence in the maxillary sinuses may suggest an initial infectious focus of COVID-19, and pointing to a differential diagnosis between sinusitis and the new coronavirus may present a preference in maxillary sinuses⁵.

CONCLUSION

The possibility of evaluating the maxillary sinus region's morphophysiology suggests a real possibility in the clinical assessment of the new coronavirus's pandemic, thus requiring the monitoring and follow-up of the clinical evolution for pharyngeal hyperemia. Clinical signs should always guide such possibilities

and indicate warning signs for the differential diagnosis of COVID-19.

Complementary examinations of face and chest radiography are useful for investigation and, when associated with predictive models of artificial intelligence, can assist the professional in decision making and thus facilitate management and conduct. Still, we can point out that in small municipalities, health professionals do not have C.T. scanners, and in many cases, it is necessary to rent the device or move patients to more extensive and more distant cities. In general, and due to the patients' severity (the majority under mechanical ventilation), these cases are transferred to larger municipalities with more technological resources and infrastructure for care. We corroborate the need for anamnesis and a thorough clinical evaluation of the patient's profile to minimize and understand the clinical evolution of COVID-19.

REFERENCES

1. SANTOS, Paula. Intelligent computational model for the classification of Covid-19 with chest radiography compared to other respiratory diseases. arXiv preprint arXiv:2108.05536, 2021.
2. Meirelles, G. S. P.. COVID-19: uma breve atualização para radiologistas. *Radiol Bras* vol.53 no.5 São Paulo Sept./Oct. 2020 Epub Oct 02, 2020.
3. BENTO, Valdirene; SALAROLI, Bruno Frederico; SANTOS, Paula. MARIE: VALIDATION OF THE ARTIFICIAL INTELLIGENCE MODEL FOR COVID-19 DETECTION.
4. ANSELMO-LIMA, Wilma T. et al . Rinossinusites: evidências e experiências. Um resumo. **Braz. j. otorhinolaryngol.**, São Paulo , v. 81, n. 1, p. 8-18, Feb. 2015.
5. Naeini, A. S.; Karimi-Galougahi, M.; Raad, N.; Ghorbani, J.; Taraghi, A.; Haseli, S.; Mehrparvar, G.; Bakhshayeshkaram, M.. Paranasal sinuses computed tomography findings in anosmia of COVID-19. *Am J Otolaryngol* ; 41(6): 102636, 2020.