

RIGHT SPIEGEL HERNIA ASSOCIATED WITH IPSILATERAL INGUINAL HERNIA: A CASE REPORT

Daiany Bromonschenkel de Angeli

Ester Rossi Tavares

Heloísa Louback Pina

Lucila Maria de Almeida Lopes

Luisa Dardengo Ramalho

Rodrigo Scoassante Tavares

All content in this magazine is licensed under a Creative Commons Attribution License. Attribution-Non-Commercial-Non-Derivatives 4.0 International (CC BY-NC-ND 4.0).



Abstract: Spiegel's hernia is a rare defect of the abdominal wall. The absence of characteristic symptoms makes its diagnosis difficult. Surgical treatment is indispensable, either by conventional technique or by videolaparoscopy, due to the high rate of strangulation. We present the unusual case of a 72-year-old woman with Spiegel's hernia on the right, concomitant with ipsilateral direct inguinal hernia. The patient underwent conventional elective surgery with primary correction of the defect using a propylene mesh and Spiegel hernia repair, in addition to right inguinal herniorrhaphy using the Lichtenstein technique.

Keywords: Abdominal hernia; Aponeurosis; Surgical Screens; herniorrhaphy; General surgery.

INTRODUCTION

Spiegel's hernias have a rare incidence, representing 0.12 to 2% of abdominal wall hernias. They are characterized by a protrusion of a peritoneal sac, an organ, or preperitoneal fat from its normal position through a congenital or acquired hole in the aponeurosis of Spiegel, which is bordered by the rectus abdominis muscle medially and the linea semilunaris laterally.¹

They mainly affect women over the fifth decade of life, and may be associated with comorbidities such as COPD, cirrhosis, obesity and pregnancy. They usually do not have characteristic symptoms, which can make early diagnosis difficult. Picture methods such as ultrasonography (US) and computed tomography (CT) can be used to aid in the diagnostic determination. Treatment can be performed by open surgical approach or laparoscopically.²

The inguinal hernia is one of the most frequent pathologies faced by the General Surgeon. The diagnosis of inguinal hernia can be based on clinical history and physical

examination in most situations with a sensitivity of 74.5 – 92% and specificity of 93%. The main sign mentioned by the patient is swelling in the region, which may be associated with pain or discomfort. It can be classified as direct or indirect depending on its location in relation to the epigastric vessels.

GOAL

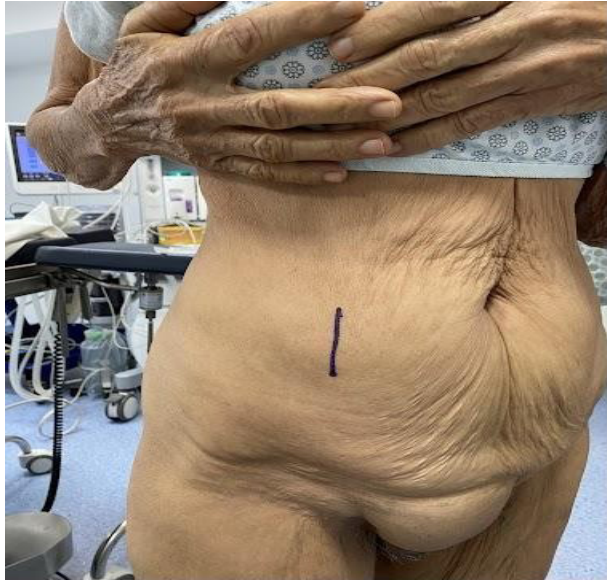To report the occurrence of a rare clinical case of Spiegel's hernia on the right associated with an ipsilateral direct inguinal hernia and its surgical treatment.

CASE REPORT

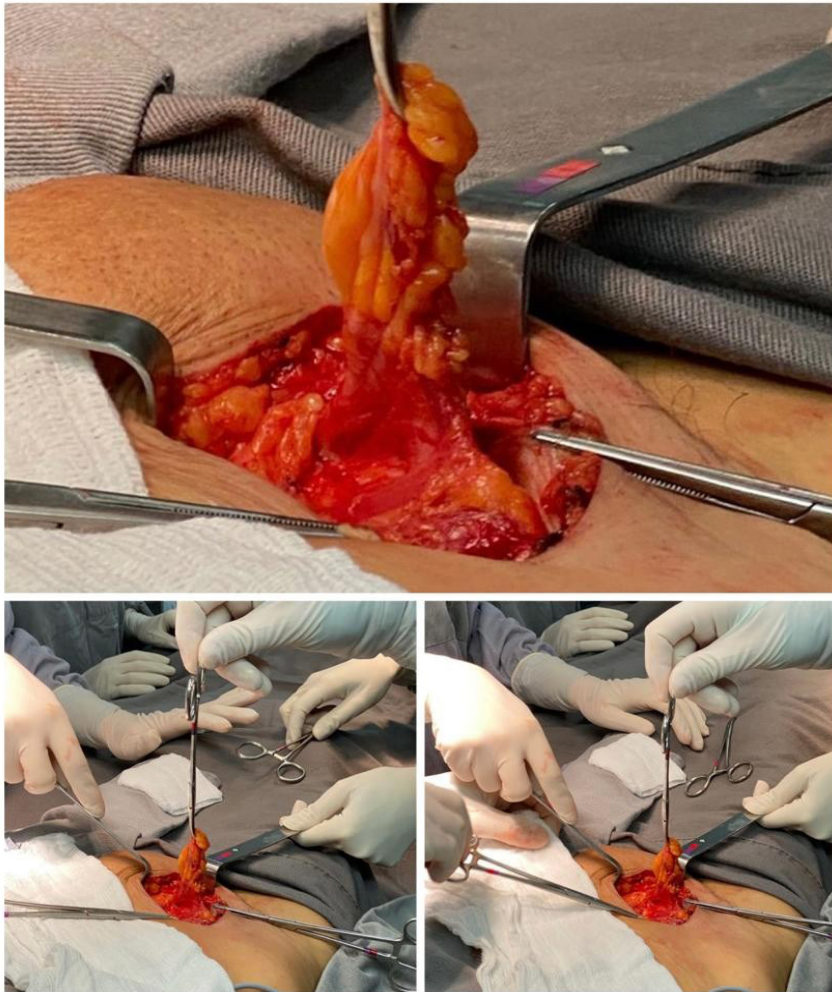
A 72-year-old female patient presented with a history of bulging of the abdominal wall on the right flank and in the right inguinal region, which appeared about 2 years ago. She referred pain in prominent places, mainly with physical exertion, but also, occasionally, at rest. She denied other symptoms.

On physical examination, there was a hernia in the inguinal region on the right, of small volume, reducible and without signs of entrapment, and a herniation in the region lateral to the rectus abdominis on the right flank (Spiegel hernia), also reducible and without signs of entrapment or strangulation.

During the surgical procedure, the patient underwent spinal anesthesia, antisepsis with degermant and alcoholic chlorhexidine, placement of sterile drapes and, for correction of the direct inguinal hernia, right inguinoscopy, diaeresis by planes, identification of weakness in the posterior wall, opening and repair were performed in aponeurosis of the external oblique muscle, exploration of the inguinal canal and inguinal herniorrhaphy with placement of a polypropylene mesh and fixation with 2.0 prolene thread.



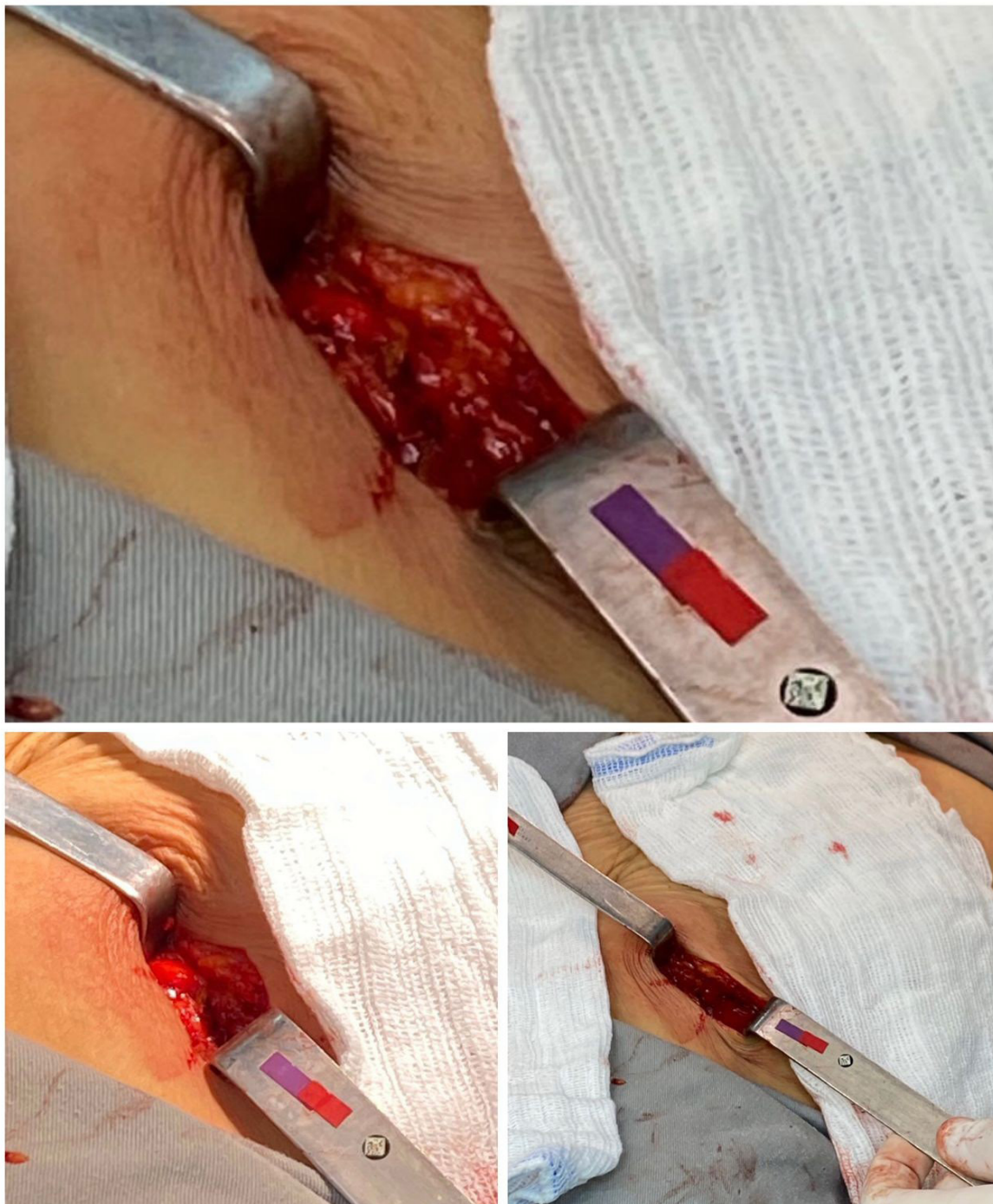
Picture 1 - Preoperative: lateral border of the rectus abdominis muscle.



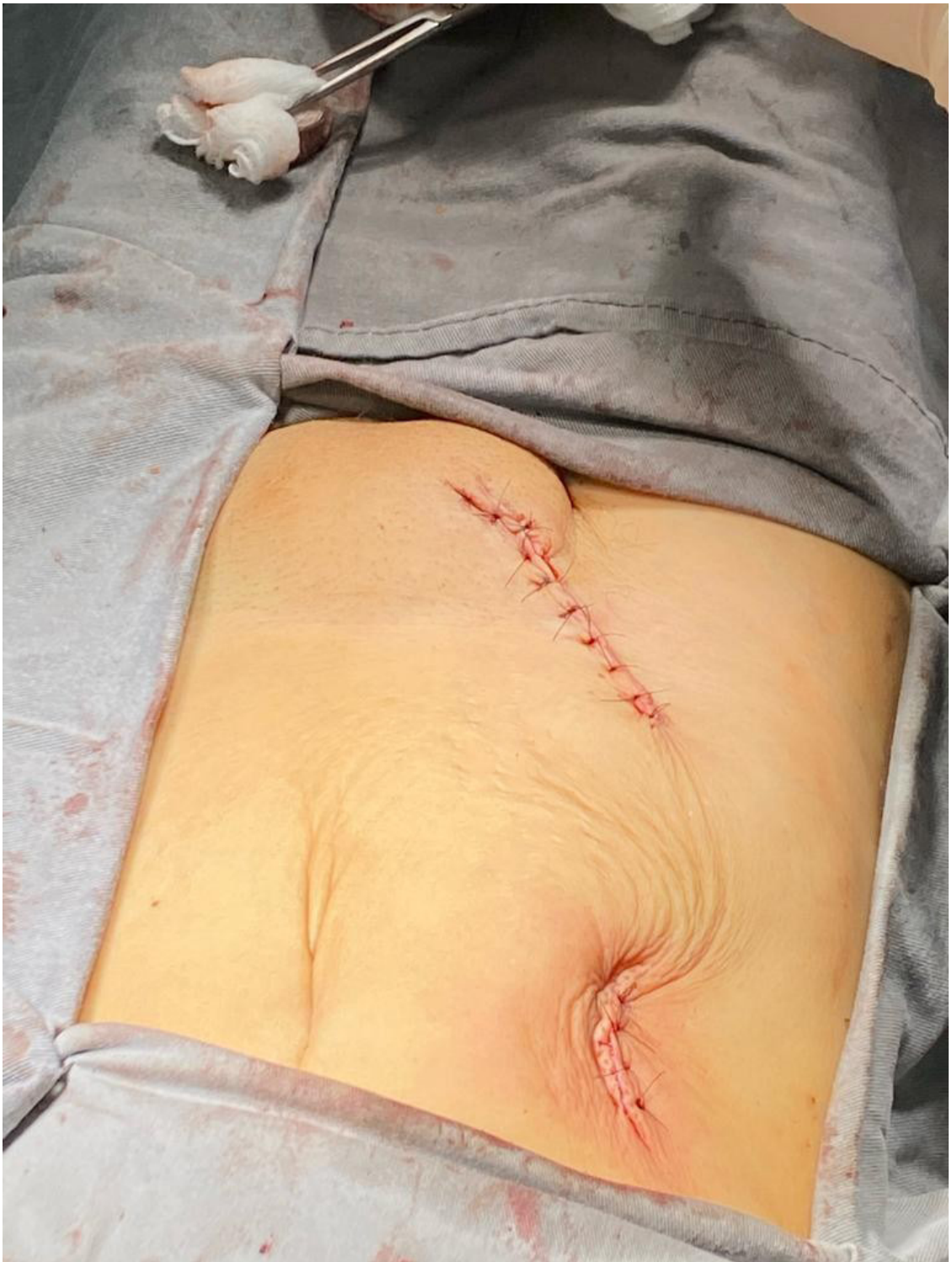Picture 2 - Identification of right inguinal hernia.

For the repair of Spiegel's hernia, a right paramedian incision was made with reference to the umbilical scar, dieresis by planes, identification of weakness in the ipsilateral semilunar line, reinforcement of Spiegel's aponeurosis with imbrication of the right

rectus abdominis muscle. Finally, a review of the hemostasis, synthesis by planes and closed dressing. The procedure was completed uneventfully and there were no postoperative complications.



Picture 3 - Identification of Spiegel's hernia.



Picture 4 - Immediate postoperative period: oblique scar in the right inguinal region above and scar in the right paramedian region below.

DISCUSSION

Spiegel's hernias are rare and represent only 0.1 to 2% of all ventral hernias. This condition is a benign surgical entity, and may be congenital or acquired. Among the main risk factors for its occurrence, obesity, rapid weight loss, multiple pregnancies, COPD, chronic constipation, ascites, trauma and previous surgical procedures stand out³. These conditions not only determine increased intra-abdominal pressure but also cause further weakening of the abdominal wall.⁴

The incidence of Spiegel's hernia is predominant in female adults, especially between 40 and 70 years of age. Thus, making an analogy with the patient in the case in question and the epidemiological aspects found in the literature, there is a similarity between the age and sex variables, reaffirming the higher prevalence of the disease in females and after the fourth decade of life. Although still uncommon, it is important to note that an increase in the incidence of the disease has been observed, which may be related to the widespread use of high-quality cross-sectional images, misdiagnosis of lateral incisional hernias, or a real increase due to the epidemic of obesity³.

With regard to the etiopathogenesis of the disease, some theories stand out in order to justify the weakening of the abdominal wall that is usually seen. One of them involves the existence of relatively large holes in the Spiegelian aponeurosis through which abdominogenital vessels and nerves penetrate (neurovascular theory), in addition to others described as the muscle-aponeurotic fasciculation theory and the embryological transition theory⁵.

Although Spiegelian hernias can develop anywhere along the entire length of the Spiegelian aponeurosis, they are most often seen to occur in the region just below the level of the umbilicus to the interspinous plane (a

horizontal line between the spine right and left anterosuperior iliac artery) and mainly on the left flank. Because of this, such an area is often referred to as the Spiegelian hernia belt. However, one more interesting point is observed in the presented case, where the patient presents Spiegel's hernia in the right flank, different from what is found in most patients with this condition.³

With regard to the physical examination, the hernia can be palpated laterally to the rectus abdominis muscle, being better evidenced by performing the Valsalva maneuver. However, in most cases it is not so common to notice the presence of the hernia, since it does not break the external oblique aponeurosis, keeping it intact and, thus, covering the defect of the abdominal wall. Therefore, the absence of typical symptoms and the lack of medical experience with this type of hernia can make early diagnosis difficult.⁴

In order to confirm the hernia, imaging methods such as Ultrasonography and CT of the abdomen can be used. In addition, they also allow anatomical visualization with limits and hernia content⁶. Surgical treatment of Spiegel's hernia is mandatory, in addition to being the only effective treatment, as there is a high risk of incarceration and strangulation. In the case of strangulated and acutely incarcerated Spiegelian Hernias, surgical repair must be urgent.⁵

Choice for the best approach includes symptoms, increased risk of acute presentation (eg, intestinal containment or prior incarceration), and patient choice. In the case of the patient presented, the surgical approach was chosen due to persistent pain. Because it is infrequent, there is still no surgical technique considered ideal for its correction⁵. However, a variety of approaches are available, including open, laparoscopic and robotic repairs. Among the laparoscopic techniques,

the transabdominal approach (intraperitoneal onlay mesh [IPOM] and transabdominal preperitoneal [TAPP]) stands out, as well as totally extraperitoneal approaches (TEP), in addition to robotics.³

In elective situations, whenever possible, minimally invasive techniques are preferred. They have as absolute contraindications the inability to tolerate pneumoperitoneum or safely access the peritoneal cavity. Relative contraindications include: lack of experience and/or appropriate resources by the surgeon, perforation of the GI tract or acute high-grade obstruction, and early bowel resection. The approach of choice for the patient in this case was the open repair technique, which may be preferred in the context of an acute presentation, presentation with high-grade intestinal obstruction and/or perforation, anticipation of intestinal resection, lack of familiarity and/or surgeon's experience with laparoscopic techniques and/or surgeon's preference³.

After elective repairs (both laparoscopic and open), most patients can be discharged the same day using a perioperative narcotic minimization regimen. For patients who present acutely, hospitalization may be necessary depending on the clinical status of the patient. Patients must be seen postoperatively in approximately two to four weeks to assess for any postoperative complications. Signs of surgical site infection, including erythema and/or drainage at wound sites, inability to tolerate oral intake, poor bowel function, or worsening pain must prompt the patient to seek urgent care. The follow-up of the referred patient was carried out as recommended, and she was discharged the following day and reassessed in one week, with no postoperative complications.³

It is noteworthy that, in addition to Spiegel's hernia, the patient in question also had a direct inguinal hernia on the right,

which reinforces the relevance of the case. Direct inguinal hernias account for 30 to 40% of inguinal hernias in men, but approximately 14 to 21% of inguinal hernias in women. They project medially to the inferior epigastric vessels within Hesselbach's triangle, which is formed by the inguinal ligament (Poupart's ligament) inferiorly, the inferior epigastric vessels laterally, and the rectus abdominis muscle medially.⁷

Direct inguinal hernias occur as a result of weakness in the floor of the inguinal canal. This weakness appears to be due to connective tissue abnormalities in many cases, although some may be due to deficiencies in the abdominal musculature resulting from chronic stretching or injury. Direct hernias are classified as medial hernias in the European Hernia Society groin hernia classification system.⁷

For the patient in the case, who had both inguinal and Spiegelian hernias, the most appropriate treatment consisted of performing the approach to the direct inguinal hernia with an open mesh without tension. Studies demonstrate that this type of inguinal hernia repair reduces postoperative groin pain, speeds up recovery, and reduces the rate of recurrence. Tension-free repairs that use mesh include Lichtenstein, plug and patch, and preperitoneal repair (Kugel or Rives-Stoppa)⁸.

CONCLUSION

Spiegel's hernia represents a rare condition, the diagnosis of which is usually established by exclusion. The association of Spiegel's hernia with a direct inguinal hernia is even more unusual. Adequate preoperative diagnosis depends on medical experience and it may be necessary to use imaging methods such as ultrasound and computed tomography of the abdomen. This is the mandatory treatment, since this specific

type of hernia carries a significant risk of strangulation of its contents.

REFERENCES

1. Guimarães VHM, Andrade CFI, Magalhães GMC, Guerra SNE. Hérnia de Spiegel após Abdominoplastia. *Rev. Bras. Cir. Plást.*1997;12(1):57-64
2. Chaib PS, Coltri RP, Castro MMO. Hérnia de Spiegel bilateral volumosa. *Relatos Casos Cir.*2017;(4):1-5
3. Shah, S. K., & Liang, M. K.(2022). Spigelian hernias. In M. Rosen., W. Chen (Ed.), *UpToDate*. Acessado em agosto 24, 2022
4. Parreira, José Marcos et al. Hérnia de Spiegel bilateral: relato de caso e revisão de literatura. *ABCD. Arquivos Brasileiros de Cirurgia Digestiva (São Paulo)* [online]. 2007, v. 20, n. 3 [Acessado 15 Novembro 2022], pp. 208-211
5. Chaib PS, Coltri RP, Castro MMO. Hérnia de Spiegel bilateral volumosa. *Relatos Casos Cir.*2017;(4):1-5
6. Light, D., Chattopadhyay, D., & Bawa, S. (2013). Radiological and clinical examination in the diagnosis of Spigelian hernias. *Annals of the Royal College of Surgeons of England*, 95(2), 98–100
7. Brooks, D, C., & Hawn, M., (2022). Classification, clinical features, and diagnosis of inguinal and femoral hernias in adults. In M. Rosen., W. Chen (Ed.), *UpToDate*
8. Brooks, D, C., (2022). Overview of treatment for inguinal and femoral hernia in adults. In M. Rosen., W. Chen., *UpToDate*