

**IN VIVO THERAPEUTIC
EVALUATION OF A
CELLULOSE ACETATE
HYDROGEL CROSS
LINKED WITH
ETHYLENEDIAMINE-
TETRAACETIC-
DIANHYDRIDE
CONTAINING PROPOLIS
ETHANOLIC-EXTRACT
FOR TREATING BURNS**

Moema de Alencar Hausen

Biomaterial's Laboratory, Medicine and Health Sciences Faculty, Pontifical Catholic University of São Paulo (PUC/SP), Sorocaba, São Paulo, Brazil
<https://orcid.org/0000-0002-7131-4045>

Anna Maria Gouvea Melero

Department of Physics, Chemistry and Mathematics, Federal University of São Carlos (DFQM/UFSCAR), Sorocaba, São Paulo, Brazil

Jessica Asami

Biomaterial's Laboratory, Medicine and Health Sciences Faculty, Pontifical Catholic University of São Paulo (PUC/SP), Sorocaba, São Paulo, Brazil
Faculty of Mechanical Engineering, State University of Campinas (FEM/UNICAMP), São Paulo, Brazil

All content in this magazine is licensed under a Creative Commons Attribution License. Attribution-Non-Commercial-Non-Derivatives 4.0 International (CC BY-NC-ND 4.0).



Lucas Martins Ferreira

Biomaterial's Laboratory, Medicine and Health Sciences Faculty, Pontifical Catholic University of São Paulo (PUC/SP), Sorocaba, São Paulo, Brazil

Guilherme Borges Gomes da Silva

Biomaterial's Laboratory, Medicine and Health Sciences Faculty, Pontifical Catholic University of São Paulo (PUC/SP), Sorocaba, São Paulo, Brazil

Mariana Cesar de Azeredo Bissoli

Biomaterial's Laboratory, Medicine and Health Sciences Faculty, Pontifical Catholic University of São Paulo (PUC/SP), Sorocaba, São Paulo, Brazil

Vanessa Rigoni Marcato

Biomaterial's Laboratory, Medicine and Health Sciences Faculty, Pontifical Catholic University of São Paulo (PUC/SP), Sorocaba, São Paulo, Brazil

Bruno Dias Nani

Piracicaba Dental School, University of Campinas (FOP/UNICAMP), Piracicaba, São Paulo, Brazil

Pedro Luiz Rosalen

Piracicaba Dental School, University of Campinas (FOP/UNICAMP), Piracicaba, São Paulo, Brazil

Severino Matias de Alencar

Luiz de Queiroz College of Agriculture, University of São Paulo (ESALQ/USP), Piracicaba, São Paulo, Brazil

Vagner Roberto Botaro

Department of Physics, Chemistry and Mathematics, Federal University of São Carlos (DFQM/UFSCAR), Sorocaba, São Paulo, Brazil

Post-Graduation Program in Materials Science (PPGCM), Federal University of São Carlos (UFSCAR), Sorocaba, São Paulo, Brazil

Daniel Komatsu

Biomaterial's Laboratory, Medicine and Health Sciences Faculty, Pontifical Catholic University of São Paulo (PUC/SP), Sorocaba, São Paulo, Brazil

André Senna

Department of Physics, Chemistry and Mathematics, Federal University of São Carlos (DFQM/UFSCAR), Sorocaba, São Paulo, Brazil

Eliana Aparecida de Rezende Duek

Biomaterial's Laboratory, Medicine and Health Sciences Faculty, Pontifical Catholic University of São Paulo (PUC/SP), Sorocaba, São Paulo, Brazil

Faculty of Mechanical Engineering, State University of Campinas (FEM/UNICAMP), São Paulo, Brazil

Post-Graduation Program in Materials Science (PPGCM), Federal University of São Carlos (UFSCAR), Sorocaba, São Paulo, Brazil

Abstract: An increasing interest in regenerative medicine has been an approach with natural products used for assorted skin treatments. Propolis from *Apis mellifera* species of bees have shown high acceptance due to antimicrobial and anti-inflammatory properties. However, just a few propolis types presents stronger effects in controlling inflammation. The current work describes an organic propolis recently isolated, named as OP6, that presented strong anti-inflammatory influences *in vivo* when associated with EDTA cross-linked hydrogel, used as a curative device in second-degree burns in a murine model. We developed a cellulose acetate hydrogel cross-linked with ethylenediaminetetraacetic dianhydride (HAC-EDTA) as a polymeric matrix for a bandage based on an ethanolic extract of propolis at 15%, 30%, and 60% (w/v) for treating second-degree burns. *In vivo* studies were carried out in Wistar rats divided into three groups: negative control (only lesion), positive control (lesion with HAC-EDTA film), and treatment group (lesion with the HAC-EDTA + OP6 at 15%, 30%, and 60%). Each group was randomized and equally subdivided into two subgroups according to the period of bandage wearing (7 and 14 days). Previous work of this research group selected the propolis OP6 sample source as the best candidate for the *in vivo* study. HAC-EDTA + OP6 15%, 30%, and 60% films demonstrated a concentration-dependent release rate, with the highest amount of propolis released after tests (484.3 mg) by HAC-EDTA enriched with the highest concentrated extract of propolis. HAC-EDTA + OP6 films were efficient in preventing infections, promoting lesion retraction, and tissue regeneration. The HAC-EDTA + OP6 30% treatment was more efficient, revealing a reduced inflammatory process and stimulating skin regeneration. The designed HAC-EDTA + propolis films

were shown as promising tools for second-degree burns treatment, accelerating healing process to a full recovery tissue repair after 14 days.

Keywords: Propolis, second-degree burns, healing, hydrogel.

INTRODUCTION

Burns and related injuries are still a significant public health problem, accounting for about 30,000 new cases per day worldwide and 11 million new burns each year.¹ World Health Organization (WHO) data estimate 180,000 deaths related to burns annually, especially in low- and middle-income countries.² The more severe the injury is, the deeper the lesion—considering first-degree for lesions reaching only epidermis, second-degree if it affects dermis (with risk of scars), and third-degree affecting all the skin's structures, depending on medical intervention for healing.³

The tegument is the biggest organ in the body, composed of (1) skin and (2) epidermal derivatives, including nails, hair, and glands (sweat, sebaceous, mammary). The skin plays a crucial role as a protection organ against injuries, pathogens, and chemical agents. It is an impermeable barrier and sensory organ that also works in body temperature regulating, salt excreting, vitamin D synthesizing, and sexual signaling.^{4,5} In general, the cellular repairing process occurs almost equally in all human body tissues regardless of the suffered harmful stimulus.⁶

In case of minor damage to the epidermis, in which the basal membrane underlying it remains intact, tissue repair is based on cellular repair. Skin epidermal cells multiply rapidly through stem cell differentiation and reconstitute the injured tissue. If the regeneration is not enough due to the destruction of the epidermal membrane, the cicatrization process occurs by deposition of

connective tissue on the injured area.⁶ The classical response to tissue injury is divided into three overlapping phases: inflammation (acute or chronic), proliferation and new tissue formation (fibrogenesis and angiogenesis), and maturation (or remodeling).^{7,8}

The first stage is triggered just after tissue damage with the recruitment of defense circulating cells and molecules, aiming to prevent blood and fluid losses, remove damaged components, and prevent infections.⁷ Then, homeostasis is reached by the action of leukocytes, phagocytes, antibodies, and complement cascade proteins.⁸ Next, in about 2–10 days, the second stage takes place with cell proliferation and migration. Keratinocytes and fibroblasts move to the injured dermis, and the angiogenesis occurs as a result of cytokines and growth factors (PDGF, FGF-2, and TGF- β) from inflammatory cells, especially Macrophages M2. Besides, fibroblasts produce collagen, forming the bulk of the mature scar.^{7,9,10} Finally, the remodeling stage starts after 2–3 weeks of injury, in which lesion-activated processes are finished, and recruited cells (macrophages, fibroblasts, keratinocytes) undergo apoptosis or leave the wound^{11–13} The result is a mass containing cells, collagen, and extracellular matrix components. Then, collagen type III is remodeled to collagen type I, leading to scar formation and barrier restoration.¹¹

The burn healing process requires high-cost specific dressings and protocols, which demand constant improvements and developments to produce an effective low cost dressing.³ Currently, several products are available for burn lesion care as cream, solution, and dressing.^{14,15}

Polymeric bandages have shown effectiveness in burn-related injury treatment in terms of their cost and clinical efficiency relation.¹⁶ However, despite all polymeric bandage properties, the isolated use of these

materials may not be sufficient to promote the healing process since many of these materials do not have therapeutic activity.

Propolis, a natural resinous substance from honey bees, has shown several biological benefits, particularly considering its antimicrobial, anti-inflammatory, and immunomodulatory properties, which directly contribute to wound repair and tissue regeneration.^{3,17–19} Thus, in this study, we developed a bandage based on ethanolic extract of *Apis mellifera* propolis using a polymeric matrix based on cellulose acetate hydrogel cross-linked with ethylenediaminetetraacetic dianhydride (HAC-EDTA). *In vivo* tests were carried out investigating concentrations of 15%, 30%, and 60% (m/v) of propolis and at increased time of use of bandage.

METHODS

HAC-EDTA AND PROPOLIS OP6 OBTENTION METHOD

HAC-EDTA films were obtained at the Federal University of São Carlos, campus Sorocaba, São Paulo, Brazil, following the protocol described by Senna and colleagues.^{20,21} The hydrogel was obtained by a homogeneous reaction between hydroxyl groups and cellulose acetate with a degree of substitution of 2.5. The synthesis were performed through esterification crosslinked with EDTA dianhydride.²¹ The cellulose acetate was acquired from Rhodia®.

Propolis samples were collected from *Apis mellifera* beehives in the state of Parana and Santa Catarina, Brazil, georeferenced exactly as described by elsewhere.²² Ethanolic extracts of propolis were prepared using 320 g of *A. mellifera* collected propolis (dry weights) mixed with 4 L of ethanol 80% and shaken for 30 min at 70°C. Then, this mixture was kept at –20°C for 12 h, filtered, concentrated on a rotary evaporator, and lyophilized.

HAC-EDTA AND PROPOLIS FILM

The HAC-EDTA films were swelled in distilled water, cut into 3 cm × 3 cm rectangular samples, and kept drying overnight. Ethanolic extract of propolis was defrosted in water at room temperature, the pasty-shaped substance was taken, and 3, 6, and 12 g of this substance were transferred to 2 mL of alcohol 70%. These solutions were shaken for 30 min to obtain propolis solutions at a concentration of 15%, 30%, and 60%, respectively. Ten samples of dried HAC-EDTA films were immersed in 15%, 30%, and 60% propolis solutions and shaken overnight at room temperature to obtain propolis enriched films. The positive control sample was prepared using the same protocol, but HAC-EDTA was immersed in alcohol 70% instead of ethanolic extract of propolis. Before the assays, HAC-EDTA films were previously immersed in saline solution for 1 h (alcohol removing step).

IN VIVO ASSAYS

Two-month old healthy SPF male Wistar rats ($n = 60$) weighing about 300 g were obtained from the Faculty of Medical and Health Sciences of the Pontifical Catholic University of São Paulo (FCMS/PUC-SP) bioterium. All the animals were housed in individual cages under a light-dark cycle 12:12 h on controlled temperature ($23^{\circ}\text{C} \pm 2^{\circ}\text{C}$), fed with commercial food and water provided *ad libitum*. The animals were randomly assigned into five groups ($n = 12$ each): negative control (submitted to injury and by a curative of gauze bandage); positive control, injured and submitted to a curative of HAC-EDTA film (propolis-free); and other three injured groups submitted to a curative containing different concentrations of propolis (w/v) in the HAC-EDTA film, named as HAC-EDTA+ OP6 15%; HAC-EDTA+ OP6 30%; HAC-EDTA+ OP6 60%.

Thus, each group was equally divided into two subgroups to evaluate the healing time course after 7 and 14 days after surgical burn procedure.

SURGICAL PROCEDURE

All experiments described in this study were conducted following international standards for animal experimentation (National Research Council, 1996), and following approval by Faculty of Medical and Health Sciences of Pontifical Catholic University of São Paulo Ethics Committee (Approval Protocol n. 2017/75). Animals underwent anesthesia and neuromuscular blocking by intramuscular injection of ketamine hydrochloride (90 mg/kg) and xylazine hydrochloride (5 mg/kg) solution. After anesthesia, animals were trichotomized in the dorsocervical region. Then, a second-degree burn was done in a square area of 4.0 cm² (2 cm × 2 cm) according to Walker and Manson protocol.²³ In this protocol, the trichotomized region was exposed to a 70°C water bath for 10 s. For treatment groups, burn lesions were covered by HAC-EDTA+ OP6 15%, 30%, or 60% (w/v). HAC-EDTA without propolis extract was used for positive control. In the negative control, the lesion remained with no treatment. Elizabethan collars were used to prevent animals from removing the bandages or accessing the lesion. Animals were then euthanized 7 and 14 days after the burn procedure by halothane inhalation. Afterward, tissue samples were collected and immediately immersed in formaldehyde 10% solution for fixation for 24 h and sent to conventional histological tissue processing techniques. Tissues were stained with hematoxylin and eosin (HE). Images obtained were digitally acquired by the light microscopy system (Nikon E800 equipped with a DS-Ri1 camera).

SAMPLES PROCESSING

All the collected samples were prepared for microscopy analyses, as follows: (1) samples were washed in buffer solution and dehydrated in ethanol solutions with increasing concentration of 70% (24 h), 80% (30 min), 95% (30 min), and 100% (3 min × 30 min); (2) diaphanization were carried out in a solution 1:1 of absolute ethanol/xylol for 30 min, and immersion in pure xylol solution for 60 min; (3) samples were, then, immersed in 1:1 xylol/paraffin (Histosec-Merck®) at 60°C for 30 min, and in pure liquid paraffin for 3 h. Tissues were placed in a 5 cm³ mold and embedded in paraffin at 60°C and kept for 24 h at room temperature for polymerization. The blocks were sectioned with 3.0 μm of thickness in a Leica® RM2245 microtome and stored at 60°C for paraffin excess removal. The deparaffinization step was carried out by immersing the samples twice in xylol for 20 min, followed by the hydration step in 100% (5 min), 95% (5 min), 80% (5 min), 70% (5 min) ethanol, and distilled water (several washes). The sections were then stained using the hematoxylin-eosin protocol. Histological analyses were carried out in a NIKON®—E 800 light microscope.

PROPOLIS CONTROLLED RELEASE ASSAY

Controlled release of propolis was analyzed for all 15%, 30%, and 60% HAC-EDTA+OP6. Samples were individually immersed in 4 mL of PBS solution and kept at 37°C. Periodic sample measurements were performed using a UV-Vis Femto RX800 spectrophotometer (λ = 320 nm) until the time of 222 h. The amount of propolis was then calculated based on a standard curve of known concentration values.

In case of drug release, mathematical models are essential means of predicting release mechanisms, as well as over-time drug

concentration in the body, which determines the biological efficacy of developed drug delivery systems. In this regard, several models have been introduced, but none of them could act as a perfect universal model. Thus, the Korsmeyer-Peppas model is usually the polymeric systems of choice.²⁴ This model was developed specifically for the release of a drug molecule from a polymeric matrix, such as a hydrogel. The model describes the release mechanism that follows both diffusion and erosion of polymer chains.²⁵ According to the Korsmeyer-Peppas model, where M_t is the amount of propolis released at time t , M_∞ is the total amount of propolis used for the release study, K is the release rate constant incorporating structural and geometric characteristics of the drug dosage form, and n is the release exponent. K , n , and regression coefficient values were determined by plotting $\ln(M_t/M_\infty)$ versus $\ln(t)$.

$$\frac{M_t}{M_\infty} = K.t^n$$

RESULTS

HAC-EDTA PROPOLIS RELEASE RATE

The next step was to determine whether the release of propolis active compounds could be achieved when the HAC-EDTA+OP6 films were kept in contact with PBS solution at 35°C. The tested formulations showed biphasic release patterns with an initial burst of propolis release followed by sustained release after 150 h. Thus, obtained data pointed out a fast initial release rate of propolis with values of 7.5, 28.9, and 52.1 mg.h⁻¹ for concentrations of 15%, 30%, and 60% of propolis, respectively (Figure 1). Furthermore, it is possible to observe that the sample HAC-EDTA+OP6 60% is the one that released the greatest amount of propolis. This showed that the greater concentration

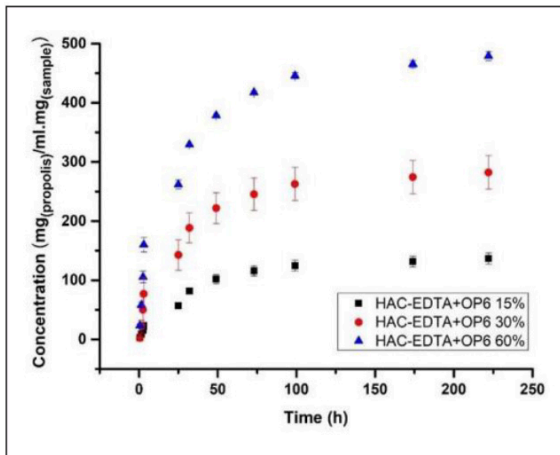


Figure 1. Data of Controlled release of propolis assays with HAC-EDTA films.

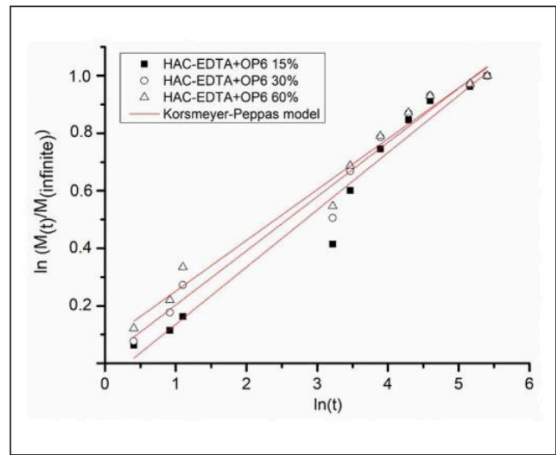


Figure 2. Data fitted to Korsmeier-Peppas model to describe the release kinetics of propolis from HAC-EDTA + OP6 15%, 30%, and 60% films.

of propolis incorporated in the sample, the greater the amount of propolis was released by film. Propolis active components were released for more than 1 week.

The mechanism of propolis release was analyzed using the Korsmeier-Peppas model (Figure 2). It is possible to note that the n values (release exponent) did not change with propolis concentrations (HAC-EDTA+OP6 15% / $n = 19,985$) (HAC-EDTA+OP6 30%/ $n = 01884$) (HAC-EDTA+OP6 60%/ $n = 19,985$).

BURN-INJURY HEALING ANALYSIS

After second-degree burn induction and HAC-EDTA curative implantation, all groups were monitored for 7 and 14 days depending on the treatment. All the animals presented an evolving healing process. Animals from the negative control (without any treatment) showed lesions with purulent exudates (Figure 4), while positive control animals evidenced serous exudate and humid injury, especially after 7 days, a condition possibly related to HAC-EDTA features and lesion covering (Figure 5). For HAC-EDTA+OP6 15% (Figure 6) and HAC-EDTA+OP6 30%

(Figure 7), treatment groups, we observed few or no evidence of exudate injury, with wound area decreasing, particularly for HAC-EDTA+OP6 30% group, in which no lesion exudate was found, and the formation of an extensive and thin crust with areas of the newly formed epidermis was observed, with lesion edges almost indistinguishable from the skin. In general, negative and positive control groups as well as HAC-EDTA+OP6 15% treatment group did not show a very evident tissue neoformation, and HAC-EDTA+OP6 30% and 60% groups presented an enhanced regenerative process with purulent exudates (Figure 4), while positive process, figures 7 and 8, respectively.

HISTOLOGICAL DATA

Histological analysis evidenced tissue neoformation in all experimental groups. Negative control group samples showed an irregular epidermis with the presence of granulation and exudate. In the positive control samples, we found a partial regeneration, and inflammatory infiltrates were absent. Both negative and positive control groups evidenced little or no regeneration of cutaneous

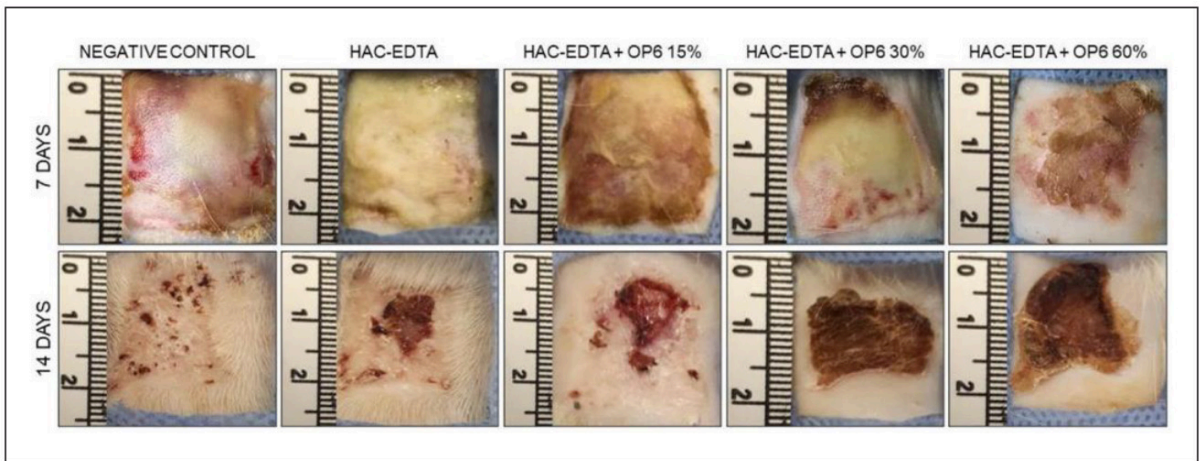


Figure 3. Macroscopic images presentation of the burned area immediately after being excised for histology processing, after 7 and 14 days. Positive and negative control groups, HAC-EDTA + OP6 15%, HAC-EDTA + OP6 30%, and HAC-EDTA + OP6 60% treatment groups.

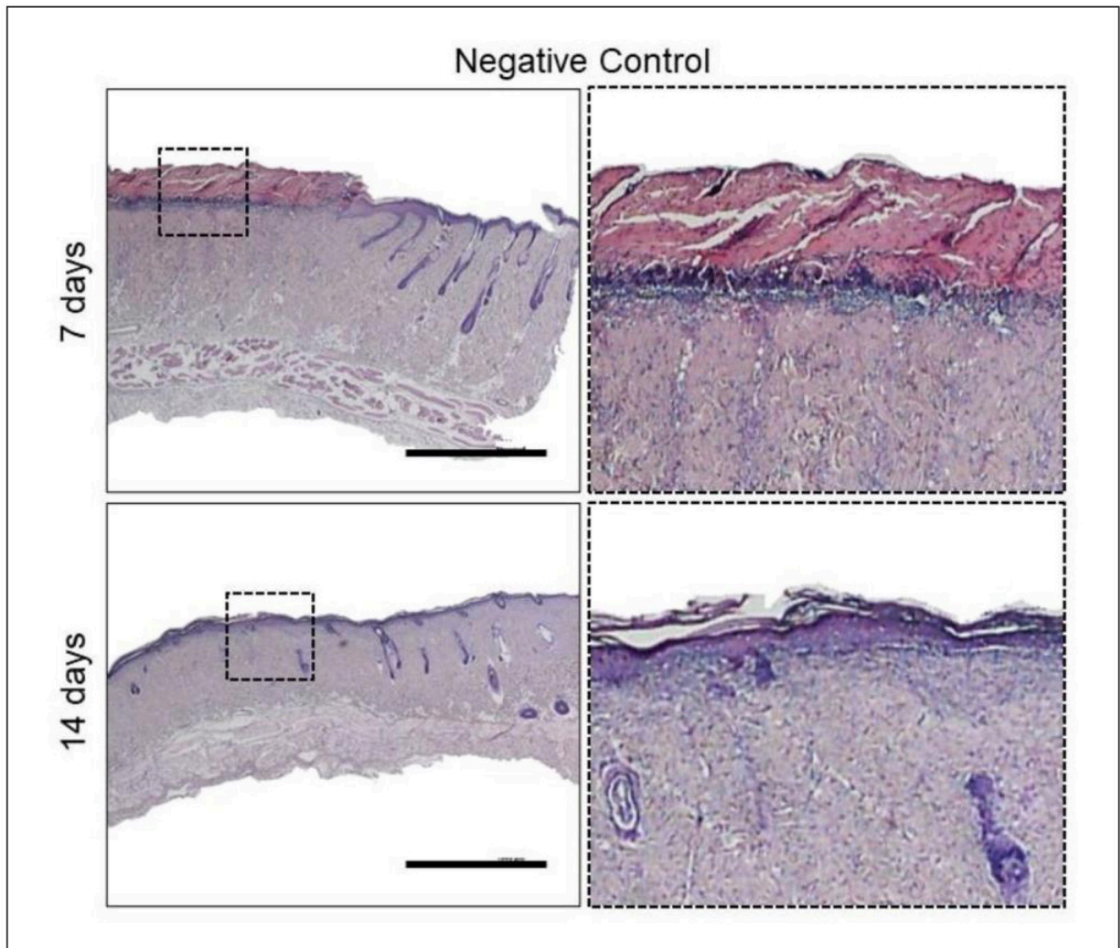


Figure 4. Histological sections of the burned area after 7 and 14 days under healing. Negative control (received gauze only as curative) samples at panoramic (left) and higher magnification (right). Bars 5 mm.

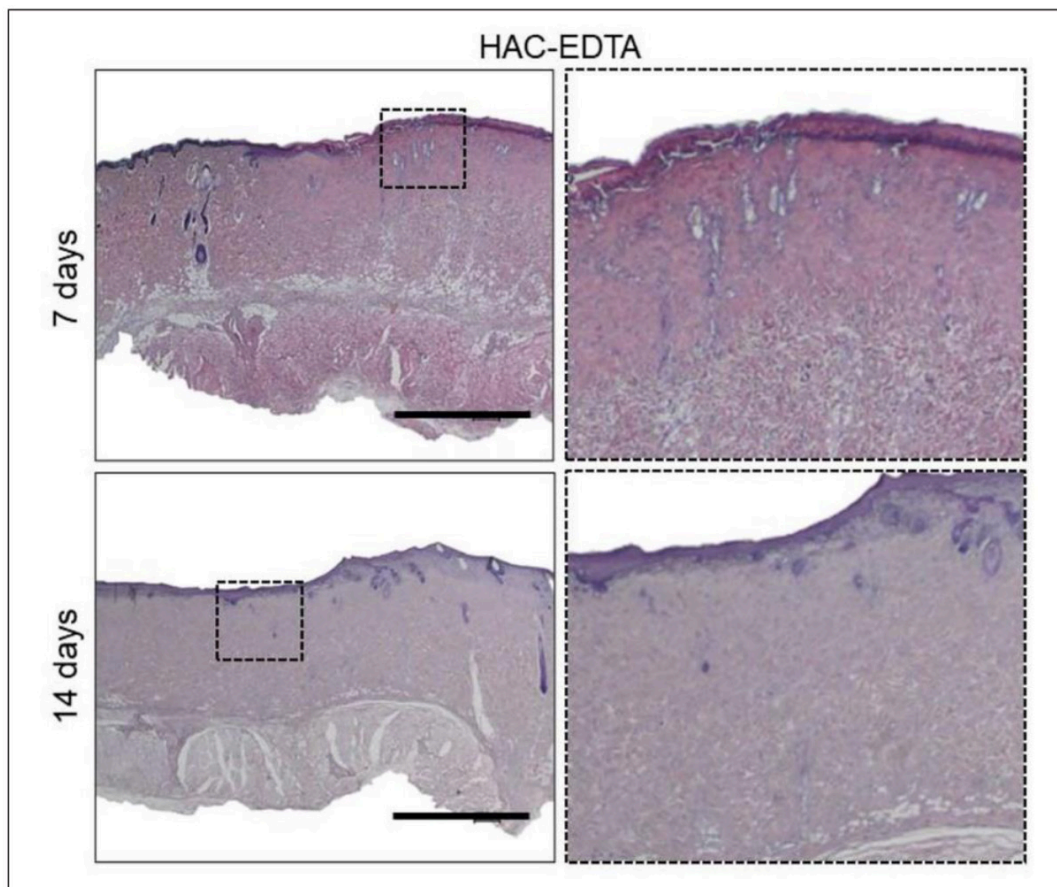


Figure 5. Light microscopy images of histological sections of burn-related lesions after 7 and 14 days of the experiment of positive control groups containing HAC-EDTA only. Bars 5 mm.

annexes. However, in all the treatment groups (HAC-EDTA + OP6 15%, HAC-EDTA + OP6 30%, and HAC-EDTA + OP6 60%), the regeneration process was enhanced. For HACEDTA + OP6 15% group, we found a more pronounced reepithelization than in the positive control, while HAC-EDTA + OP6 30% and HAC-EDTA + OP6 60% groups showed evidence of the reepithelialization of the remaining cutaneous annexes. HAC-EDTA + OP6 30% group data pointed out a more balanced modulation of the inflammatory process compared to 15% and 60% groups and, consequently, a better regenerative process. Besides, the wound edges and remaining deep appendages are significant in clarify the involved mechanisms. the reepithelization process. In second-degree

burn lesions, these appendages are located in the upper layers of subcutaneous fat, mediating an inductive process in the regenerative process. These phenomena were more evidenced in the HAC-EDTA + OP6 30% group.

In the HAC-EDTA+ OP6 60% group, we observed a higher concentration of propolis in the lesion, which could trigger a more accentuated inflammatory process compared to the HAC-EDTA+ OP6 30% group. This finding aligns with HAC-EDTA propolis release obtained data which pointed out the highest release rate for HAC-EDTA+ OP6 60% films. Further studies on dose-response for these different concentrations of propolis are needed to clarify the involved mechanisms.

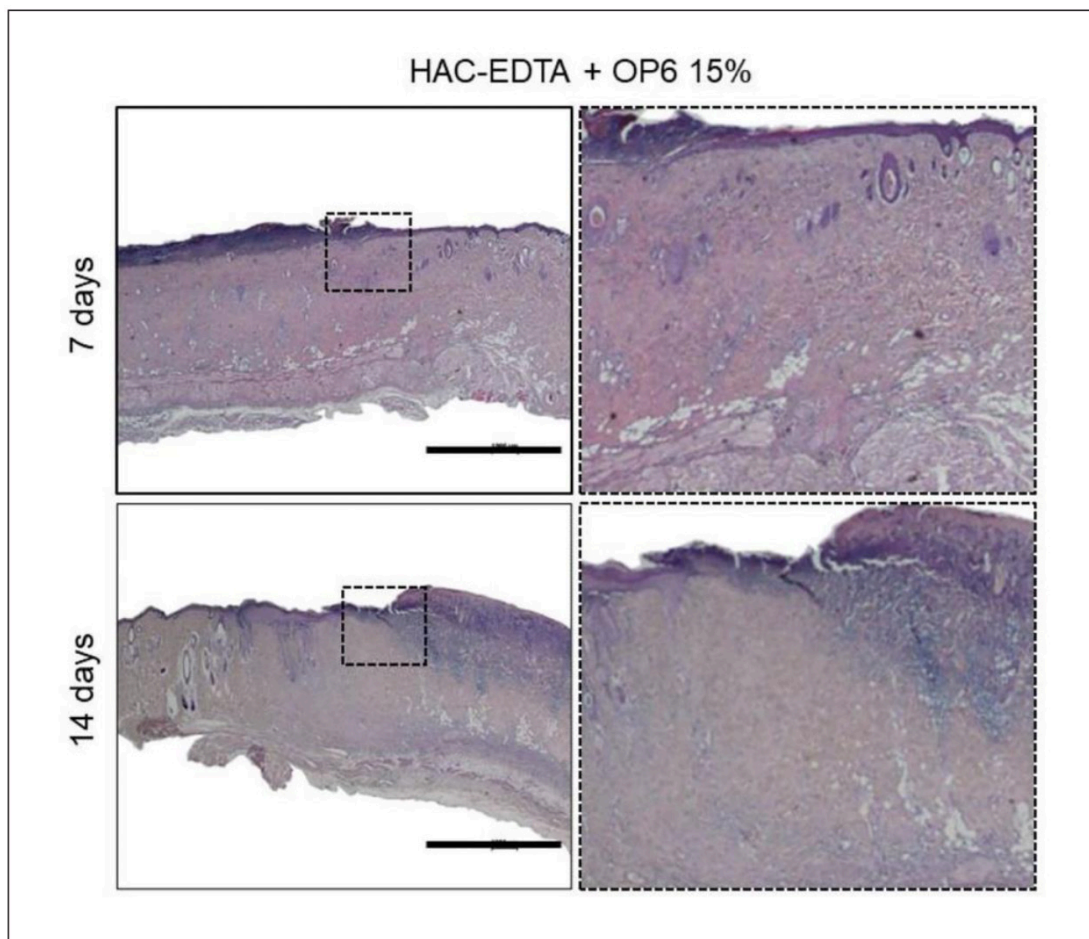


Figure 6. Light microscopy images of histological sections of burn-related lesions after 7 and 14 days of the experiment of positive control groups containing HAC-EDTA + OP6 15%. Bars 5 mm.

DISCUSSION

The release profile was concentration-dependent process. These phenomena were more evident when incorporated into HAC-EDTA films. Observed in the HAC-EDTA + OP6 30% group. Thus, the highest concentration of propolis released at the end of the assays reached around $484.3 \text{ mg}_{(\text{propolis})}/\text{ml} \cdot \text{mg}_{(\text{sample})}$). Furthermore, the greater amount of propolis in the sample also reflected in higher surface deposition of propolis at samples, leading to a wide release of propolis at early times, which justify the faster initial release rate of propolis by HAC-EDTA+ OP6 60% as compared to the other samples. After the early time of controlled release testing, the propolis delivery

continues for more than a week. In this case, the mechanism that drives propolis release from samples is given by controlled diffusion of propolis in the inner part of the sample. A similar pattern was obtained by other authors²⁶ in propolis based-chitosan varnish at concentration of 15%, the rapid release of propolis followed by a long-term sustained release is a desired feature in materials when antimicrobial activity for example, is one of the goals.

The diffusion mechanism of propolis release was further confirmed by Korsmeyer-Peppas plots that showed fair linearity (R^2 values between 0.96 and 0.98), with slope values less than 0.5, indicating that propolis

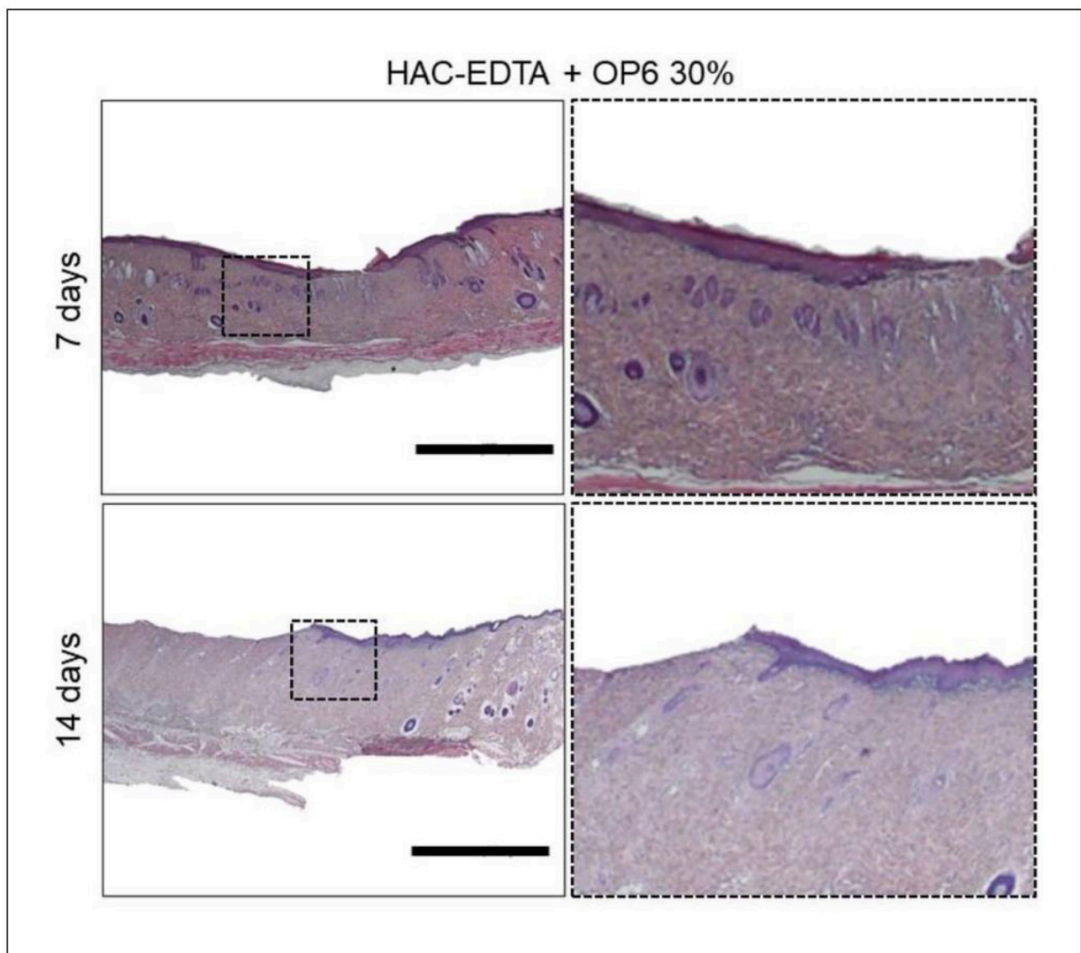


Figure 7. Light microscopy images of histological sections of burn-related lesions after 7 and 14 days of the experiment of positive control groups containing HAC-EDTA + OP6 30%. Bars 5 mm.

release mechanism from the selected samples were controlled diffusion.²⁷ The n values (release exponent) did not change with propolis concentrations (HAC-EDTA+ OP6 15%/n = 19,985) (HAC-EDTA+OP6 30%/n = 01884) (HAC-EDTA+ OP6 60%/n = 19,985). It shows that propolis concentration did not influence the release mechanism. Thus, it is possible to observe that the concentration of propolis did not significantly affect the structure of HAC-EDTA.

The anti-inflammatory activity of ethanolic extract of propolis is well known for decreasing the activation of NF- κ B and delivery of TNF- α in macrophages, and suppressing the pathogenic lipoxygenase pathway via

arachidonic acid metabolism, similar to the dexamethasone action.^{19,22,28,29} Besides, among propolis OP variants, the OP6 presents the highest anti-inflammatory activity,¹⁹ which was the property that elected the OP6 as the variant of choice for this work. The tissue regeneration after burn-related injury triggers several physiological mechanisms, which can be affected by local infection, exacerbated inflammation, and oxidation, with tissue homeostasis and function lost.³⁰ Propolis is a versatile substance with antibiotic, septic, and astringent features, while the flavonoids and phenolic components present antioxidant properties³¹ while inhibiting bacterial motility.²⁸ These propolis characteristics

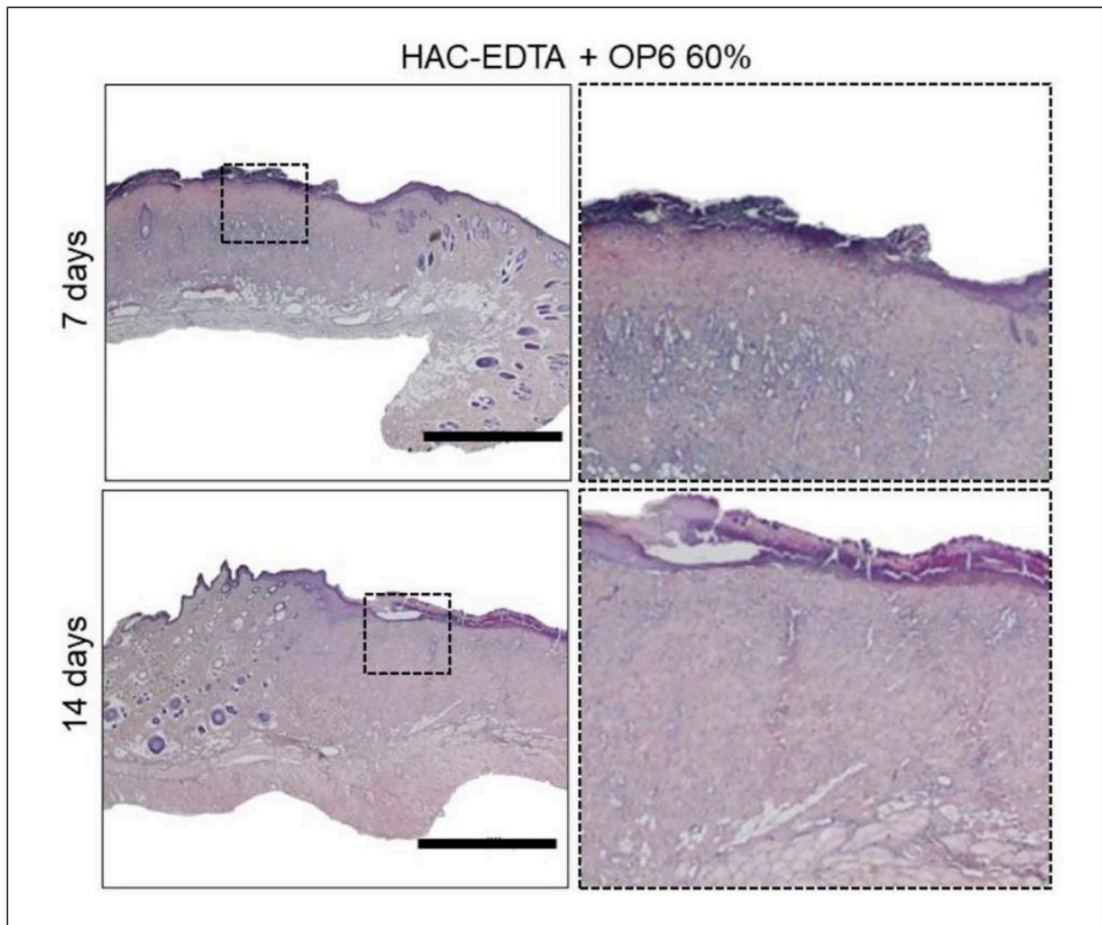


Figure 8. Light microscopy images of histological sections of burn-related lesions after 7 and 14 days of the experiment of positive control groups containing HAC-EDTA + OP6 60%. Bars 5 mm.

prevented exudate formation in the burn-related treatment groups, as highlighted in Figures 2 and 3 as differently identified in the control group.

All propolis concentrations presented effective results in controlling the natural inflammation induced by the second-degree burn. Additionally, the presence of the material itself in positive controls demonstrated a striking decrease in granulation tissue. Although a natural healing course can be observed in negative controls, as observed by the macroscopic appearance (Figure 3), the physical barrier itself induced by the HAC-EDTA prevented exudate formation in positive controls, leading to lower crust formation. As presented macroscopically, although some

persisting crust remained after 14 days in almost all groups, the epidermis presented fully developed in HAC-EDTA 30 and 60%. Thus, its persistence during the healing process was not considered a feature that indicates a chronic inflammatory pattern in all samples. The WUWHs Consensus document (2019)³² about wound exudates states that a desired dressing should retain fluids, induce low adherence to the wound bed and prevent tissue maceration. Such conditions were observed in all HAC-EDTA dressings despite containing OP6 or not. Notwithstanding, the increasing concentrations of OP6 revealed similar healing patterns, except for the highest one (containing 60% of OP6) that revealed a persistent inflammatory infiltrate. As

reviewed recently,³³ some studies showed that increased concentrations of assorted types of propolis can lead to cell death *in vitro* which could unfold in good benefits as an anticancer agent. Thus, the observed remaining infiltrate cells (Figure 8) could be related to continuous high levels of propolis despite the long-lasting controlled release (Figure 1), leading to some toxic cell effects, inducing a quiescent inflammation in the healing dermis. Such feature was not observed at OP6 at 30%, which was then elected as the optimal concentration to induce healing when incorporated to the HAC-EDTA, as compared to OP6 at 15% or 60%. Additionally, the presence of follicles and even some sebaceous glands in the healing site observed at the histology sections of groups HAC-EDTA+ OP6 30% are a clear indication of an early recovery of dermis due to inflammatory remission. Therefore, the contribution to induce functional cutaneous annexes leading to increase the regenerative process in second-degree burns, and the dressing exudate-sequestration feature attributed to HAC-EDTA strongly contributes for future clinical trials as a wound dressing in injured skin.

CONCLUSION

In this study, we developed and studied HAC-EDTA films enriched with ethanolic extract of propolis (OP6) at 15%, 30%, and 60% (m/v) as bandages for treating second-degree burns in a rat model. Results showed the HAC-EDTA+ OP6 approach was efficient in treating the injuries, promoting the cicatrization process, and avoiding infections in the damaged tissue of animal models. Our HAC-EDTA+ OP6 films were able to stimulate lesion retraction with a better healing process and tissue repair. We found that propolis at 30% concentration contributed more to the polymeric bandage, leading to a significant inflammatory reduction and regeneration.

Thus, HAC-EDTA+ OP6 films designed here are promising tools for second-degree burns treatment since they accelerate the healing process and tissue repair.

ACKNOWLEDGEMENTS

Additional thanks to Breyer & Cia Ltda. (PR, Brazil) for propolis supply and to LaBNUS at University of Sorocaba (UNISO) for permission to use the UV-VIS spectrophotometer and to the technical support of Priscila Breda (FCMS-PUC/SP).

DECLARATION OF CONFLICTING INTERESTS

The author(s) declared no potential conflicts of interest with respect to the research, authorship, and/or publication of this article.

FUNDING

The author(s) disclosed receipt of the following financial support for the research, authorship, and/or publication of this article: The authors would like to thank CNPq (grants 306673/2019-3 and 311894/2020-8), PIBIC/CEPE/PUC-SP and to FUNDASP/PUC-SP for the financial support.

REFERENCES

1. Stokes MAR and Johnson WD. Burns in the third world: an unmet need. *Ann Burns Fire Disasters* 2017; 30: 243–246.
2. World Health Organization. *Burns*. <https://www.who.int/news-room/fact-sheets/detail/burns> (2021, accessed 22 November 2021).
3. Krupp T, Dos Santos BD, Gama LA, et al. Natural rubber - propolis membrane improves wound healing in second-degree burning model. *Int J Biol Macromol* 2019; 131: 980–988.
4. Greenhalgh DG. Management of burns. *N Engl J Med* 2019; 380: 2349–2359.
5. Kierszenbaum AL and Tres L. *Histology and cell biology: an introduction to pathology Ebook*. Elsevier Health Sciences, 2015.
6. Kumar V, Abbas AK and Aster JC. *Robbins & Cotran pathologic basis of disease E-Book*. Elsevier Health Sciences, 2020.
7. Gurtner GC, Werner S, Barrandon Y, et al. Wound repair and regeneration. *Nature* 2008; 453: 314–321.
8. Krafts K. Tissue repair. In: Wexler P (ed.) *Encyclopedia of Toxicology*, Vol 4, 3rd ed. Oxford: Academic Press, 2014, pp.577–583.
9. Qiang L, Yang S, Cui Y-H, et al. Keratinocyte autophagy enables the activation of keratinocytes and fibroblasts and facilitates wound healing. *Autophagy* 2020; 17(9): 2128–2143.
10. Werner S, Krieg T and Smola H. Keratinocyte-fibroblast interactions in wound healing. *J Invest Dermatol* 2007; 127: 998–1008.
11. Eming SA, Wynn TA and Martin P. Inflammation and metabolism in tissue repair and regeneration. *Science* 2017; 356(6342): 1026–1030.
12. Eming SA, Martin P and Tomic-Canic M. Wound repair and regeneration: mechanisms, signaling, and translation. *Sci Transl Med* 2014; 6: 265sr6–265sr6.
13. Xia H, Li X, Gao W, et al. Tissue repair and regeneration with endogenous stem cells. *Nat Rev Mater* 2018; 3: 174–193.
14. Cuttle L, Pearn J, McMillan JR, et al. A review of first aid treatments for burn injuries. *Burns* 2009; 35: 768–775.
15. Fadeyibi IO, Ibrahim NA, Mustafa IA, et al. Practice of first aid in burn related injuries in a developing country. *Burns* 2015; 41: 1322–1332.
16. Ferreira FV and Paula LB. Sulfadiazina de prata versus medicamentos fitoterápicos: estudo comparativo dos efeitos no tratamento de queimaduras. *Rev Bras Queimaduras* 2013; 12: 132–139.
17. Sforcin JM, Fernandes A Jr, Lopes CA, et al. Seasonal effect on Brazilian propolis antibacterial activity. *J Ethnopharmacol* 2000; 73: 243–249.
18. Martinotti S and Ranzato E. Propolis: a new frontier for wound healing? *Burns Trauma* 2015; 3: 9.
19. Tiveron AP, Rosalen PL, Franchin M, et al. Chemical characterization and antioxidant, antimicrobial, and anti-inflammatory activities of South Brazilian Organic Propolis. *PLoS One* 2016; 11: e0165588.
20. Melero AMG, Senna AM, Domingues JA, et al. Hydrogel based on cellulose acetate used as scaffold for cell growth. *Int J Chem Mol Eng* 2018; 12: 352–362.
21. Senna AM, Novack KM and Botaro VR. Synthesis and characterization of hydrogels from cellulose acetate by esterification crosslinking with EDTA dianhydride. *Carbohydr Polym* 2014; 114: 260–268.
22. Nani BD, Sardi JCO, Lazarini JG, et al. Anti-inflammatory and anti-Candida effects of Brazilian organic propolis, a promising source of bioactive molecules and functional food. *J Agric Food Chem* 2020; 68(10): 2861–2871.
23. Walker HL and Mason Ad Jr. A standard animal burn. *J Trauma* 1968; 8: 1049–1051.

24. Dash S, Murthy PN, Nath L, et al. Kinetic modeling on drug release from controlled drug delivery systems. *Acta Pol Pharm* 2010; 67: 217–223.
25. Kini S, Bahadur D and Panda D. Mechanism of anti-cancer activity of benomyl loaded nano- particles in multidrug resistant cancer cells. *J Biomed Nanotechnol* 2015; 11(5): 877–889.
26. Franca JR, De Luca MP, Ribeiro TG, et al. Propolis–based chitosan varnish: drug delivery, controlled release and antimicrobial activity against oral pathogen bacteria. *BMC Complement Altern Med* 2014; 14: 478.
27. Basak SC, Kumar KS and Ramalingam M. Design and release characteristics of sustained release tablet containing metformin HCl. *Braz J Pharm Sci* 2008; 44: 477–483.
28. Mirzoeva OK, Sud'ina GF, Pushkareva MA, et al. [Lipophilic derivatives of caffeic acid as lipoxygenase inhibitors with antioxidant prop- erties]. *Bioorg Khim* 1995; 21: 143–151.
29. Oztürk F, Kurt E, Cerçi M, et al. The effect of propolis extract in experimental chemical cor- neal injury. *Ophthalmic Res* 2000; 32(1): 13–18.
30. Wang Y, Beekman J, Hew J, et al. Burn injury: Challenges and advances in burn wound healing, infection, pain and scarring. *Adv Drug Deliv Rev* 2018; 123: 3–17.
31. Banskota AH, Tezuka Y and Kadota S. Recent progress in pharmacological research of propo- lis. *Phytother Res PTR* 2001; 15(7): 561–571.
32. WUWHS (World Union of Wound Healing Society). <https://www.woundsinternational.com/download/resource/7732> (accessed 29 November 2021).
33. Pahlavani N, Malekahmadi M, Firouzi S, et al. Molecular and cellular mechanisms of the effects of propolis in inflammation, oxidative stress and glycemic control in chronic diseases. *Nutr Metab* 2020; 17: 65.