

ORAL HETERTOTOPIC GASTROINTESTINAL CYST: CASE REPORT

Maike Vinícius Braz de Lacerda

Student of the Dentistry course at Faculdade
Evangélica de Goianésia

Goianésia-Goiás

<http://lattes.cnpq.br/7476091698922949>

Jose Mateus dos Santos Junior

Teacher Specialist in Stomatology, Master
in Oral Pathology, teacher of the Integrated
Clinic Discipline of the Dentistry course at
Faculdade Evangélica de Goianésia.

Goianésia-Goiás

<http://lattes.cnpq.br/6790075740380185>

Maisa France Teixeira

Teacher, PhD of the Dentistry course at
Faculdade Evangélica de Goianésia.

Goianésia-Goiás

<http://lattes.cnpq.br/0188449698292248>

All content in this magazine is
licensed under a Creative Com-
mons Attribution License. Attri-
bution-Non-Commercial-Non-
Derivatives 4.0 International (CC
BY-NC-ND 4.0).



Abstract: The oral heterotopic gastrointestinal cyst (OHCG), also known as enterocystoma, choristomatic cyst or lingual duplication cyst, is characterized as a benign proliferation and differentiation lesion of ectopic cells. The present work aims to report a clinical case of a pediatric patient with enterocystoma. The treatment was carried out through surgical excision under general anesthesia in a hospital environment. Then, the 35mmx15mmx10mm piece was fixed in 10% formaldehyde and sent for histopathological analysis. As a result, a diagnosis of oral heterotopic gastrointestinal cyst was obtained. It is noticed that the treatment of choice presented satisfactory results with the complete removal of the lesion and without a history of recurrence.

Keywords: Oral Pathology. Choristoma. Benign neoplasm.

INTRODUCTION

The oral heterotopic gastrointestinal cyst (OHCG), also known as enterocystoma, choristomatic cyst or lingual duplication cyst, is characterized as a benign proliferation and differentiation lesion of ectopic cells. This rare congenital condition has few literary reports, being diagnosed mainly in neonates and children up to 2 years of age, with no predilection for race and with a prevalence in males (2:1) (GINAT; CARLL; BAROODY, 2019).

Heterotopic gastric mucosa is rarely found in the oral region, being more commonly reported in the duodenum, common bile duct, gallbladder, ileum, appendix, jejunum, Merkel's diverticulum, colon and rectum. In the oral cavity, the most commonly affected sites are the dorsum of the tongue and the floor of the mouth. Other locations that can also be found, but less frequently, are in the region of the larynx, lips, neck and regions close to the submandibular gland (LEE et al., 2020).

Clinically, the lesion appears as an asymptomatic mass, soft or firm on palpation, with a sessile base, covered by tissue with a color and texture similar to mucosa. The differential diagnosis in the oral cavity for this type of lesion usually includes dermoid cyst, thyroglossal duct cyst, lymphatic malformation (lymphangioma) and ranula (SAENZ et al., 2016; ALMEIDA, 2016).

Histologically, this lesion can be variable, including non-keratinized stratified squamous epithelium (gastric) or non-keratinized ciliated columnar epithelium (intestinal), being found in isolation or in association. The isolated form of gastric mucosal epithelium is found in most cases (42%), followed by the intestinal epithelium also in isolation (16%) and the association of the two types of epithelium (10%) (ALMEIDA, 2016).

It is also observed the presence of a thick cystic capsule composed of dense and/or loose tissue, and gastric glands, pancreatic tissue, bundles of smooth muscle tissue, parietal and neuroendocrine cells may be found, often located in the lining areas of the gastric mucosa.

The diagnosis is made through the collection of anamnesis, clinical examination, characteristics of the lesion and histopathology, and imaging tests such as Magnetic Resonance (MRI), Computed Tomography (CT) or Ultrasound may be required in cases of routine prenatal examinations. When the diagnosis of oral heterotopic gastrointestinal cyst is confirmed, the treatment of choice is complete surgical excision, preventing recurrence.

Untreated enterocystoma can cause airway compression, feeding difficulties, dyspnea and dysphagia, consequently leading to growth deficit in neonates. The present work aims to report a clinical case of a pediatric patient with enterocystoma.

CLINICAL CASE

Patient JF, male, 1 year old, malanoderma, attended the Hospital Municipal Dr. Mário Gatti (HMMG), with a small fistula in the submental region, without painful symptoms and without clinical alterations. Through anamnesis and clinical analysis, some diagnostic hypotheses were established, the main ones being: Ranula, Dermoid Cyst, Thyroglossal Duct Cyst, Lymphangioma and Oral Heterotopic Gastrointestinal Cyst.

An excisional biopsy was performed under general anesthesia in a hospital environment (Figure 1), the specimen was fixed in 10% formalin and a soft tissue fragment measuring 35mmx15mmx10mm (Figure 2) was sent for histopathological analysis to the Pathology Laboratory of São Leopoldo Mandic. As a result, a diagnosis of oral heterotopic gastrointestinal cyst was obtained.

In the case report in question, the histological section revealed a cyst lined by stratified squamous epithelium and squamous keratinous debris occupying the space of the cyst (Figure 3). The cyst wall was composed of columnar cells with pale eosinophilic cytoplasm (Figure 4), compatible with gastric mucosal epithelium with intraluminal mucin secretion (Figure 5). Associated with this lining are glands analogous to gastric mucin fossae containing principal and parietal cells, as well as goblet cells consistent with intestinal metaplasia (Figure 5).

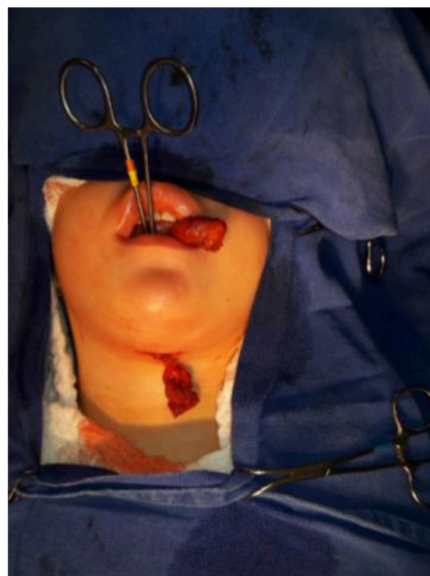


Figure 1: transsurgical
Source: Authors, 2022.

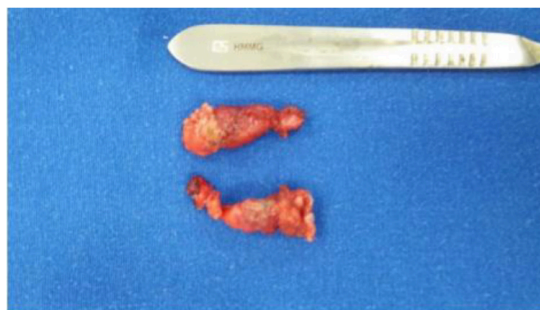

Figure 2: Removed fragment of size 35mmx15mmx10mm.
Source: Authors, 2022.

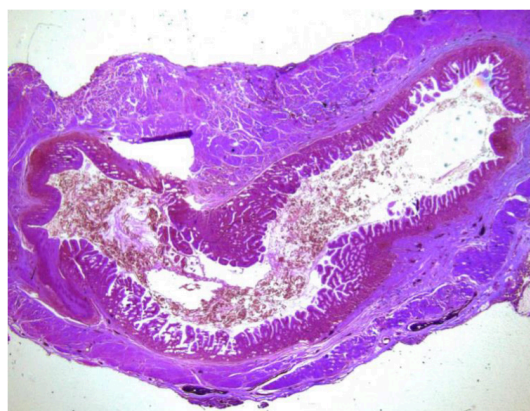


Figure 3: Specimen stained with hematoxylin-eosin showing acyst lined by stratified squamous epithelium and squamous keratinous debris occupying the cyst space.

Source: Authors, 2022

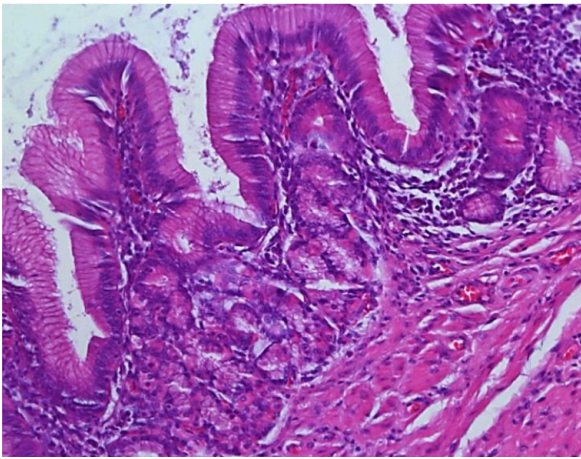


Figure 4: Specimen stained with hematoxylin-eosin showing columnar gastrointestinal epithelium lining the cyst wall.

Source: Authors, 2022.

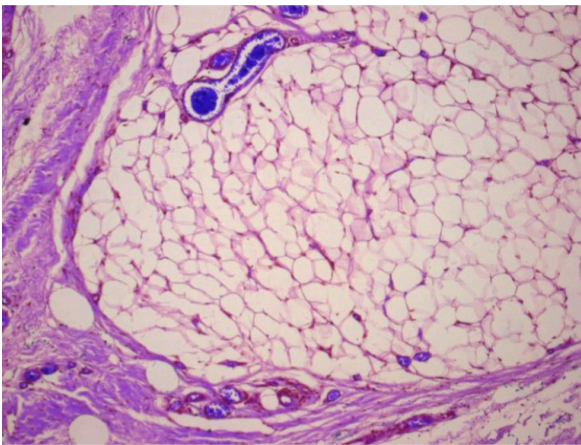


Figure 5: Stained specimen with hematoxylin-eosin highlighting secretion intraluminal mucin within the gastric epithelium.

Source: Authors, 2022.

DISCUSSION

The literature reports that cystic masses are more frequently found in pediatric patients in the head and neck region, the most common being developmental cysts. Regarding the oral heterotopic gastrointestinal cyst, this is characterized as a rare congenital lesion, rarely found in the oral region. Saenz et al. (p.44,2016) reports in his work that currently less than 100 cases have been found in the literature, since this type of injury, in

addition to being considered something rare, has extensive terminology. Consequently, tracking cases and determining data such as incidence and prevalence becomes extremely difficult (SAENZ et al., 2016; ROBINSON; SENGOTSI; VAN, 2021; ALNOUR et al., 2022).

The histopathogenesis of this lesion is still obscure, however some theories are accepted. The first and most accepted concerns the entrapment of gastric tissues during embryonic development around the 4th week of gestation, where the primitive stomach is located in the neck and during the migration of embryonic tissues the fragment of ectodermal tissue can be trapped in the midline region, giving rise to the OHGC. The second theory suggests that its formation is derived from other types of cysts, such as thyroglossal duct and salivary gland retention. In addition to these theories, there are several others, however, even if they have foundations, none can completely determine this etiology (KINIŞ et al., 2014).

Histologically, HOCG can have variable characteristics. Among the various findings, this type of cyst can be found lined by epithelium of the gastric mucosa with the presence of crypts or lined by intestinal epithelium. Furthermore, this lining can be found in isolation or associated with other types of epithelium such as pseudostratified columnar or non-keratinized stratified squamous epithelium. Other features involve the observation or identification of smooth muscle tissue around the cyst, the presence of oxyntic, neural, and endocrine cells, as well as mucin and pancreatic tissue (ALMEIDA, 2016).

Clinically, some lesions may present similar aspects to CGHO. Biopsy and histological evaluation are necessary to confirm this diagnosis. Histologically, even with the presence of mucin, this lesion

cannot be confused with mucocele or ranula, since the gastrointestinal cyst has unique characteristics such as the presence of non-keratinized stratified squamous epithelium or non-keratinized ciliated columnar epithelium, which are tissues normally found in the stomach and intestine (ALMEIDA, 2016).

In addition to histology, imaging tests such as MRI, CT and USG can be used to aid in the diagnosis and surgical decision. However, as this type of cyst mostly affects pediatric patients, their management becomes quite difficult during these tests. Although this type of examination is painless, the unfamiliar environment, the presence of noise and the need to remain still during such a procedure, makes the child's emotional state shaken, making it difficult or impossible to perform it (KINIŞ et al., 2014).

Even with extensive dimensions, patients may or may not have airway compromise, difficulties during mandibular articulation and dysphagia. Regardless of the oral location, the indicated treatment will be surgical excision, and recurrence is reported

only when partial removal of the lesion is performed. The surgeon in charge can make use of both conventional surgical techniques and the use of CO2 laser, which has additional benefits such as greater precision in the incision, better hemostasis, healing and postoperative comfort. The prognosis is mostly good, with no reports of recurrence (ROBINSON; SENGOATSI; VAN, 2021; SIMŞEK-KAYA; OZBUDAK; KADER, 2018; KINIŞ et al., 2014).

CONCLUSION

In the present case report, it can be noted that the treatment of choice proved to be quite effective, resulting in complete removal of the choristoma, good prognosis and no reports of recurrence. According to the literature, it was possible to identify that the treatment recommended and with satisfactory results was surgical excision, while partial removal of the lesion showed a history of recurrence. In addition, because the lesion is rarely found, there are few published works, which makes the study limited.

REFERENCES

Almeida OPD. **ABENO 5 - Patologia Oral**. 1ªed. São Paulo: Piracicaba .2016.

Alnour A, *et al.* **Heterotopic gastrointestinal cyst in the mandible of a young adult: A rare case-report from Syria**. *Annals of Medicine and Surgery*, v. 80, n.1, p. 104296, 2022.

Ginat DT, Carll T, Baroody FM. **Heterotopic gastrointestinal cyst of the oral cavity radiology–pathology correlation**. *Head and Neck Pathology*, v. 13, n. 4, p. 668-670, 2019.

Lee AD, *et al.* **Large lingual heterotopic gastrointestinal cyst in a newborn: A case report**. *World Journal of Clinical Cases*, v. 8, n. 17, p. 3808, 2020.

Robinson L, Sengoatsi T, Van WFP. **Concomitant Congenital Intraoral Dermoid Cyst and Heterotopic Gastrointestinal Cyst**. *Head and Neck Pathology*, v. 15, n. 1, p. 298-302, 2021.

Sáenz MAM, *et al.* **Respiratory distress associated with heterotopic gastrointestinal cysts of the oral cavity: A case report**. *Annals of medicine and surgery*, v. 12, n.1, p. 43-46, 2016.

Simşek-Kaya G, Ozbudak İH, Kader D. **Coexisting sublingual dermoid cyst and heterotopic gastrointestinal cyst: case report**. *Journal of Clinical and Experimental Dentistry*, v. 10, n. 2, p. e196, 2018.

Kiniş V, *et al.* **A rare sublingual cyst in an infant: oral heterotopic gastrointestinal cyst**. *J Pediatr*, v. 56, n.2, p. 212-214, 2014.