

PARTINGTON- ROCHELLE SURGERY: A CASE REPORT

Gustavo Rivelli Lamboglia

Hospital Universitário de Aracaju (HU-UFS)
Aracaju - Sergipe

Rene Pereira da Costa

Hospital Universitário de Aracaju (HU-UFS)
Aracaju - Sergipe

Iago Fernando Alencar Amorim

Hospital Universitário de Aracaju (HU-UFS)
Aracaju - Sergipe

Tiago dos Santos Gutierrez Lazaro

Hospital Universitário de Aracaju (HU-UFS)
Aracaju - Sergipe

Skarlatt Quézia Pires Souza

Hospital Universitário de Aracaju (HU-UFS)
Aracaju - Sergipe

All content in this magazine is licensed under a Creative Commons Attribution License. Attribution-Non-Commercial-Non-Derivatives 4.0 International (CC BY-NC-ND 4.0).



Abstract: Chronic pancreatitis is a progressive inflammatory disorder characterized by the irreversible destruction of the pancreatic parenchyma, which may be associated with disabling chronic pain and permanent loss of endocrine and exocrine function. The management of suspected patients remains a challenge nowadays due to the limited understanding of the pathophysiological process of the disease, the unpredictability of the clinical course in a given individual and the controversies between diagnostic criteria and therapeutic options. The surgical treatment of chronic pancreatitis has undergone a drastic transformation over the last few decades, contributed by the finding that the head of the pancreas was the focus of chronic inflammation and the prospective trials that have repeatedly demonstrated the superiority of treatment over conservative approaches. In the treatment of chronic pancreatitis. Despite the wide availability of medical, endoscopic and surgical procedures, pain management in chronic pancreatitis remains a medical challenge, mainly due to the lack of evidence-based treatment protocols.

Keywords: Pancreatitis; Chronic disease; Pancreas, surgery; Abdomen, Surgery; pancreatojejunostomy.

INTRODUCTION

Chronic pancreatitis is a progressive inflammatory disorder characterized by the irreversible destruction of the pancreatic parenchyma, which may be associated with disabling chronic pain and permanent loss of endocrine and exocrine function. Pain is the most prevalent symptom in chronic pancreatitis, and it is hardly cured with medication. (1)

The management of suspected patients remains a challenge nowadays due to the limited understanding of the pathophysiological process of the disease, the unpredictability of

the clinical course in a given individual and the controversies between diagnostic criteria and therapeutic options. It is estimated that up to 50% of patients develop progressive or clinically intractable symptoms and become, therefore, candidates for surgical treatment, the main surgical indication is intractable abdominal pain (2).

The option for surgical treatment is also indicated in the complications of chronic pancreatitis, such as pseudocysts, pancreatic fistulas, strictures, involvement of adjacent organs or suspected neoplasia. The most performed surgical drainage procedure for the treatment of chronic pain is the Partington-Rochelle surgery, derived from the Puestow and Gillesby technique, whose modification consists of excluding the splenectomy and distal pancreatectomy. It consists of a lateral pancreaticojejunostomy associated with the attachment of a roux-y-jejunal loop longitudinally along the pancreas, providing complete drainage of the ducts of Wirsung and Santorini (1).

CASE REPORT

D.S.N., male, 53 years old, smoker, previously diagnosed with chronic pancreatitis. He was admitted to the Aracaju university hospital due to pain unresponsive to drug treatment, he was admitted to another service for chronic pain management. Patient had daily abdominal pain in the epigastrium since the first episode of pancreatitis, of strong intensity, radiating to the back. He had sporadic nausea without vomiting. During hospitalization in the outpatient service, 6 mg of morphine was used every 4 hours and corticosteroids were administered intravenously, with no improvement in the condition.

On admission to the university hospital in Aracaju, the patient was moaning, with severe pain, sweating, tachycardic (with a

heart rate of 100 bpm), normotensive, on respiratory auscultation without alterations, on the abdominal physical examination, the patient presented in antalgic position, hydroaerial noise present, tense abdomen, painful to palpation throughout the abdomen, both superficial and deep. Opted for patient hospitalization for pain support and nutritional status optimization.

During hospitalization, an abdominal tomography was performed, which showed a heterogeneous, globose pancreas, with multiple sparse foci of calcification. Dilation of the main pancreatic duct is associated (0,8 cm) and secondary ducts, identified up to the cephalic region along with a focus of calcification measuring 0.9 cm, possibly obstructive. Such a finding suggests chronic pancreatitis. Mesenteric and retroperitoneal lymph nodes in the upper abdomen with borderline dimensions, indeterminate. Tumor markers with negative results were also performed, negative serology was performed, laboratory tests that showed no signs of acute chronic pancreatitis. Endoscopy was performed in order to pass a tube after the duodenal papilla, which showed grade I esophageal moniliasis (KODSI). Fornix varices (gov 2) swollen mucosa in the medulla/transition to second portion.

The Partington-Rochelle surgery was performed according to the recommended technique, without interurrences, the patient remained stable throughout the procedure, was referred to the ICU in the postoperative period, the patient remained stable, using a parenteral diet, was discharged on the 2nd PO to ward, starting oral diet on the 4th postoperative day, without abdominal pain. On the 6th postoperative day, he developed a pancreatic fistula guided by the abdominal drains. On the 15th postoperative day, with a very low flow rate in the drainage, gradual traction of the drains began and it was

removed on the 17th postoperative day. Patient remained hospitalized for 18 postoperative days for drain-guided pancreatic fistula control, nutritional support, being discharged on the 18th postoperative day with all organic functions preserved, without analgesia and with adequate pain control for outpatient follow-up.

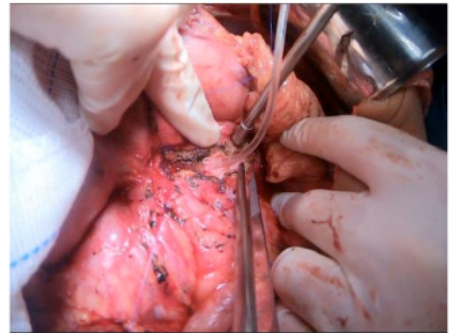


Figure 1 - Wirsung duct with anterior opening to the head of the pancreas, probe with passage to the duodenum and repair threads to start the suture

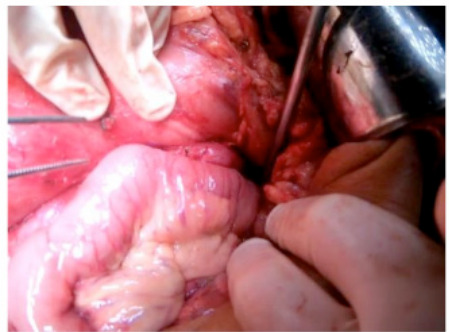


Figure 2- Final appearance of the Partington-Rochelle surgery

DISCUSSION

The surgical treatment of chronic pancreatitis has undergone a drastic transformation over the last few decades, contributed by the finding that the head of the pancreas was the focus of chronic inflammation and the prospective trials that have repeatedly demonstrated the superiority of treatment over conservative approaches.

in the treatment of chronic pancreatitis. The main indication for surgical treatment in chronic pancreatitis is pain that is refractory to medical or endoscopic treatment. In most situations, patients referred for surgical treatment underwent long periods of conservative treatment.(3,4)

Other indications are: suspected neoplasm or complications in adjacent organs, pseudoaneurysm or erosion of large vessels, bulky pancreatic pseudocyst refractory to endoscopic treatment, or pancreatic fistula. The ideal surgical procedure is one that has low morbidity and mortality, is easily reproducible, allows sustained pain control, reducing the need for opioids, does not significantly interfere with endocrine and exocrine function, resolves complications in adjacent organs, and improves the quality of life. patient's life. (two)

Surgical procedures in the treatment of chronic pancreatitis are grouped into 3 categories: drainage, resection and mixed procedures. The choice of surgical technique is based on the type of morphological changes in the pancreas and the involvement of adjacent organs. Recent studies suggest that surgical treatment must not be considered only as a last resort, as it can mitigate disease progression, control pain and preserve pancreatic function when performed at early stages. Longitudinal studies show that with disease progression 40-75% of patients with chronic pancreatitis require surgery.

The Partington-Rochelle procedure is safe, simple and effective, and is associated with a mortality rate of less than 5% and morbidity of less than 1%. Immediate and persistent pain relief was reported in 80% of patients. Endocrine and exocrine functions remain unchanged after longitudinal pancreatojejunostomy, as pancreatic parenchyma resection is practically non-existent. (3,4,5)

CONCLUSION

Despite the wide availability of medical, endoscopic and surgical procedures, pain management in chronic pancreatitis remains a medical challenge, mainly due to the lack of evidence-based treatment protocols. Currently, a conservative approach is being adopted in the early stages of the disease, using non-opioid and opioid analgesics. Eventually, in the final stage of the disease, patients will be referred for surgical treatment, in the absence of improvement of symptoms with prolonged use of analgesics or after multiple endoscopic interventions. (1.5)

The “step-up” approach prevails in most situations, even though several publications show that 40-75% of patients with chronic pancreatitis will need surgery during the course of the disease. Although initially, medical treatment reduces or eliminates, albeit transiently, the symptoms in some patients, it has no impact on disease progression, in addition, long-term treatment with opioids can lead to tolerance, dependence and adverse effects.

The optimal timing for surgery remains a clinically important dilemma and further studies and trials are imperative in order to develop more comprehensive guidelines for the treatment of pancreatitis. Since, even after common complications inherent to the procedure, there was total remission of the use of opioid and non-opioid medications in the case described. (3.4)

REFERENCES

- 1- Frulloni L, Falconi M, Gabbrielli A, Gaia E, Graziani R, Pezzilli R, et al (2010). Italian consensus guidelines for chronic pancreatitis. *Dig Liver Dis*, 42 (Suppl. 6): S381-406.
- 2- Yadav D, Lowenfels A (2013). The epidemiology of pancreatitis and pancreatic cancer. *Gastroenterology*, 144: 1252-1261.
- 3- Jupp J, Fine D, Johnson C (2010). The epidemiology and socioeconomic impact of chronic pancreatitis. *Best Practice & Research Clinical Gastroenterology*, 24: 219-231.
- 4- Muñoz J E (2010). Diagnosis of chronic pancreatitis: functional testing. *Best Practice & Research Clinical Gastroenterology*, 24: 233-241.
- 5- Martínez J, Abad-González A, Aparicio J R, Aparisi L, et al (2013). The Spanish Pancreatic Club recommendations for diagnosis and treatment of chronic pancreatitis: part 1 (diagnosis). *Pancreatology*, 13: 8-17