

MANAGEMENT OF PATIENTS WITH SPECIAL NEEDS FOR THE TREATMENT OF PERICORONARITIS DURING SOCIAL ISOLATION: CASE REPORT

Rodolfo Freitas Dantas

Dental surgeon. Medical Student UNIPE-PB
Professor at Centro Universitário UNIESP-
PB

João Pessoa - Paraíba

<http://lattes.cnpq.br/6892678914894326>

Manoelly Anyelle Pessoa Dias Dantas

Dental Surgeon UNIESP-PB

Bachelor of Laws UNIPÊ-PB

Specialist: Dental radiology and imaging

Specialist pediatric dentistry

Specialist Public Health

João Pessoa - Paraíba

Leonardo dos Santos Dias

Student of Dentistry at Centro Universitário
of João Pessoa UNIPÊ

João Pessoa - Paraíba

<http://lattes.cnpq.br/7112483977495315>

Flaviane Fernandes Fontes

Dental Student at Centro Universitário
UNIESP-PB

João Pessoa - Paraíba

Nathan Carlos de Souza Gonçalves

Dental Student at Centro Universitário
UNIESP-PB

João Pessoa – Paraíba

All content in this magazine is
licensed under a Creative Com-
mons Attribution License. Attri-
bution-Non-Commercial-Non-
Derivatives 4.0 International (CC
BY-NC-ND 4.0).



Dielson Roque da Costa

Dental Student at the UNIESP University
Center

<http://lattes.cnpq.br/6994288759032530>

Ana Carolinne Mesquita Fidelis

Dental Student at Centro Universitário
UNIESP-PB

João Pessoa – Paraíba

Maria Eduarda de Oliveira Silva

Dental Student at Centro Universitário
UNIESP-PB

João Pessoa – Paraíba

Abstract: The approach to systemically compromised patients has several nuances to be observed. Epilepsy is an altered physiological state that involves the central nervous system. Physiologically, an epileptic seizure is a sudden change in central nervous system function, resulting from a high-voltage paroxysmal electrical discharge. The objective of this case report is to discuss the approach to a patient with epilepsy for the treatment of pericoronitis through tooth extraction. of epilepsy, where he sought a private dental clinic complaining of pain in the lower third molar region. It is extremely important to deal with the approach of a patient with special needs.

Keywords: Dentistry. Pericoronitis. Epilepsy. Social isolation.

INTRODUCTION

Epilepsy is the most common serious neurological disease in the world. It is characterized as a brain disorder that can generate epileptic seizures and by the neurobiological, cognitive, psychological and social consequences of this condition. An epileptic seizure is a transient occurrence of signs and/or symptoms due to excessive or synchronous neuronal activity in the brain. Transient episodes of motor, sensory, or psychic dysfunction, with or without loss of consciousness, or convulsive movements may be present (BAUMGARTEM; CANCINO, 2016).

The view of the seizure disorder (epilepsy) is modified by the social and cultural context in which the patient is inserted. Some cultures believe that epilepsy represents “demonic possession”. The fear and ignorance of some people lead to cases of discrimination and feelings of shame for the patient (JACOBY, A.; SNAPE, D.; BAKER, GA 2005).

The anamnesis is the moment to identify fundamental questions regarding epilepsy. It is a vital necessity in the dental treatment of these patients to have security in the performance of the procedures. Just as important is the recognition of the limitations of each patient when the lack of physical and clinical conditions is observed. A minimum requirement would be that the consultation environment remains calm, and stimuli that trigger the crisis should be avoided. Certain stimuli are capable of depolarizing neurons, for example, noises, the light of the reflector and mechanical restraint through fear can trigger crises (BARBÉRIO; SANTOS; MACHADO, 2013).

Periodontal disease begins with gingivitis, but not every case of gingivitis necessarily evolves into periodontitis, given that the evolution of the disease is the result of the accumulation of bacteria present in the gingival margin, in gingivitis the clinical characteristics are the presence of bacterial plaque, bleeding, edema, erythema, increased gingival exudate and sensitivity, which can be reversed through the removal and control of bacterial plaque, which is the cause. In periodontitis, the same picture is present, but loss of conjunctival attachment, periodontal pocket formation and alveolar bone loss are also present. Some factors contribute to the development of periodontitis, such as smoking, heredity, hormonal variation and systemic diseases (ANTONINI et al., 2014).

Pericoronitis is an inflammation of the soft tissue associated with the crown of a partially erupted tooth. It is most commonly seen in relation to the incompletely erupted mandibular third molar, including the gingiva and dental follicle.

According to Bean and King (1971), complications can be more severe and lead to imminent life-threatening situations. It can spread anteriorly or posteriorly down

the facial planes and involve buccal, buccal, submasseteric, submental, submandibular, and pterygoid spaces.

The professional must be prepared to solve the problem of all patients, even with their adversities, even if they are not qualified to perform the necessary procedure in relation to the patient, but they must know and know what the patient needs, making a referral to a trained professional for the case (PALMEIRA et al., 2020).

Clinical treatment of pericoronitis should be chosen according to the intensity of inflammation. Palliative or immediate treatment consists of rubbing the hyperplasia with 0.12% chlorhexidine or 10V hydrogen peroxide for 2 minutes, and in addition, instructing the patient to rinse the mouth with a solution of salt and warm water, rest, and abundant intake of liquid. If the general condition of the patient is affected and/or if there is marked trismus, and more serious local and systemic complications, antibiotics are indicated with subsequent extraction of the dental element (BOSSOI; SOLIS, 2008).

GOALS

Explain, through a case report, the approach of a patient with special needs who presented with pericoronitis during social isolation.

CASE REPORT

A 28-year-old patient sought a private dental clinic complaining of pain in the region of the lower third molars, in the region of the right and left mandibular ramus. Clinical examination revealed severe pericoronitis, with limited mouth opening, mild facial edema, exudate being released to the touch, mucosa with an atypical reddish color and pain to touch.

Soon after, radiographic examination (panoramic) and blood tests (hemogram)

were requested for better planning of the case. An extremely detailed anamnesis was carried out at that first moment, where the allergy to the drug Phenobarbital was observed. The patient claimed to use Epilenil 500 mg, two tablets of daily use, one tablet in the morning and the other at night. Phenobarbital is a barbiturate with anticonvulsant properties, due to its ability to raise the seizure threshold (trade names: Edhanol® Gardenal® Luminal®). With drug interactions with Paracetamol, metronidazole, chloramphenicol, corticosteroids, benzylpenicillin, doxycillin and tetracycline. The patient reported having had seizures for the last time in January 2020, after having had stressful events,

of 750 mg every six hours for two days. The procedure was scheduled for seven days after the initial consultation. To control anxiety and as a way to prevent an eventual seizure by inhibiting the central nervous system, DIAZEPAN 5 mg was prescribed. The patient took a 5mg DIAZEPAN tablet one hour before surgery, upon returning to the clinic, on the day of surgery the patient was submitted to the introduction of O₂, through an oxygen catheter, connected to the portable cylinder, in case there was a need. Local anesthesia was performed with the anesthetic mepivacaine,

In the panoramic radiograph, elements 38 and 48 presented classified as class I according to Pell and Gregory's classification, and in winter's classification it was vertical, in view of this situation, osteotomy was performed and then the Seldin lever and the peyson lever were used to perform the dislocation of the elements, and with With forceps number 23, the teeth were removed, followed by curettage with a surgical curette, abundant irrigation, and simple suture with 4.0 nylon thread.

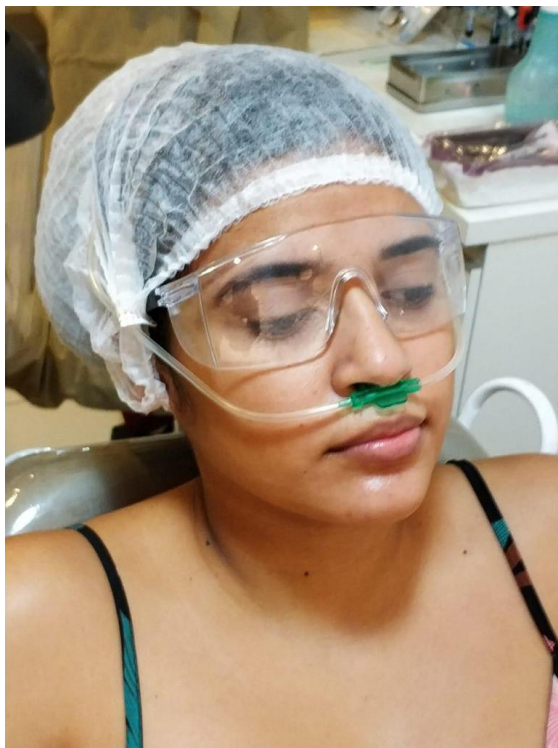

Image 1: Patient monitored under oxygen administration.

Medications were prescribed at the initial consultation to alleviate the inflammatory condition, as well as to relieve pain. For this, amoxicillin of 500mg was prescribed, every eight hours for seven days and paracetamol

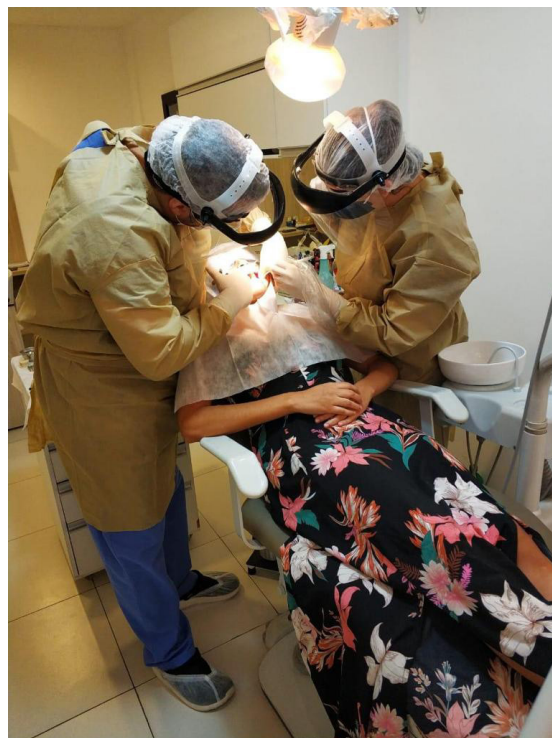

Image 3: trans - operative.

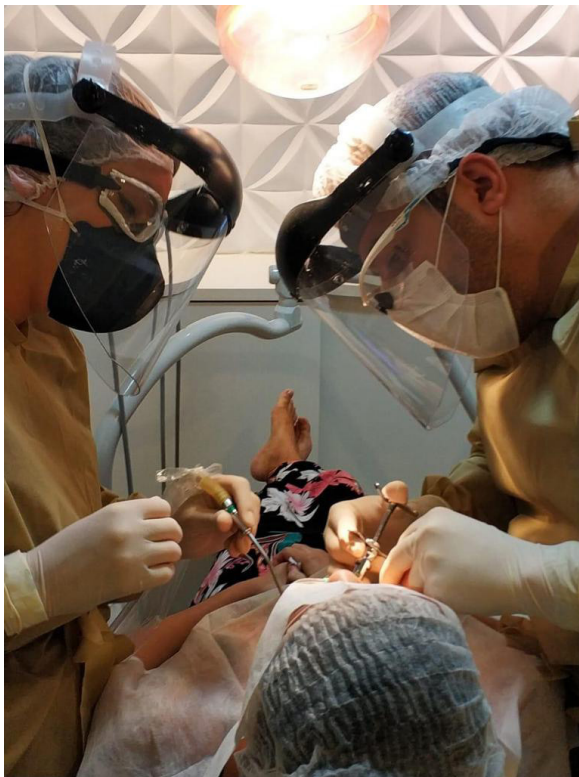


Image 4: Local anesthesia with the anesthetic Mepivacaine, to block the Lower Alveolar Nerve.

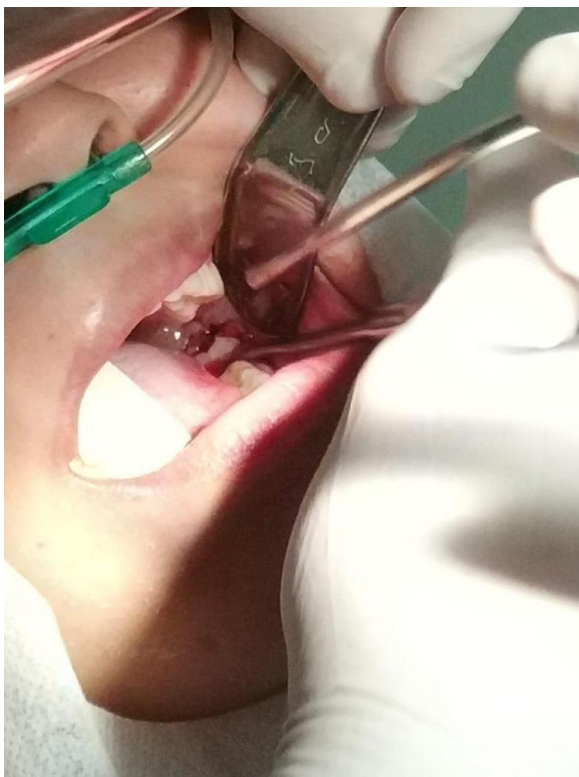

Image 5: trans - operative

The prescribed postoperative medication was dipyrone in case of an episode of pain. And return consultation for stitch removal seven days after the procedure period.

CONCLUSION

The period of social isolation presents itself with several aspects regarding health care. Some psychological conditions lead the individual to a certain disregard for their personal hygiene, especially in this period of social isolation. Pericoronitis requires microorganisms to occur, and hygiene is an extremely important factor for prevention. Currently, the importance of this approach is increasingly strong and firm in the dental class, highlighting the importance of this learning. Patients with epilepsy require some care for care, such as lighting.

REFERENCES

ANTONINI, R. et al. Fisiopatologia da doença periodontal. **Inova Saúde**, v.2, n.2, 2014.

BARBÉRIO, G.S.; SANTOS, P.S.S.; MACHADO, M.A.A. Epilepsia: condutas na prática odontológica. *Rev Odontol Univ Cid São Paulo*. V.25, n.2, p.141-6, 2013.

BAUMGARTEM, A.; CANCINO, C.M.H. Epilepsia e Odontologia: uma revisão da literatura. **Rev. bras. odontol.**, Rio de Janeiro, v. 73, n. 3, p. 231-6, jul./set. 2016.

BEAN, L. R.; KING, D.R. Pericoronitis: its nature and etiology. *Journal of American Dental Association*, v.83, 1971.

DHONGE, R.P. *et al.* An Insight into Pericoronitis. *International Journal of Dental and Medicine Research*, v.1, n.6, p. 172-175, 2015.

JACOBY, A.; SNAPE, D.; BAKER, G.A. Epilepsy and social identity: The stigma of a chronic neurological disorder. **Lancet Neurol**. V.4, N.3, P.171-8, 2005).

LOPEZ TORRES, A. C. et al. Odontologia bajo anestesia general en el paciente con epilepsia: Reporte de caso y revisión de literatura. **Rev. Estomatol. Herediana**, v.30, n.3, p. 207-215, 2020

PALMEIRA, J. T. *et al.* Avaliação do conhecimento de cirurgiões-dentistas sobre emergências médicas: uma revisão da literatura. **Brazilian Journal of Health Review**, v.3, n.4, p. 8555-8567, 2020.

TUNES, U. PERIODONTIA. **Journal of Dentistry & Public Health**, v.5, 2014.