

**ANATOMICAL  
VARIABILITY OF THE  
MYLOHYOID NERVE:  
PILOT STUDY IN 213 DRY  
HUMAN JAWS**

---

*Cleverton Lima de Sá*

<https://orcid.org/0000-0001-5186-3672>

*Carla Jamile Quirino Silva*

<https://orcid.org/0000-0002-6049-0721>

*Maria Nairla Carvalho*

<https://orcid.org/0000-0003-3167-3083>

*Margarite Maria Delmondes Freitas*

<https://orcid.org/0000-0002-9210-1030>

*Isabela de Avelar Brandão Macedo*

<https://orcid.org/0000-0002-6625-016>

*Glauquer Sávio Alves da Silva*

<https://orcid.org/0000-0002-0804-9621>

All content in this magazine is licensed under a Creative Commons Attribution License. Attribution-Non-Commercial-Non-Derivatives 4.0 International (CC BY-NC-ND 4.0).



**Abstract:** The mylohyoid nerve originates superior to the mandibular foramen and follows its course in an inferior-anterior direction to reach the mylohyoid muscle and anterior belly of the digastric muscle. Sensory fibers of this nerve, which correspond to 30% of the total, are spread in the skin of the lower portions of the chin and, eventually, innervate some dental units. The aim of this study is to visually investigate, in 213 dry human mandibles, whether or not there are lingual foramina that indicate anatomic variation of the mylohyoid nerve. Human jaws were analyzed in the human anatomy laboratory at Tiradentes University – UNIT/SE and the results obtained indicate that 76% of them had foramina that suggest the entry of the mylohyoid nerve for innervation of the teeth. The region that most highlighted the foramina index was the premolars on both sides and the sex that most highlighted its presence was male with 61.7%. Regarding the mandibular shape, there is a higher prevalence of foramina in oval-shaped mandibles. In relation to the presence and absence of dentition, the highest rate of this occurred in mandibles with partial edentulism. Thus, we point out the importance of knowing these variations of the mylohyoid nerve, so that the professional can intervene effectively in peri and intraoral surgical procedures.

**Keywords:** Mylohyoid nerve, inferior alveolar nerve, Anatomical variation, Mandibular foramen, Mylohyoid nerve block

## INTRODUCTION

The trigeminal nerve is so named because it has three caliber branches distributed over extensive areas of the face, they are: the ophthalmic, maxillary and mandibular branches (MADEIRA, et al. 1978). The mandibular nerve emits the deep temporal, buccal, lingual, inferior alveolar and mylohyoid nerves, which are located above

the mandibular foramen (MADEIRA, 1995; GRAY, 1988).

The mylohyoid nerve originates on average 14.7 mm before the mandibular foramen (WILSON, et al. 1984). It follows its course in an inferior-anterior direction to the mylohyoid groove, located on the deep surface of the mandibular ramus to innervate the mylohyoid muscle, crossing its superficial surface towards the anterior belly of the digastric muscle, also innervated by it (GRAY, 1988). ; KUMAR, et al. 2011), it spreads in the lower portions of the chin and, eventually, in the teeth (MADEIRA, 1995).

In about 45 to 50% of cases, the mylohyoid nerve branches pass through the small accessory foramina in the lingual region of the teeth, suggesting their innervation (KINI, et al. 2020; MADEIRA, et al. 1978; JEYASELAN, et al, 1984; BENNETT, et al. 2001; GOWGATES, 1973). These foramina can be noticed with the naked eye, have different diameters and distributions (HEASMAN & BEYNON, 1986; CHOI, et al. 2019), and may be responsible for the 38 to 90% failure rate in inferior alveolar nerve block (KINI, 2019). et al. 2020; MALAMED, 1997; STEIN, et al. 2007; Clark, et al. 1999).

The aim of this study is to visually investigate, in 213 dry human mandibles, whether or not there are lingual foramina that indicate anatomic variation of the mylohyoid nerve.

## MATERIALS AND METHODS

### DATA SEARCH

A systematic search was carried out in the virtual databases of PUBMED and BIREME, in Portuguese and English. The search strategies included a combination of the following descriptors searched in the Medical Subject Headings (MeSH): Mylohyoid nerve, variation, muscle mylohyoid, inferior alveolar nerve block and Mylohyoid nerve, foramina,

inferior alveolar nerve block. Researches were carried out, on both platforms, with associations of descriptors and after associations some terms were searched in isolation as shown in **table 1**.

Studies were selected based on the paths, relationships, anomalies, distributions, and clinical implications of the Mylohyoid nerve. Clinically relevant articles, original articles, literature review articles, case reports in fresh cadavers and in dry jaws were included. The excluded publications did not relate to the Mylohyoid nerve and its communications, did not present images of the path, distribution and intramandibular insertion or exposed inaccurate imaging tests. Articles that discussed only the inferior alveolar nerve and its block technique, that discussed animal studies, atlases or congress abstracts were also excluded. (**Flowchart 1**).

## STUDY IN DRY JAWS

The sample of this study is composed of 213 dried mandibles of adult humans, from the ossuary of the laboratory of human anatomy and forensic anthropology at Tiradentes University - UNIT-SE. Sample selection was based on inclusion and exclusion criteria. Inclusion criteria: intact mandibles with or without lingual foramina. Exclusion criteria: mandibles with congenital, pathological or traumatic anatomical alterations in the region to be studied (lingual face). The amount susceptible to the study was 213 dry mandibles belonging to individuals cataloged by the forensic anthropology service of the Tiradentes University - UNIT/SE, from the State of Bahia.

For the study and collection of the number of foramina in the pieces, a data collection form for the foramina in dry human mandibles was prepared (**Appendix I**). Through the investigative analysis of the forensic records of each mandible, initially, they were first

separated by sex and age of each. Continuously, the classification was followed as to the shape (Oval, square or triangular) and then if there is presence or absence of teeth (Total edentulous, partially edentulous or totally dentate). Finally, visual confirmation and foramina counting were performed by region: Anterior Region (lingual region of the lower incisors and canines), Middle Region (lingual region between the lower premolars) and Posterior Region (lingual region of molars).

## DATA ANALYSIS

The data collected from the topographic analysis of the mandibles were tabulated to generate graphs, enabling a better visualization of the results. The data were compared with each other, observing 4 associations: Presence of lingual foramina in the male and female mandibles; presence of tongue foramin in the 3 types of mandibular shapes (oval, square and triangular); presence of lingual foramina in dentate, edentulous or partially dentate mandibles and presence of foramina by region.

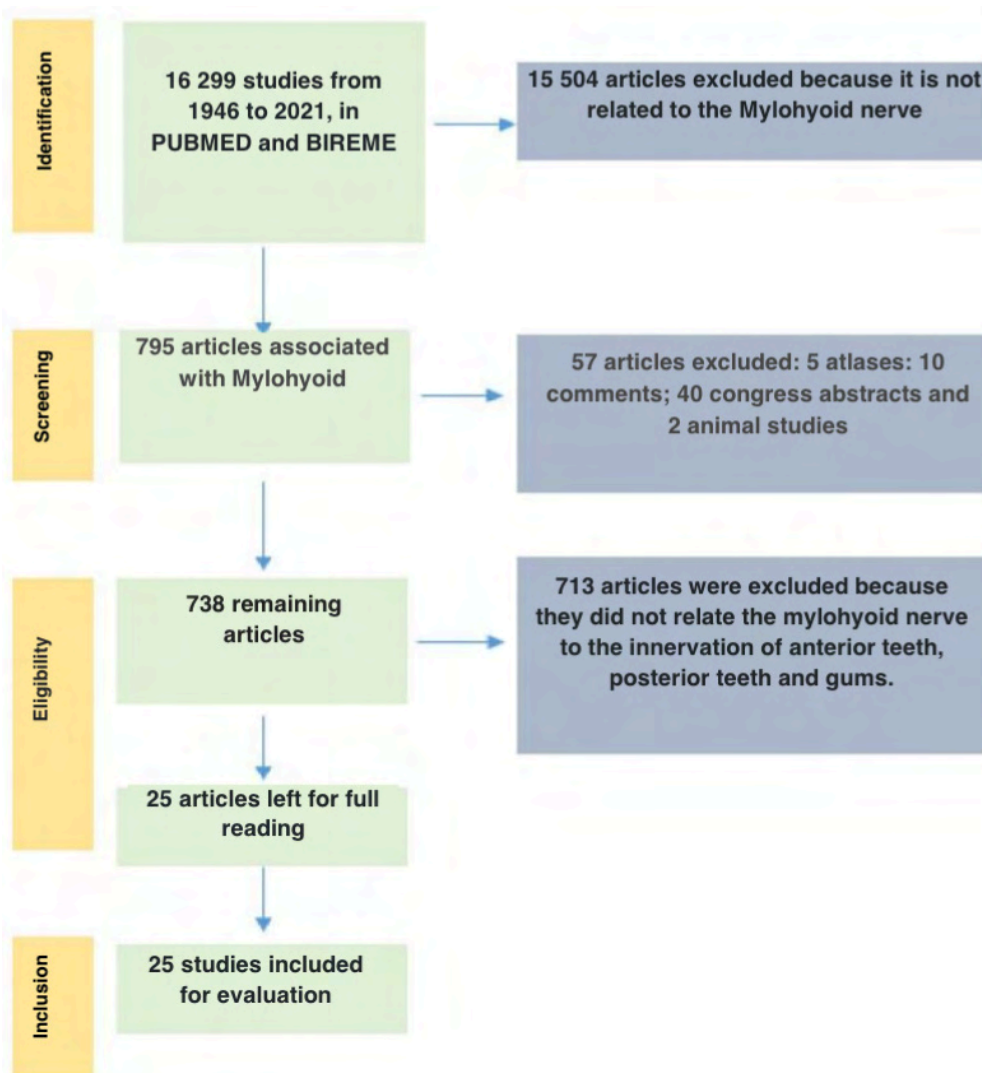
## RESULTS

The mandibles were analyzed, following each variant, observing the presence or absence of foramina in the lingual region. In **graph 1**, one can observe the prevalence in relation to sex and association with morphological findings. About 76% of the total had at least one foramina in the lingual region and, despite not being found in the literature, the association of the presence of foramina with males was relatively higher with 61.7% compared to females 38.3%.

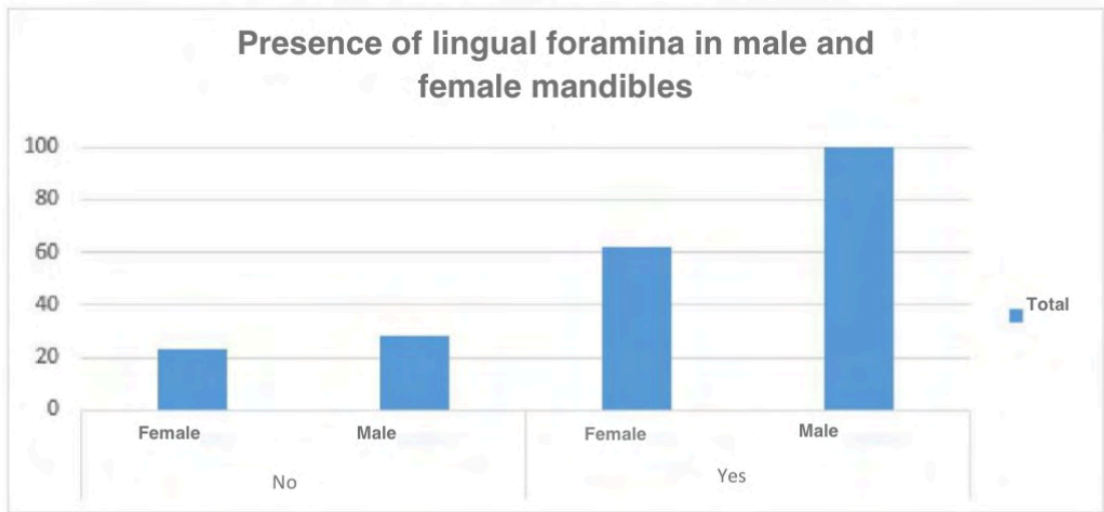
Another aspect studied in the pieces was the shape of the mandible and the results were compared with sex and the presence or absence of foramina, as illustrated in Graph 2. These associations were not found in the literature for discussion, however, the ovoid shape presented a greater number of foramina

DESCRIPTORS	RESEARCH IN PUBMED	RESEARCH IN BIREME
Mylohyoid nerve	8,364	5.996
Mylohyoid nerve and variation	391	224
Mylohyoid nerve and muscle mylohyoid and nerve block	10	90
Mylohyoid nerve and foramina	138	137
Inferior alveolar nerve block and Mylohyoid nerve	1348	949
Inferior alveolar nerve block	1511	1288
TOTAL	<b>8.903</b>	<b>7.396</b>

Table 1: Presentation of searched terms and the number of publications found in both databases.

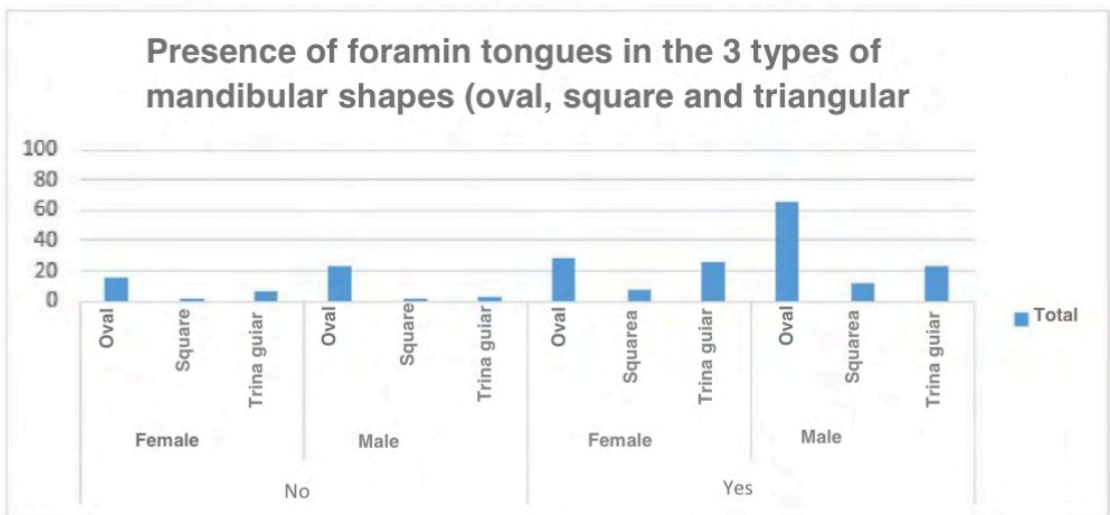


Flowchart 1: Flow for selecting studies according to the criteria.



Graph 1: Representation of the prevalence between the sexes and if there were at least one foramina in the lingual region of the mandible.

Source: Authors.



Graph 2: Representation of associations between topographical aspects and sex.

Source: Authors

about 57.4% and these in male mandibles.

Another association observed was the significantly lower index of this nerve in totally edentulous and fully dentate mandibles compared to mandibles of partially edentulous individuals. The results showed, in relation to dentition, a prevalence of foramina in partially edentulous with 56.7%, followed by total edentulous 23.4% and fully dentate 19.7%. The fully dentate mandibles may have presented a lower number of foramina because they are in smaller number in the sample - 20.1% (**Graph 3**).

The **graph 4** presents the association that refers to the prevalence of the region where foramina were found, being divided into three zones: Anterior (incisors and canines region); Middle (Premolar region) and posterior (Region and molars) on both sides.

## DISCUSSION

The mylohyoid nerve is related to the inferior (extraoral) face of the mylohyoid muscle, which extends to the tip of the submandibular fossa and inferiorly to the mylohyoid line, maintaining a relationship with the submandibular gland (FIGÚN, et al. 2003). The diameter of the nerve fibers and the presence of the myelin sheath are important measures to characterize the functional aspect, determining the speed of conduction of the action potential (GUYTON, 1969). Sensory fibers of this nerve, which correspond to 30% of the total, are spread in the skin of the lower portions of the chin and, eventually, in the teeth (MADEIRA, 1995).

The incidence between 61.4 and 76.9% of accessory foramina in the region indicates possible innervation in the lower dentition (Madeira et al., 1978), similar to the present study, which found an incidence of 76%.

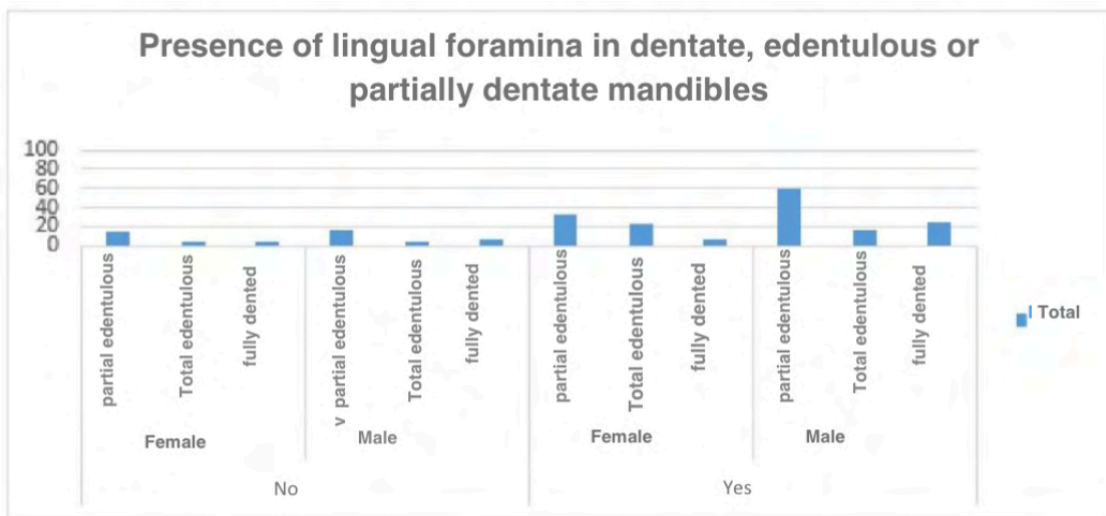
Studies point to the innervation of 20% of the anterior dental units by this nerve, after penetrating the mandible by

foramina, which have different diameters and distributions, moving towards the dental apices (FROMMER, et al. 1972; WILSON, et al. 1984). In our study, in the anterior region there was presence of foramin in 40.1% (**figure 1.A** and **figure 1.B**).

Some authors have reported that in about 45 to 50% of cases, the terminal branches of the mylohyoid nerve pass through the small accessory foramina near the mental symphysis, anterior to the mylohyoid line (KINI, et al. 2020; MADEIRA, et al. 1978; JEYASELAN, et al. 1984; BENNETT, et al. 2001). In our research, although in agreement with the presence of foramin in the region, the number was relatively lower with 15.9% of our samples (**figure 1.C**). Intraosseous dissections of the mylohyoid nerve have shown that these foramina give passages to branches that reach the incisor teeth directly (ROOD, et al. 1977b).

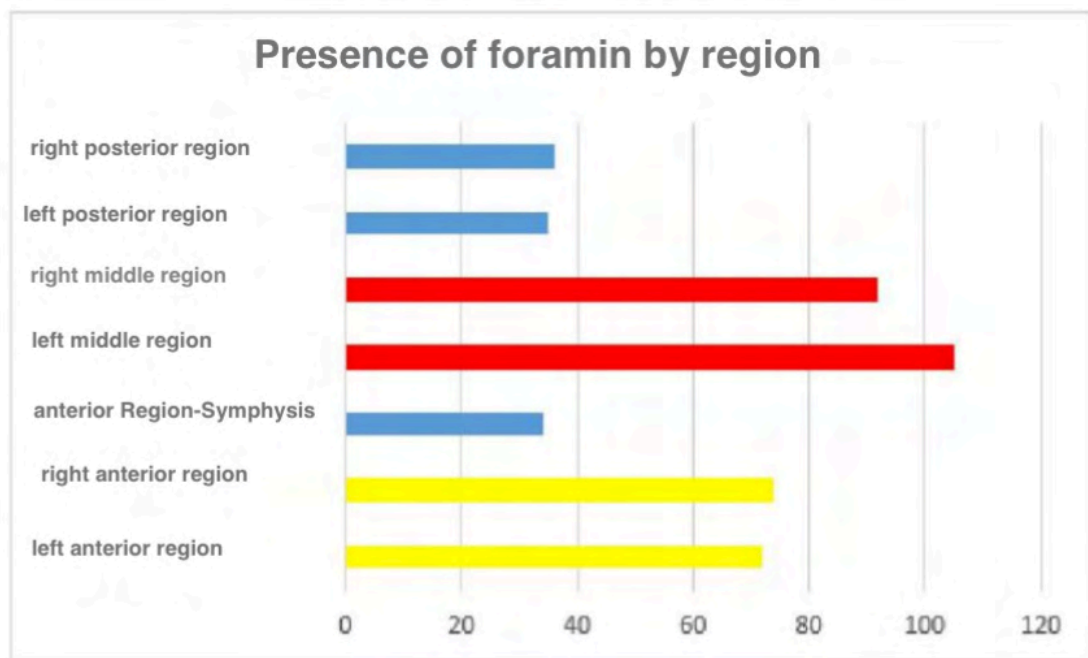
An inferior retromental foramen has also been described as occurring in a similar location, on the inferior border of the mandible, with an incidence between 87.3 and 96.2% (MADEIRA et al., 1978). From a larger perspective, 43% to 50% of the population, the terminal branches of the mylohyoid nerve penetrate the lingual aspect of the mandible through the lingual foramen, premolar region, or retro mentalis, to innervate the incisors or premolars. and related gums (CLARK, et al. 1999; He, et al. 2017; BENNETT, et al. 2001) (**figure 1.D** e **figure 1.E**).

Innervating the premolars, canines and incisors there is an incidence of approximately 60% (BLANTON & JESKE, 2003). Haveman & Tebo (1976) examined 150 dried skulls and found that the foramina occurred most frequently on the medial surface of the mandible, with 53.5% of the foramina occurring within or very close to the mylohyoid sulcus (Haveman & Tebo, 1976). Another study of 300 dried skulls also showed similar results (SILLANPAA, et al. 1974).



Graph 3: Data on partial edentulism, total edentulism and totally dentate in relation to the lingual foramina.

Source: Authors.



Graph 4: Illustration of mandible regions and foramina distribution. Higher prevalence in the middle region, on both sides (Horizontal bars in red). The second most prevalent region was the previous one (in yellow).

Source: Authors

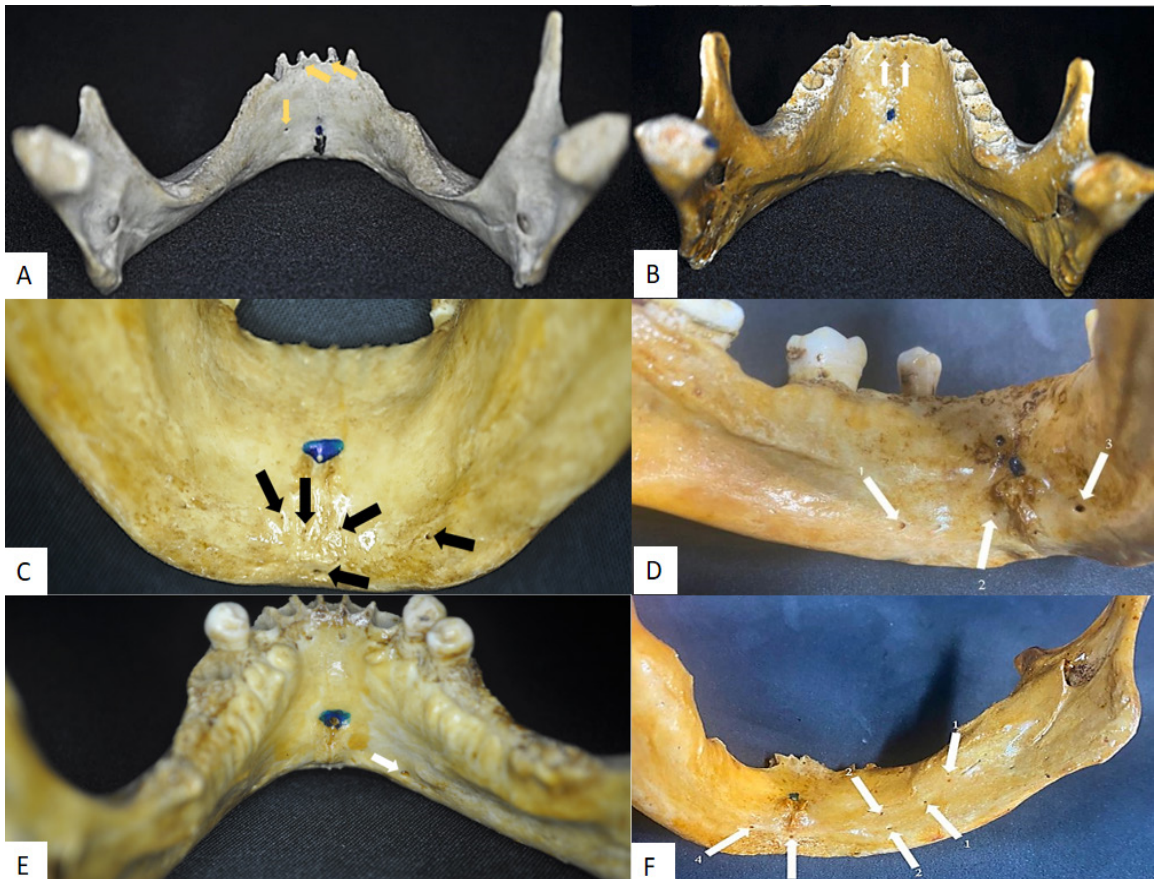


Figure 1: A — Anterior region: Foramina indicated by the yellow arrows in the region closer to the cervical and mid-basal region. B — Foramina indicated by white arrows, anterior region, close to the cervical region. C — Retromental foramina, indicated by the arrows, demonstrating the entry of the mylohyoid nerve to the apex of the dental units in the anterior region. D - Anterior foramen, arrows 2 and 3, and foramina in the middle region, arrow 1. E —Foramina in the middle region, white arrow. F - Foramina of the Posterior Region (1), Foramina of the Middle Region (2), Foramina of the Mandibular Symphysis Region (3) and Foramina of the Anterior Region (4).

Source: Authors.



We found a greater number of foramina in the middle region of the mandible, in agreement with these authors, however, with a discrepant frequency of 43.9%. Chapnick (1980) reported from his observations on 122 mandibles that a small foramen lingual to the premolars occurred near the lower border of the mandible in 68.9% of the specimens; He suggested that the foramen may be related to the mylohyoid nerve or the transverse cervical nerve of the cervical plexus (CHAPNICK, 1980b).

It is suggested that these foramina on the medial surface of the last molar can transmit the branch of the mylohyoid nerve, being able to supply sensory fibers to the last molar (ALTUG, 2012; JEYASELAN, et al. 1984), also found in our analyses, 15.8%, as illustrated in figure 1.F.

Interestingly, in edentulous mandibles, the number of these foramina through which this nerve follows its course is significantly lower than in dentate individuals (HEASMAN & BEYNON, 1986), which differs from our results: higher prevalence of partially edentulous 56.7%, edentulous 23.4% and fully dentate 19.7%. The data indicate that the average number of foramina per mandible is 36 (HAVEMAN & TEBO, 1976; STEIN, et al. 2007). With these accessory innervations there may be failures in analgesia and adverse effects.

The most common causes of incomplete inferior alveolar block are: Anesthetic deposits below the mandibular foramen, anesthetic deposits too anteriorly (laterally) in the ramus of the mandible and accessory innervation to the mandibular teeth, presenting painful symptoms during the procedure and increased anxiety and phobias. (MALAMED, et al. 2013). The presence of pain in the procedure, caused by the incorrect nerve block, serves as an emotional trigger for the imbalance of these states, which impair clinical dental

management (DE ANDRADE, et al. 2014; APPUKUTTAN, et al. 2016).

Knowledge of such anatomical variations, of embryological origin, can help during surgical or dental interventions (MADEIRA et al., 1978; KUMAR, et al. 2011; CHOI, et al. 2019; KINI, et al. 2020). The knowledge of this variability is important, mainly, for the success of procedures that require a correct block of the hemi-arch, which presents a rate of 38 to 90% of failure (KINI, et al. 2020; MALAMED, 1997; STEIN, et al. 2007; CLARK, et al. 1999; AKINOSI, 1977; GOW-GATES, 1973). For this, anesthetic infiltration of the mylohyoid nerve is necessary after the inferior alveolar nerve block (MADEIRA, et al. 1978).

## CONCLUSION

About 76% of the sample presented foramina on the lingual aspect of the mandible, suggesting the innervation of the dental units by the mylohyoid nerve, according to the literature. The middle, right and left regions showed a greater distribution of these foramina, 43.9%, followed by the anterior region with 40.1% and the posterior region with 15.8%.

Regarding the prevalence of foramina in relation to sex, there was a greater presence of these in male mandibles 61.7% (regardless of shape and presence or absence of dentition), followed by 38.3% in female mandibles.

As for the presence of foramina and its relation to the mandibular shape, it was observed that there is a higher percentage in the oval shape with 57.4%, followed by the triangular shape 30.2% and the square shape 12.3%.

Regarding dentition, the prevalence was of partially edentulous with 56.7%, total edentulous 23.4% and totally dentate 19.7%, which is justified by the small amount of fully dentate jaws present in the ossuary - 20.1% of the total studied.

Thus, it is remarkable how the anatomical variation of the mylohyoid nerve can directly interfere in the success of the inferior alveolar nerve block and the knowledge of such variations needs to be understood so

that the health professional can intervene effectively in the applicability of the anesthetic technique, resulting in flawless analgesia, as these can impact the success of the procedure.

## REFERENCES

- AKINOSI, J.O. **Uma nova abordagem para o bloqueio do nervo mandibular.** Br J Oral Surg v. 15, p. 83–87, 1977.
- ALTUG, H. A. **The efficacy of mylohyoid nerve anesthesia in dental implant placement at the edentulous posterior mandibular ridge.** Journal of Oral Implantology, v. 38, n. 2, p. 141-147, 2012.
- APPUKUTTAN, D. P. **Strategies to manage patients with dental anxiety and dental phobia: literature review.** Clinical, cosmetic and investigational dentistry, v. 8, p. 35, 2016.
- BENNETT, S.; TOWNSEND, G. **Distribution of the mylohyoid nerve: anatomical variability and clinical implications.** Australian Endodontic Journal, v. 27, n. 3, p. 109-111, 2001.
- BLANTON, P. L, JESKE, A.H. **A chave para a anestesia local profunda.** J Am Dent Assoc v. 134, p. 753–760, 2003.
- CHAPNICK L. **Suprimento nervoso para a dentição mandibular: A Reveja.** J Can Dent Assoc v. 46, p. 446–448, 1980a.
- CHAPNICK L. **Um forame na língua da mandíbula.** J Can Dent Assoc v. 46, p. 444–445, 1980b.
- CHOI, P.; IWANAGA, J.; DUPONT, G.; OSKOUIAN, R. J.; & TUBBS, R. S. **Clinical anatomy of the nerve to the mylohyoid.** Anatomy & cell biology. v. 52, n. 1, p. 12-16, 2019.
- CLARK, S.; READER, A.; BECK, M.; & MEYERS; W. J. **Anesthetic efficacy of the mylohyoid nerve block and combination inferior alveolar nerve block/mylohyoid nerve block.** Oral Surgery, Oral Medicine, Oral Pathology, Oral Radiology, and Endodontology. v. 8, n. 5, p. 557-563, 1999.
- DE ANDRADE, E. D. **Terapêutica medicamentosa em odontologia.** Artes Médicas Editora, 2014.
- FIGÚN, M. E.; GARINO, R. R. **Anatomia odontológica: funcional e aplicada.** p. 532-532, 2003.
- FROMMER, J.; MELE, F. A.; MONROE, C. W. **The possible role of the mylohyoid nerve in mandibular posterior tooth sensation.** The Journal of the American Dental Association, v. 85, n. 1, p. 113-117, 1972.
- GOW-GATES, G. A. **Anestesia por condução mandibular: Uma nova técnica usando marcos extraorais.** Oral Surg Oral Med Oral Pathol. v. 36, p. 321–328, 1973.
- GRAY, H. **Gray's anatomia: a base anatômica da prática clínica.** 29 ed. Rio de Janeiro: Guanabara Koogan S. A., 1988
- GUYTON, A. C.; PI, A. F. Y. **Fisiologia humana.** Interamericana, 1969.
- HAVEMAN, C.W.; TEBO, H.G. **Forame acessório posterior da mandíbula humana.** J Prosthet Dent v. 35, p. 462–468, 1976.
- HE, P.; TRUONG, M. K.; ADEEB, N.; TUBBS, R. S.; IWANAGA, J. **Anatomia clínica e significado cirúrgico do forame lingual e seus canais.** Clin Anat. v. 30, p. 194-204, 2017.
- HEASMAN, P.A.; BEYNON, A.D. **O papel do nervo milo-hióideo em inervação do dente mandibular.** J Dent. v. 14, p. 80–81, 1986.
- JAYASEELAN, N.; SHARMA, J. K. **Morphological study of unnamed foramina in north Indian human mandibles and its possible role in neurovascular transmission.** International Journal of oral Surgery, v. 13, n. 3, p. 239-242, 1984.

KINI, S., SOMAYAJI, K., ACHARYA, S., & SAMPATH, S. **Anomalies and clinical significance of mylohyoid nerve: A review.** Clinical, Cosmetic and Investigational Dentistry, v. 12, p. 429, 2020.

KUMAR, S.; KUMAR, C. J.; BHAT, S.; & KUMAR, A. **Anatomical study of the unusual origin of a nerve to the mylohyoid muscle and its clinical relevance.** British Journal of Oral and Maxillofacial Surgery, v. 49, n. 5, p. e14-e15, 2011.

MADEIRA, M. C. **Anatomia da face: bases anátomo-funcionais para a prática odontológica.** São Paulo; Sarvier, p. 174-174, 1995.

MADEIRA, M. C.; PERCINOTO, C.; MARIA DAS GRAÇAS, M. S. **Clinical significance of supplementary innervation of the lower incisor teeth: a dissection study of the mylohyoid nerve.** Oral Surgery, Oral Medicine, Oral Pathology, v. 46, n. 5, p. 608-614, 1978.

MALAMED, D. S. F. **EMERGENCY MEDICINE: Beyond the basics.** The Journal of the American Dental Association v. 128, n. 7, p. 843-854, 1997.

ROOD, J.P. **Algumas causas anatômicas e fisiológicas de falha para obter analgesia mandibular.** Ir. J Oral Surg, v. 15, p. 75-82, 1977b.

SILLANPAA, M; VUORI V, LEHTINEN R. **O nervo milo-hióideo e anestesia mandibular.** Int J Oral Maxillofac Surg v. 17, p. 206-207, 1974.

STEIN, P.; BRUECKNER, J.; MILLINER, M. **Sensory innervation of mandibular teeth by the nerve to the mylohyoid: implications in local anesthesia.** Clinical Anatomy: The Official Journal of the American Association of Clinical Anatomists and the British Association of Clinical Anatomists, v. 20, n. 6, p. 591-595, 2007.

WILSON, S.; JOHNS, P.; FULLER, P. M. **The inferior alveolar and mylohyoid nerves: an anatomic study and relationship to local anesthesia of the anterior mandibular teeth.** Journal of the American Dental Association, v. 108, n. 3, p. 350-352, 1984.

## I) ANNEX - 1 - FORM FOR DATA COLLECTION IN DRY HUMAN JAWS

1. Mandibular shape

Oval ( )

Square ( )

Triangular ( )

2. Dentition

All dental units present ( )

Partial edentulous ( )

Total Edentulous ( )

3. Does the part have any damage (pathology or trauma)?

Yes ( )

No ( )

4. Are there lingual foramina present?

Yes ( )

No ( )

If yes, follow the questions ahead.

5. How many foramina in the anterior region

0 ( )

1 ( )

2 ( )

3 ( )

4 ( )

Or over\_\_\_\_\_

6. How many foramina in the right middle region (premolars)

0 ( )

1 ( )

2 ( )

3 ( )

4 ( )

Or over\_\_\_\_\_

7. How many foramina in the left middle region (premolars)

0 ( )

1 ( )

2 ( )

3 ( )

4 ( )

Or over\_\_\_\_\_

8. How many foramina in the right posterior region (molar region)

0 ( )

1 ( )

2 ( )

3 ( )

4 ( )

Or over \_\_\_\_\_

9. How many foramina in the right posterior region (molar region)

0 ( )

1 ( )

2 ( )

3 ( )

4 ( )

Or over \_\_\_\_\_