

CASE REPORT: PAPILLARY CARCINOMA IN THE MALE BREAST

Thaís Rafael Almeida Sanches

Resident physician in Radiology and Diagnostic Imaging at the Foundation Center for Oncology Control of the State of Amazonas (FCECON)

Manaus – AM

<http://lattes.cnpq.br/8057848913023143>

Sabrina Ramos Bianco

Radiologist at the Foundation Center for Oncology Control of the State of Amazonas (FCECON)

Manaus – AM

<http://lattes.cnpq.br/5315165876704149>

Euler Martins Marques

Mastologist at the Foundation Center for Oncology Control of the State of Amazonas (FCECON)

Manaus – AM

<http://lattes.cnpq.br/3227088143888965>

Abraham Felipe Luna de Oliveira

Resident physician in Radiology and Diagnostic Imaging at the Foundation Center for Oncology Control of the State of Amazonas (FCECON)

Manaus – AM

<http://lattes.cnpq.br/1848818732686039>

Thyago Araújo Ale

Resident physician in Radiology and Diagnostic Imaging at the Foundation Center for Oncology Control of the State of Amazonas (FCECON)

Manaus – AM

<http://lattes.cnpq.br/0886518395790625>

All content in this magazine is licensed under a Creative Commons Attribution License. Attribution-Non-Commercial-Non-Derivatives 4.0 International (CC BY-NC-ND 4.0).



Walder Vieira Neto

Resident physician in Radiology and
Diagnostic Imaging at the Foundation
Center for Oncology Control of the State of
Amazonas (FCECON)
Manaus – AM
<http://lattes.cnpq.br/5453773940195978>

Abstract: Background: Breast cancer in men is rare (1%) and the papillary carcinoma subtype represents 2-3% of these cases. In general, therapeutic management is based on surgery and may be associated with other adjuvant treatments. However, the therapy is still debatable, as there are few studies on this type of injury, especially in the male population. **Aims:** In this study, we report a case of Papillary Breast Cancer in male breast, in an oncology health unit in the city of Manaus/AM (Brazil). **Methods:** The sample consisted of a male patient who underwent medical treatment at the Amazonas Oncology Control Center Foundation, aged 50-70 years, with breast cancer, papillary pattern. **Conclusion:** There is still little information described in the medical literature about this entity, with regard to diagnostic and therapeutic aspects. Therefore, it is necessary to carry out further studies in this area to assist in medical management and patient prognosis.

Keywords: Male breast, Male breast cancer, Papillary Carcinoma.

INTRODUCTION

Male breast cancer is a rare pathology, of unknown etiology, but it is known that hormonal, environmental and genetic factors are related to its emergence. Because it is uncommon, there are few descriptions on the topic in the medical literature. It is known that some factors are involved in the pathogenesis of breast cancer in men, such as the hormonal, environmental and genetic factors.

In general, the diagnosis of male breast cancer occurs at later stages, compromising the prognosis when compared to female breast cancer. Among the types of male breast cancer, those with papillary and cribriform patterns are the most common. For the description of a case report on this subject, it is important to approach from the epidemiological aspects,

the history of the current disease, correlating with personal and family history, to the description of mammographic, ultrasound, histopathological and immunohistochemical findings.

The work was carried out in a health unit whose care is specialized in cancer patients in the city of Manaus/Amazonas (Brazil).

The present study aims to report a case on Papillary Breast Cancer in the male breast, with the aim of increasing the medical literature, in order to facilitate the identification of signs and symptoms of possible risk groups for the development of breast cancer. masculine.

CASE REPORT

Male, 59 years old, Caucasian, evolved with a small nodular, palpable, retroareolar lesion of the right breast 01 year ago. After 06 months of evolution, the lesion increased in volume and its consistency became hardened. The patient reported that, on some occasions, the lesion presented local heat and pain. On physical examination, he presented a hardened nodule in the retroareolar region, mobile, painless, without papillary discharge, measuring approximately 7 cm, without skin thickening or retraction, without palpable axillary lymph node. He denies trauma, surgical treatment, use of hormones, smoking or alcohol consumption. He has a BMI of 29.8 kg/m² (overweight), with Systemic Arterial Hypertension using Captopril, Losartan and Hydrochlorothiazide. He denies previous chest irradiation. She denies a family history of breast cancer or its risk factors.

(Figure 1).

A fine needle puncture biopsy (FNA) was performed, which showed a cytological picture with cystic content, with the presence of degenerated macrophages, absence of atypia, isolated cell arrangement, with a protein background.

(Figure 2).

Mammography shows Right Breast with adipose tissue showing a retroareolar nodule, measuring 5.9 cm, oval in shape, circumscribed margin, without microcalcifications and without visualization of axillary lymph nodes, BI-RADS 6.

(Figure 3).

As for ultrasonography, the lesion appears as a retroareolar nodule, oval in shape, with a circumscribed margin, mixed pattern, predominantly cystic, with thick content, with vegetating projections, measuring 5.5 x 4.3 cm. The solid projections are isoechoic, parietal, irregular, the largest measuring 1.5 cm, present central and peripheral flow on color Doppler. It also has a typical intramammary lymph node at the junction of the lateral quadrants, measuring 0.7 x 0.5 cm, BI-RADS 4B.

(Figure 4).

In the anatomopathological study, it appears as an epithelial proliferative lesion with a papillary pattern with discrete cellular monotony. In the immunohistochemistry (IHC), mammary carcinoma was found, with areas of papillary pattern, positive for estrogen receptors, positive for progesterone receptors and score 1+ (negative) for HER2. As commented by the IHC, it appears as an epithelial proliferative lesion with areas of a papillary pattern, intensely fragmented, with mild nuclear atypia, showing absence of CK14 expression and strong and diffuse expression of estrogen receptors. The absence of myoepithelial cells was evidenced by the negativity for p63 and calponin expression.

(Figure 5).

Right breast mastectomy was performed with axillary dissection for lesion resection. Anatomopathological sections of the surgical specimen, parallel and successive, showed a wide cystic cavitation with fluid content of hemorrhagic aspect, measuring 5.5 x 4.5 cm, 4.0 cm from the lateral margin and 3.0 cm from the medial, 1.0 cm from the deep

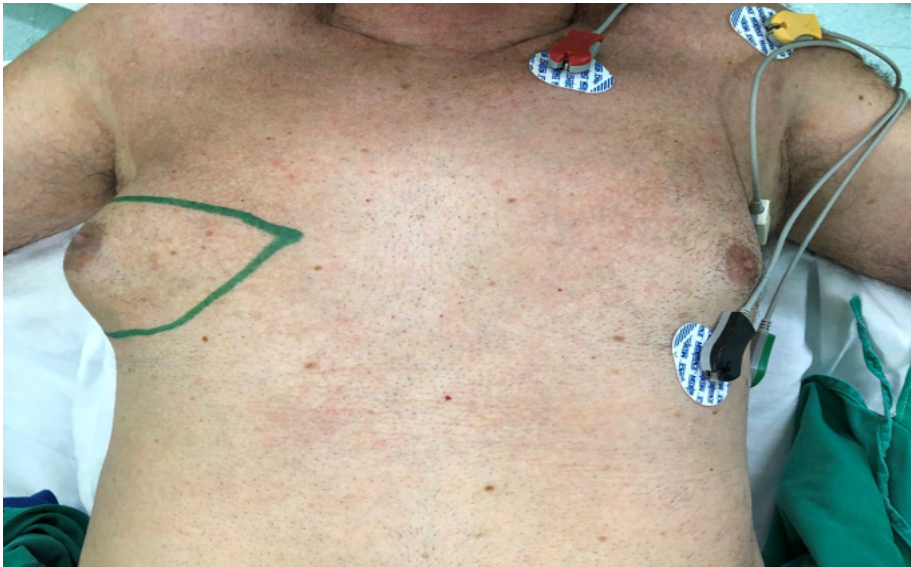

Figure 1: Physical examination: pre-surgical marking on the right breast. A voluminous right breast can be observed without nipple retraction compared to the contralateral breast.

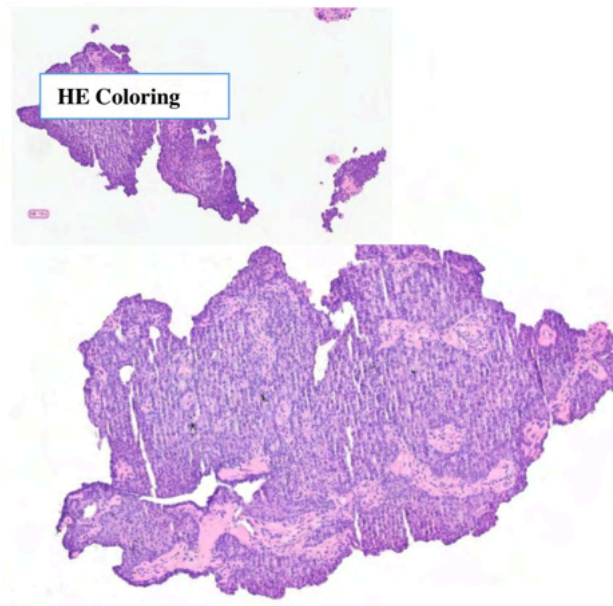


Figure 2: Fine needle aspiration puncture (FNA) blade: Papillary-patterned proliferative epithelial lesion with discrete cellular monotony.

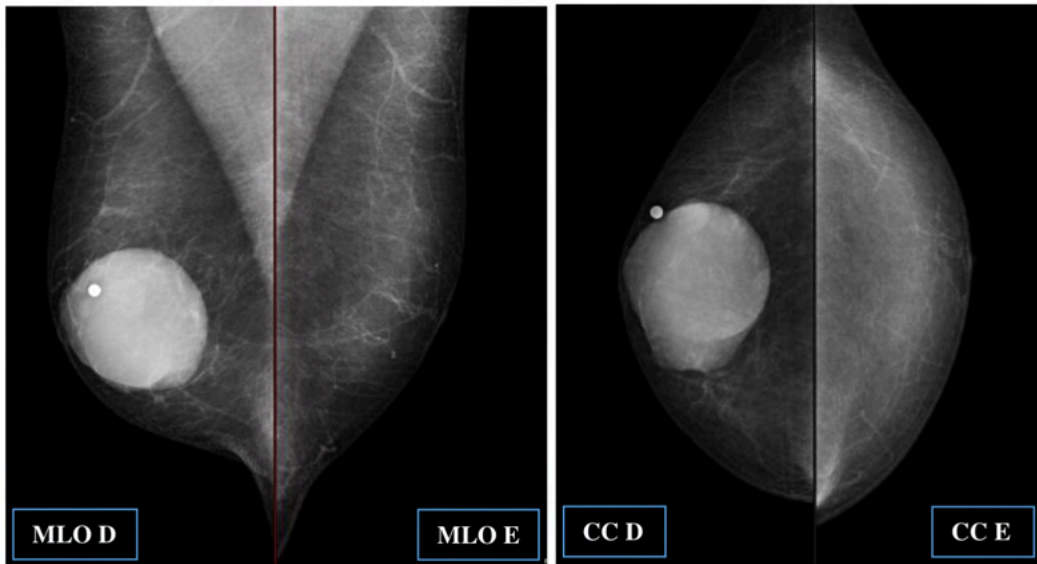


Figure 3: Digital Mammography. Breasts with fatty tissue and a nodule in the right retroareolar region. Lead marker in a palpable nodule in the right breast.

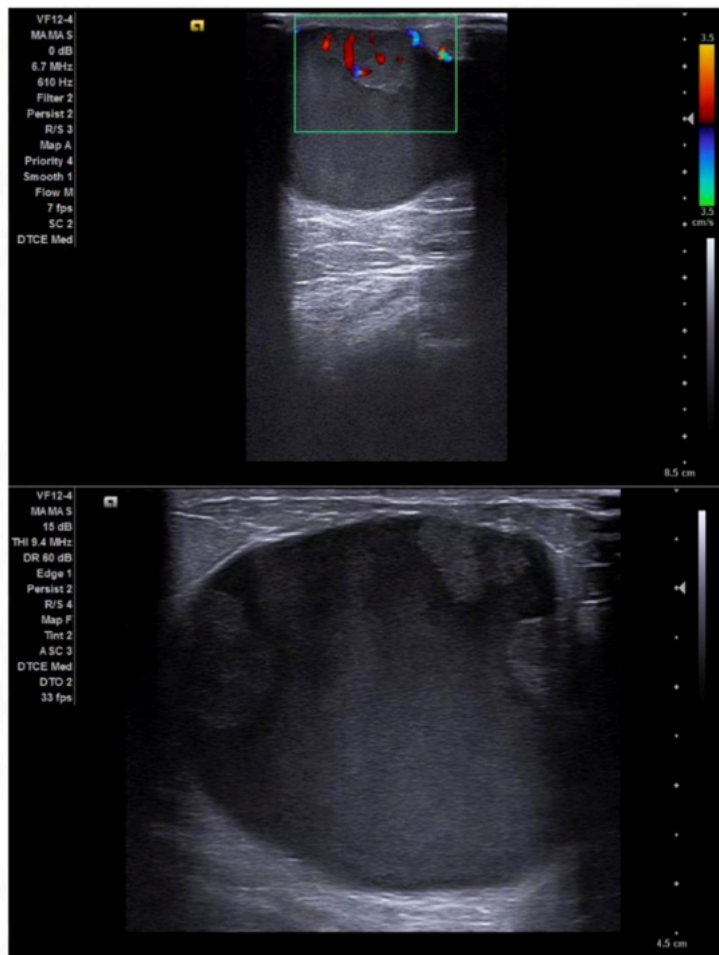


Figure 4: Right Breast US: Solid-cystic nodule, with fine echoes inside, showing flow on color Doppler in its papillary projections.




Figure 5: Immunohistochemistry slide. Calponin: the negativity for expression of this marker evidences the absence of myoepithelial cells in the papillary axes. CK14: absence of CK14 expression in the neoplasm. Estrogen Receptor: Strong and diffuse expression of estrogen receptors in neoplasia.

margin. The walls of the cystic cavitation are smooth and inside it has several sessile polypoid projections, the largest measuring 1.8 cm in diameter. The cyst wall exhibits a projection that apparently communicates with the nipple.

(Figure 6 and 7).

DISCUSSION

Male breast cancer is very uncommon, accounting for less than 1% of male breast cancers. The small amount of

breast parenchyma, along with hormonal, environmental and genetic factors contribute to the low incidence rate of breast cancer in men. Because it is rare, its etiology is still unknown and there is a lack of information on the subject (SALOMON et. al., 2015. YALAZA, M.; INAN, A.; BOZER, M., 2016. GIORDANO, S. H., 2018). Contrary to what is described in the literature above, the patient in the case does not have risk factors for the emergence of this neoplasm, except for being overweight (metabolic risk).

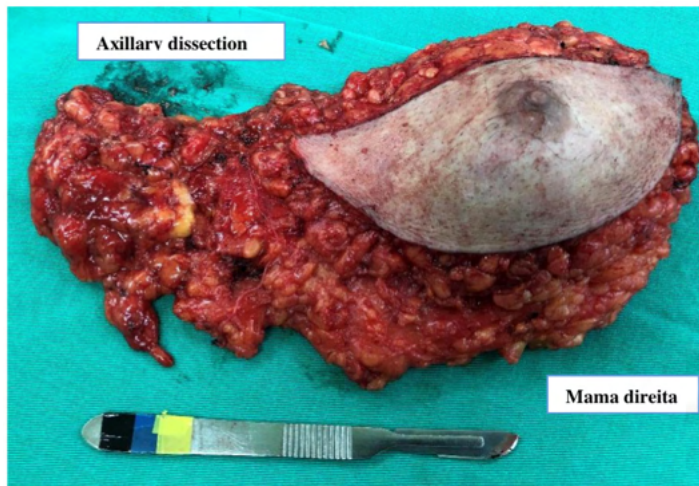


Figure 6: Surgical piece of radical mastectomy with axillary dissection.

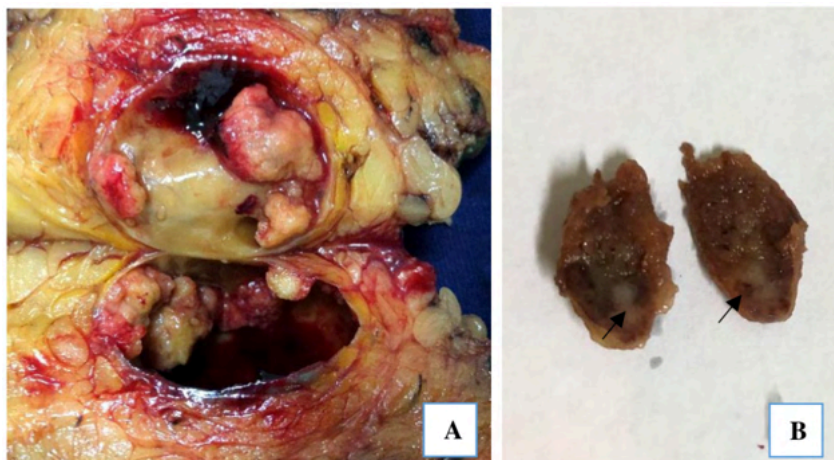

Figure 7: Anatomopathological evaluation of the surgical specimen. A: A wide cystic cavitation with fluid content of hemorrhagic aspect is evidenced, with several sessile polypoid projections on its walls. B: Axillary lymph node with apparent tumor invasion in its adipose hilum (arrows).

Our case disagrees with the data found by Bonfim et. al. (2013), who report in their study that most cases of breast cancer in men are in the age group between 61-75 years of age.

As for the clinical characteristics, Bonfim et. al. (2013) and Giordano (2018) describe that in most male cases, the lesion presents as a painless retroareolar mass, as present in the patient of this case report. However, Giordano (2018) also adds that papillary retraction, bloody papillary discharge, skin ulceration and palpable axillary lymphadenopathy can occur. Such findings were not found in the patient in the case, not corroborating the information in the work of the latter author.

Yalaza, Inan and Bozer (2016) report that the male breast is composed of adipose tissue and does not contain Cooper's ligaments, therefore, it is radiolucent on mammography. Thus, tumors may appear as "a well-defined, lobulated, hyperdense mass with spiculated margins or as a structural distortion". They also report that microcalcifications are less common. The mammographic findings of the present study are in agreement with the imaging findings described by the aforementioned authors, but microcalcifications were not observed in this case.

According to the American Cancer Society (2018) and Giordano (2018), there are some special types of breast cancer, which are subtypes of invasive carcinoma. In the literatures. In addition, Giordano (2018) describes that in most cases of male breast cancer, immunohistochemistry appears to be estrogen receptor positive and HER2 receptor negative than in women with breast cancer. In our study, the subtype shown corresponds to one of the special subtypes and the immunohistochemistry corresponds to the findings of the work described above.

As for the biopsy, Haas, Costa and Souza (2009) report that both fine-needle aspiration (FNA) and core-biopsy (core-biopsy) allow

knowledge of lesion staging through size and presence or absence of axillary lymph nodes. Reefy et. al. (2013) and Fayanju et. al. (2007) apud Lombardi (2019), agree that cytology from FNAC may have dubious results, since the product collected may be from the cystic component, causing a negative result for malignant lesion. The same authors emphasize that core-biopsy is the best way to collect samples for histological analysis. In our patient, FNA was performed, however the result was positive for malignancy, not requiring core needle biopsy.

The surgical treatment performed in our case is also in agreement with the work by Bonfim et al. al. (2013), Solomon et. al. (2015), Freitas et. al. (2015) and Giordano (2018), which predict that modified or simple radical mastectomy can be considered as a therapeutic option in male breast cancer. However, Solomon et. al. (2015) considers that axillary dissection or sentinel lymph node research must be performed in the case of invasive cancer.

Solomon et. al. (2015), Freitas et. al. (2015) and Yalaza, Inan and Bozer (2016) consider that other therapeutic methods can also be included, such as radiotherapy, chemotherapy and adjuvant endocrine therapy. Reefy et. al. (2013) apud Lombardi (2019), adds that systemic adjuvant therapy has focused on the use of Tamoxifen, since papillary carcinoma tends to be estrogen/progesterone receptor positive and HER2 negative. The patient in this study did not complete his treatment at the health unit where the surgery was performed. Thus, we do not have more data to finalize adjuvant therapy and quality of life after starting therapy.

CONCLUSION

The present work reports a rare case of male breast cancer and demonstrates its diagnostic and therapeutic difficulty, in

addition to evidencing the precariousness of data in the medical literature. From this report, we can observe that breast cancer in men behaves differently from breast cancer in women. Thus, further studies are needed in this area that correlate epidemiological and clinical data, tumor biology, treatment, prognosis and factors that contribute to the survival of male patients.

THANKS

I am grateful for the help of the Radiologist Dr. Sócrates Lote, the Pathologist Doctors, Dr. Antônio Palhares and Dr. Adriano Almeida, and the Nurse Davi Matos.

REFERENCES

- AMERICAN CANCER SOCIETY. **About Breast Cancer in Men**, 2018. Disponível em: <<https://www.cancer.org/content/dam/CRC/PDF/Public/8584.00.pdf>>. Acesso em: 31 out 2021.
- BONFIM, R. J. A. *et. al.* Câncer de mama no homem: análise dos aspectos epidemiológicos, clínicos e terapêuticos em serviço formal brasileiro. **Revista Brasileira de Oncologia Clínica**. 2013, v. 10, n. 37, p. 90-96.
- FREITAS, G. B. *et. al.* Papiloma intraductal. **Revista Brasileira de Mastologia**, 2015, v.25, n.1, p.1-2.
- GIORDANO, S. H. Breast câncer in men. **New England Journal of Medicine**, 2018; v.378, p. 2311-20.
- HAAS, P.; COSTA, A.B.; SOUZA, A. P. Epidemiologia do câncer de mama em homens. **Revista do Instituto Adolfo Lutz**. São Paulo, 2009, v.8, n. 3, p. 476-81.
- LOMBARDI, W. *et. al.* Carcinoma papilífero intracístico mamário bilateral. Colégio Brasileiro de Cirurgia, **Relatos Casos Cirúrgicos**, 2019; v.5, n.1, p.e2061.
- SOLOMON, M. F. B. *et. al.* Câncer de mama no homem. **Revista Brasileira de Mastologia**, 2015, v.25, n.4, p.141-5.
- YALAZA, M.; INAN, A.; BOZER M. Câncer de mama masculino. *The Journal Breast Health*, 2016; v. 12, n.1, p. 1-8.