

**EVALUATION OF
MECHANICAL
CIRCULAR SUTURE
IN THE CERVICAL
ESOPHAGOGASTRIC
ANASTOMOSIS IN
PATIENTS SUBMITTED
TO RESCUE
ESOPHAGECTOMY
AFTER
CHEMORADIOTHERAPY
WITH EXCLUSIVE
INTENT FOR ADVANCED
MALIGNANT
ESOPHAGUS
NEOPLASIA**

Gabriela Margato Pascon

Faculty of Medicine Life Sciences Center
<http://lattes.cnpq.br/1119690604229934>

José Luís Braga de Aquino

Research Group: Clinical Surgical Diagnosis
and Therapeutics

Life Science Center

[https://sistema.atenaeditora.com.br/
index.php/admin/ID%20Lattes%20
1833453392773484](https://sistema.atenaeditora.com.br/index.php/admin/ID%20Lattes%201833453392773484)

All content in this magazine is licensed under a Creative Commons Attribution License. Attribution-Non-Commercial-Non-Derivatives 4.0 International (CC BY-NC-ND 4.0).



Abstract: Esophageal cancer is the third most frequent neoplasm of the gastrointestinal tract. As they are consumed patients and with other comorbidities, mainly cardiopulmonary, they are difficult to manage clinically and therapeutically. Chemoradiation was recommended as the exclusive treatment for esophageal cancer considered unresectable, however, low survival rates were observed. Thus, rescue esophagectomy gained space in this scenario of limited therapeutic possibilities, due to its higher survival rates. In this work, 5 patients diagnosed with malignant esophageal neoplasia who underwent previous chemoradiation (initially considered unresectable) through clinical examinations, imaging and staging to assess the possibility of salvage esophagectomy were studied. Once the indication for this surgery was confirmed, it was performed between 4 to 6 months after the end of clinical cancer treatment in the 5 patients in the study. Thus, the present scientific initiation work proposes to evaluate the complications of rescue esophagectomy after exclusive intention chemoradiation for advanced esophageal cancer with cervical esophagogastric anastomosis by mechanical circular suture, as well as if there was improvement of dysphagia and of the quality of life of these patients.

Keywords: Cancer, esophagectomy, mechanical suture.

INTRODUCTION

Esophageal neoplasia ranks third among the most frequent malignant tumors of the gastrointestinal tract [1,2,3,4]. These are patients with difficult clinical control due to this consutive condition.

Therefore, few therapeutic possibilities remain. In recent years, chemoradiation has been advocated as the exclusive treatment for locally advanced esophageal cancer considered unresectable [1,2,3,4]. However,

a poor prognosis was observed and salvage esophagectomy came to be considered the best treatment due to its higher survival rates.

However, it can present complications, mainly at the level of the anastomosis with the esophagus.

MATERIALS AND METHODS

In the period from August 2018 to July 2019, in the Thoracic Surgery Service of Hospital PUC Campinas, five patients diagnosed with malignant esophageal neoplasm with clinical conditions of undergoing rescue esophagectomy, after having previously undergone chemoradiation, were studied due to advanced tumors considered initially unresectable.

The five patients in the study in the initial evaluation for presenting malignant neoplasm of advanced and unresectable esophagus with invasion of the aorta and tracheobronchial tree (stage T4b), underwent chemoradiation with exclusive intention with daily dose of radiotherapy until completing 50 to 60Gy, according to the established standardization by the Radiotherapy Service of Hospital Mario Gatti, in partnership with Hospital PUC Campinas by the SUS health network. The same was true for chemotherapy, with all patients receiving doses of 5-fluorouracil and cisplatin for 12 to 15 weeks, according to standardization established by the Chemotherapy Service of Hospital PUC Campinas.

The patients underwent a new assessment to demonstrate the possibility of resectability of the neoplasm through:

Clinical evaluation - Of the study patients, all had dysphagia with criterion 2 of SAEED et al 1995: 0- unable to swallow; 1- swallow liquids with difficulty; do not swallow pasty and solids; 2- swallow liquids without difficulty, swallow pasty with difficulty; 3- swallow liquids and pastes without difficulty;

4- swallow liquids and pastes without difficulty, occasional difficulty for solids;
5- normal swallowing. They also reported weight loss of 7 to 19 kg after the end of the chemoradiation, smoking an average of 20 to 40 cigarettes per day and drinking 2 to 3 doses of spirits per day.

Preoperative evaluation for staging after chemoradiation therapy: Upper Digestive Endoscopy - in two patients, this exam confirmed the presence of malignant neoplasm, with biopsy confirming squamous cell carcinoma

- Computed Tomography of the Chest, Computed Tomography of the Head and Neck and Computed Tomography of the Abdomen that demonstrated resectability (absence of infiltrations) and absence of metastases.

Cardiopulmonary evaluation: chronic obstructive pulmonary disease and hypertensive heart disease were demonstrated, both controlled with medication and, therefore, without contraindications for the proposed surgical procedure.

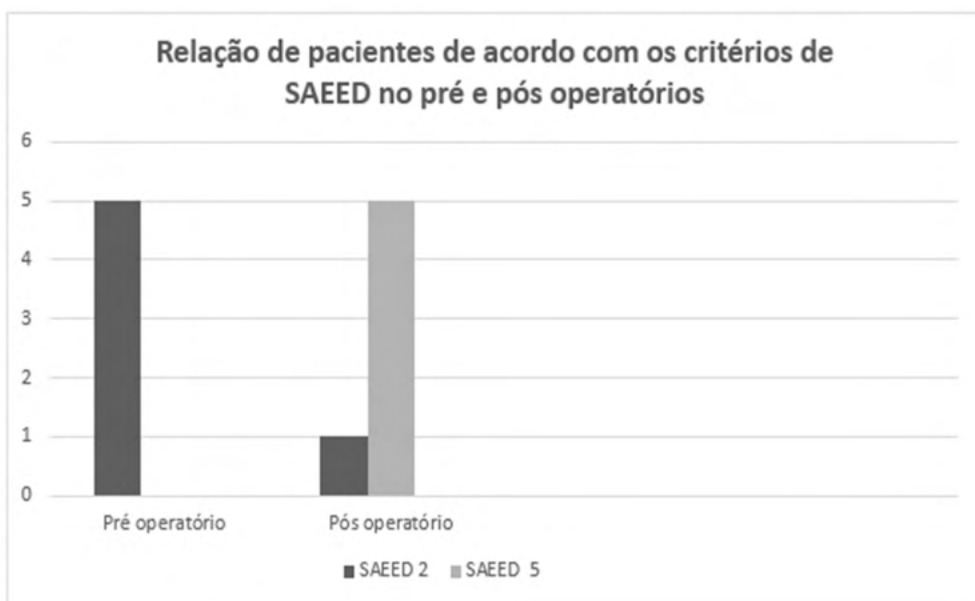
Nutritional assessment: weight loss > 15% of ideal was demonstrated in two patients, with parenteral nutrition being performed for 15 to 20 days before surgery.

All patients also underwent motor and respiratory physiotherapy during the same period prior to the surgical procedure, which consists of the rescue esophagectomy technique through the access routes: cervical, thoracic and abdominal.

RESULTS

Postoperative evaluation: was performed regarding the presence of systemic clinical complications, mainly cardiopulmonary, through laboratory tests, imaging methods and clinical evaluations.

performed daily; local complications, such as dehiscence and/or stenosis of the cervical esophagogastric anastomosis and quality of swallowing after hospital discharge, with comparison of dysphagia to the preoperative period, according to the SAEED criteria in graph 1 below.



List of patients according to the SAEED criteria in the pre and postoperative periods.

Graph 1: List of patients according to the SAEED criteria in the pre and postoperative periods.

Thus, in the early evaluation, up to 30 days after surgery, two patients had pulmonary infection, both having a good evolution with specific clinical treatment.

No patient in the study had clinical or radiological evidence of fistula at the level of the cervical esophagogastric anastomosis until the 7th postoperative day. Thus, an oral diet was introduced, initially liquid and progressively pasty and solid, according to patient acceptance.

On the 55th postoperative day, one patient had symptoms of high dysphagia for pasty foods (SAEED criterion 2); Contrast-enhanced X-ray and upper digestive endoscopy showed stenosis of the cervical esophagogastric anastomosis (graph 2).

Five sessions of endoscopic dilation were performed, with the patient having good evolution through the rescue of swallowing.

Mid-term evaluation, approximately 5 to 11 months, was performed in four patients. They did not file any complaints, referring suspension of some habits and satisfaction with the surgical procedure, as it provided significant improvement in swallowing

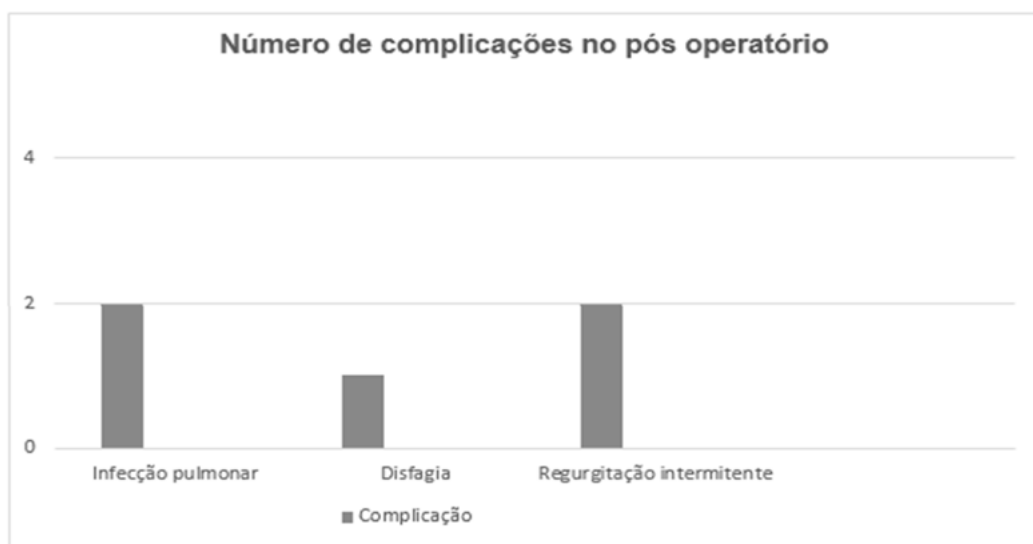(according to the SAEED criteria), return to activities and weight gain. However, two patients reported intermittent regurgitation.

In the remaining patient, no mid-term evaluation was performed, as he was in the recent 18-day postoperative period.

DISCUSSION

Esophagectomy has always been the treatment of choice for esophageal cancer, despite its cure rates not exceeding 40% [1]. The low effectiveness of this procedure in curative terms is explained by the early systemic spread of esophageal cancer, increasing the chances of patients presenting occult metastases at the time of diagnosis. Another factor involved is the intrinsic anatomical relationship of the esophagus, located close to the vital structures of the mediastinum, which makes adequate oncological resection difficult.

In locally advanced esophageal lesions without conditions of resectability, or in those patients with clinical contraindication to surgery, an alternative that has been demonstrated is the combination of radiotherapy with exclusive chemotherapy



Number of complications in the postoperative period.

Graph 2: Number of complications in the postoperative period.

with a definitive proposal.

This was well demonstrated in the five patients in the study, as in the initial evaluation they all had advanced esophageal squamous cell carcinoma with invasion of the mediastinal structures, which contraindicated resectability. Thus, there was an indication of chemoradiation with the intention of being exclusive, in order to reduce or even totally banish tumors and try to provide a better quality of life even with low survival potential.

Despite this treatment, the five patients still had the tumor lesion in the reassessment performed, but to a lesser extent and with the possibility of resection.

Thus, it began to be demonstrated that the only way to attempt a potential cure in these patients with persistent or recurrent disease after the use of chemoradiation with exclusive intention would be the rescue esophagectomy, as several series demonstrated a survival rate of three to five years from 60 to 40% respectively. From a theoretical point of view, the rescue operation is endowed with greater technical difficulty, due not only to the high doses of radiation applied to the tumor bed, but also to the longer time interval between the end of the treatment and the operation, which determines greater degree of fibrosis between the periesophageal structures, and thus providing greater postoperative morbidity and mortality. In this study, all patients underwent salvage surgery 4 months or more after completion of chemoradiation.

Due to this longer interval between surgery and the end of chemoradiation, with the consequent fibrosis that could be present at the mediastinal level, it was decided to perform esophageal resection by right thoracotomy in all patients, as this access route provides a better view of the operative field and thus be able to minimize complications, a fact that is also reported by other authors.

As for morbidity related to esophagogastric anastomosis dehiscence, it basically depends on the location of the anastomosis, the viability of the gastric conduit and the conditions of the perianastomotic tissues, which can block possible fistulas. The most favorable situation is when the dehiscence occurs in the cervical region, with a viable gastric conduit protected by the soft tissues around the suture.

Another fact that must be highlighted to minimize the potential dehiscence of this anastomosis at the cervical level is the use of mechanical suture, which, as it is easy, fast, in two planes and inverted, provides better safety, as has been demonstrated by several authors in benign and malignant conditions. And this was well demonstrated in our study, as none of the patients presented this complication with the use of circular mechanical suture, starting the oral diet from the 7th day after surgery.

Despite the good evolution, one patient had anastomotic stenosis from the 55th day after surgery. This was probably due to the anatomically small diameter of the esophagus, which led to the use of a circular appliance with a smaller diameter, number 25mm, and thus predisposing to stenosis. Yendamuri et al [5] have already demonstrated in their series of patients who underwent mechanical suture in the esophagus at the cervical level that the stenosis of this anastomosis is related to the diameter of the device.

Although this complication compromises quality of life, due to the dysphagia that presents, it is resolved most of the time with endoscopic dilation, a fact that occurred with this patient, who rescued swallowing after 5 sessions with this procedure.

However, due to the small sample size due to the limited study time, it is difficult to infer that the mechanical suture is adequate. The same occurs in the mid-term evaluation, which despite the fact that the four patients reported being satisfied with the surgical procedure

(because they improved their quality of life, with total rescue of swallowing and return to their usual activities), the follow-up time was limited to 11 months.

Therefore, in order to draw more adequate conclusions as to whether rescue esophagectomy with circular mechanical cervical esophagogastric anastomosis after previous chemoradiation in patients with advanced esophageal malignancy is adequate, it would be important to continue the study with the same methodology but with a larger number of patients and with longer evaluation time.

THANKS

I thank the Pontifical Catholic University of Campinas for promoting research, Dr. José Luís Braga de Aquino for the opportunity, the patients for their teaching, contribution and patience.

REFERENCES

1. Kumagai, K. et al. (2016) Systematic review and meta-analysis on the significance of salvage esophagectomy for persistent or recurrent esophageal squamous cell carcinoma after chemoradiotherapy. *Dis Esophagus*;29(7):734-39
2. Swisher S. et al. (2017) Salvage esophagectomy for persistent or recurrent disease after definitive chemoradiation. *Ann Cardiothorac Surg*; 6(2):144-51
3. Markar S. et al. (2015) Salvage surgery after chemoradiotherapy in the management of esophageal cancer. Is it a viable therapeutic option?. *J Clin Oncol*;33(33):3866-73
4. Farinella E. et al. (2016) Salvage esophagectomy after failure of definitive radiochemotherapy for esophageal cancer. *J Surg Oncol*;114: 833-37
5. Yendamuri, S. et al. (2011). Does Circular Stapled Esophagogastric Anastomotic Size Affect the Incidence of Postoperative Strictures? *Journal of Surgical Research*. 165(1): 1-4.