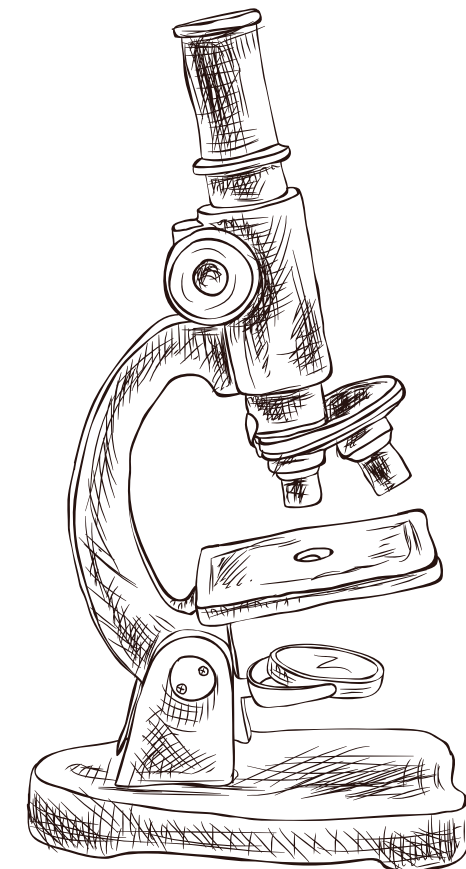
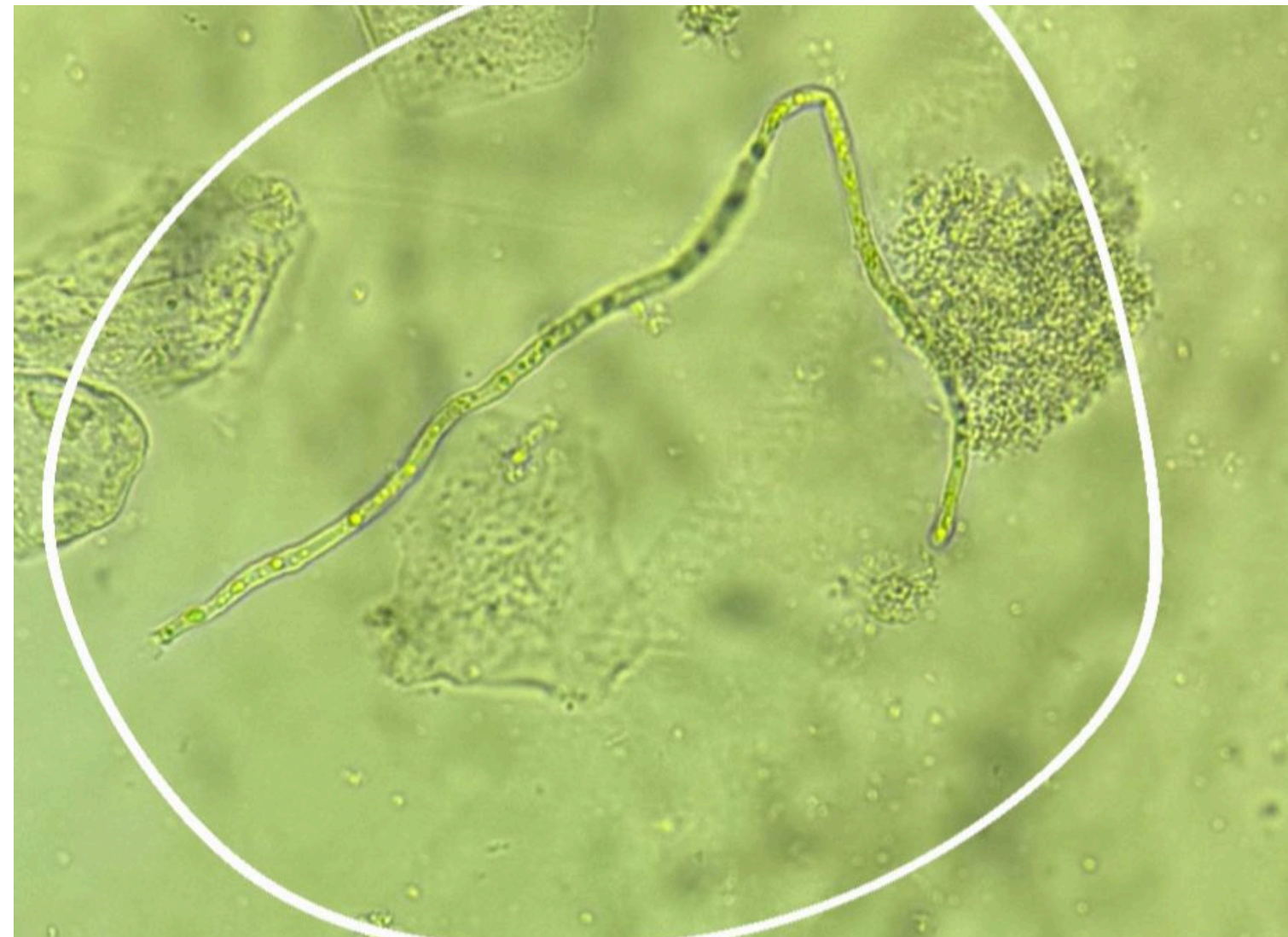


# ATLAS DE SECREÇÃO VAGINAL


LEAC- LABORATÓRIO ESCOLA DE  
ANALISES CLINICAS



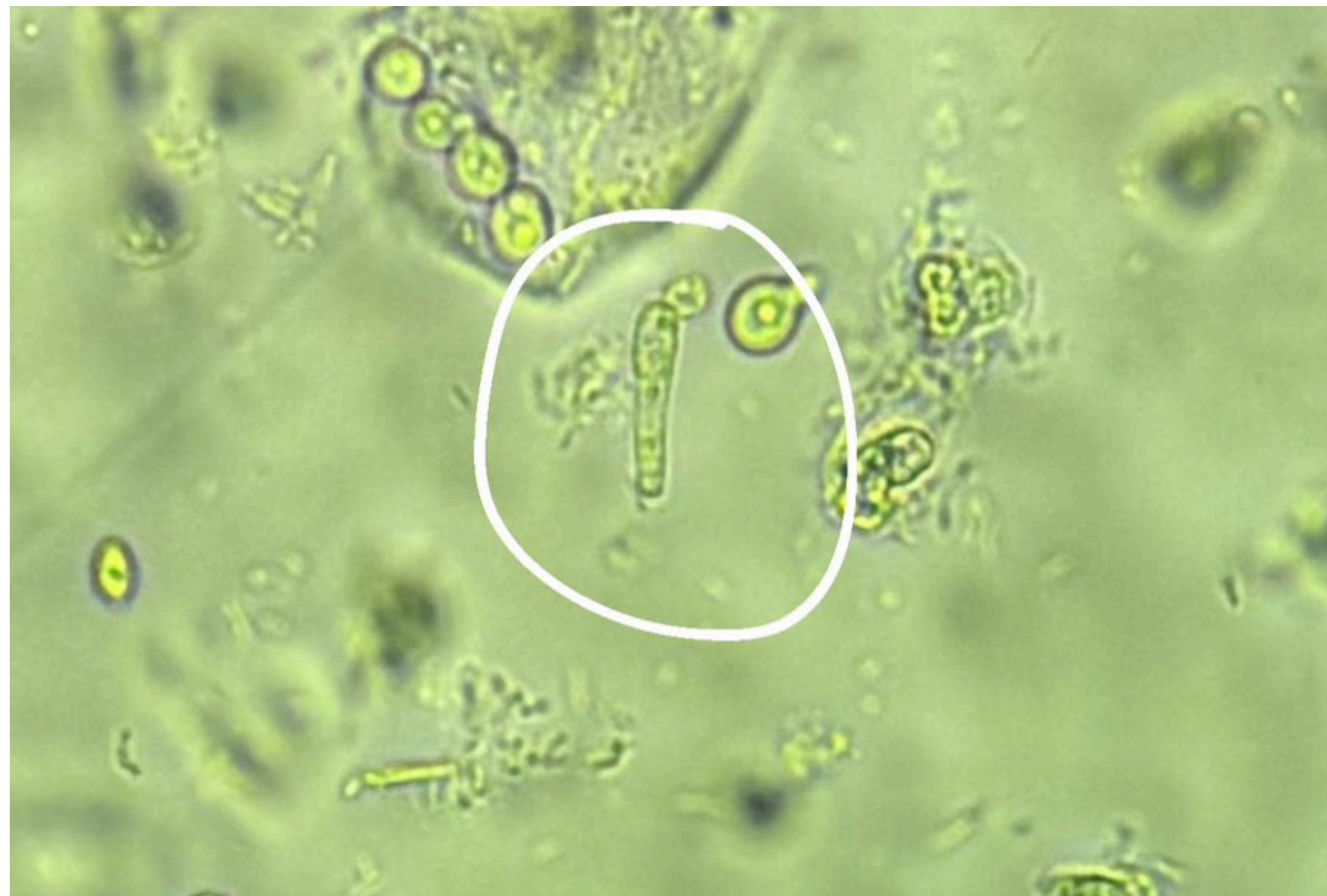# HIFA HIALIANA SENOCÍTICA REGULAR




LEAC- LABORATÓRIO ESCOLA DE  
ANALISES CLINICAS



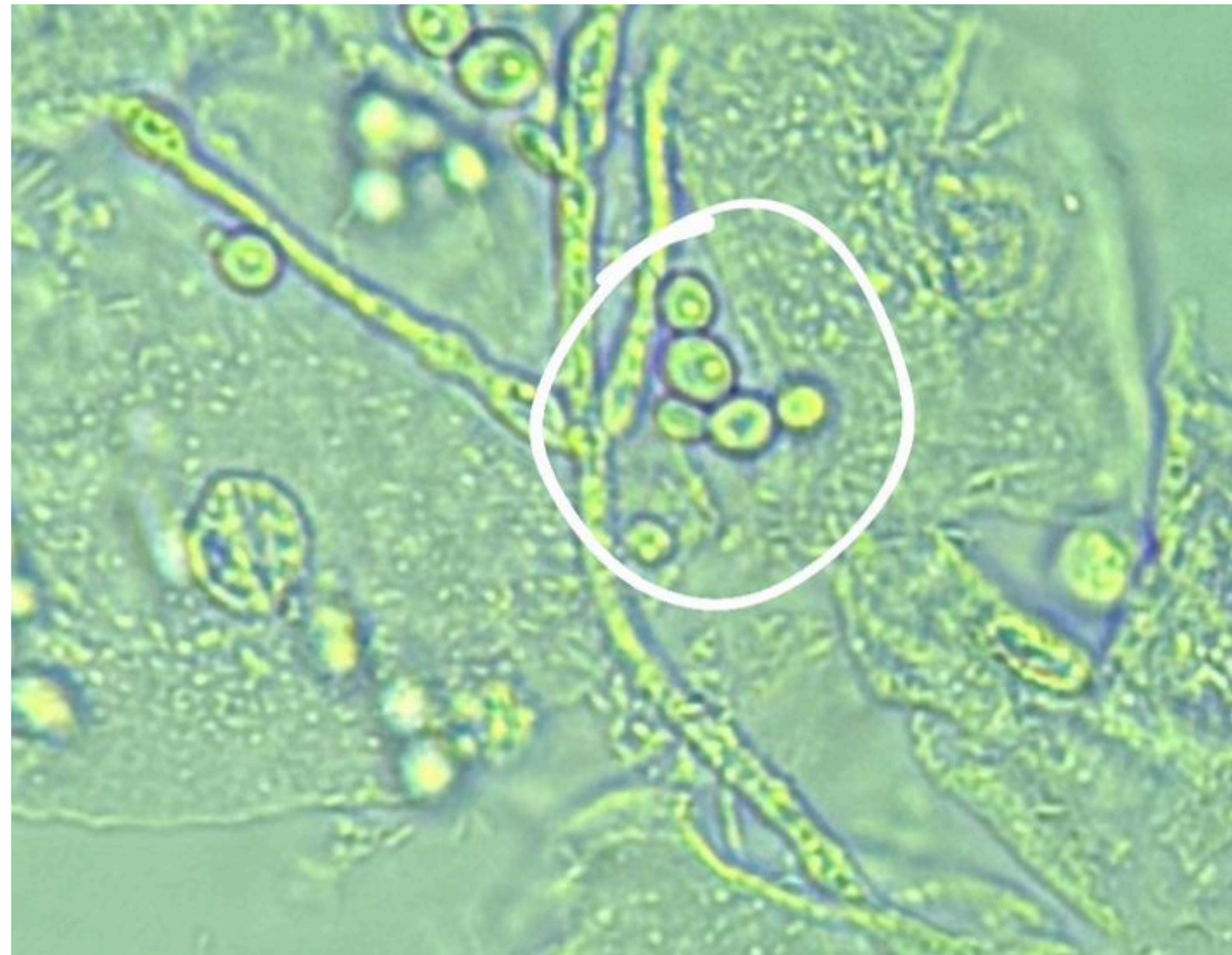
## ESTRUTURA TUBULAR GERMINATIVA



LEAC- LABORATÓRIO ESCOLA DE  
ANALISES CLINICAS

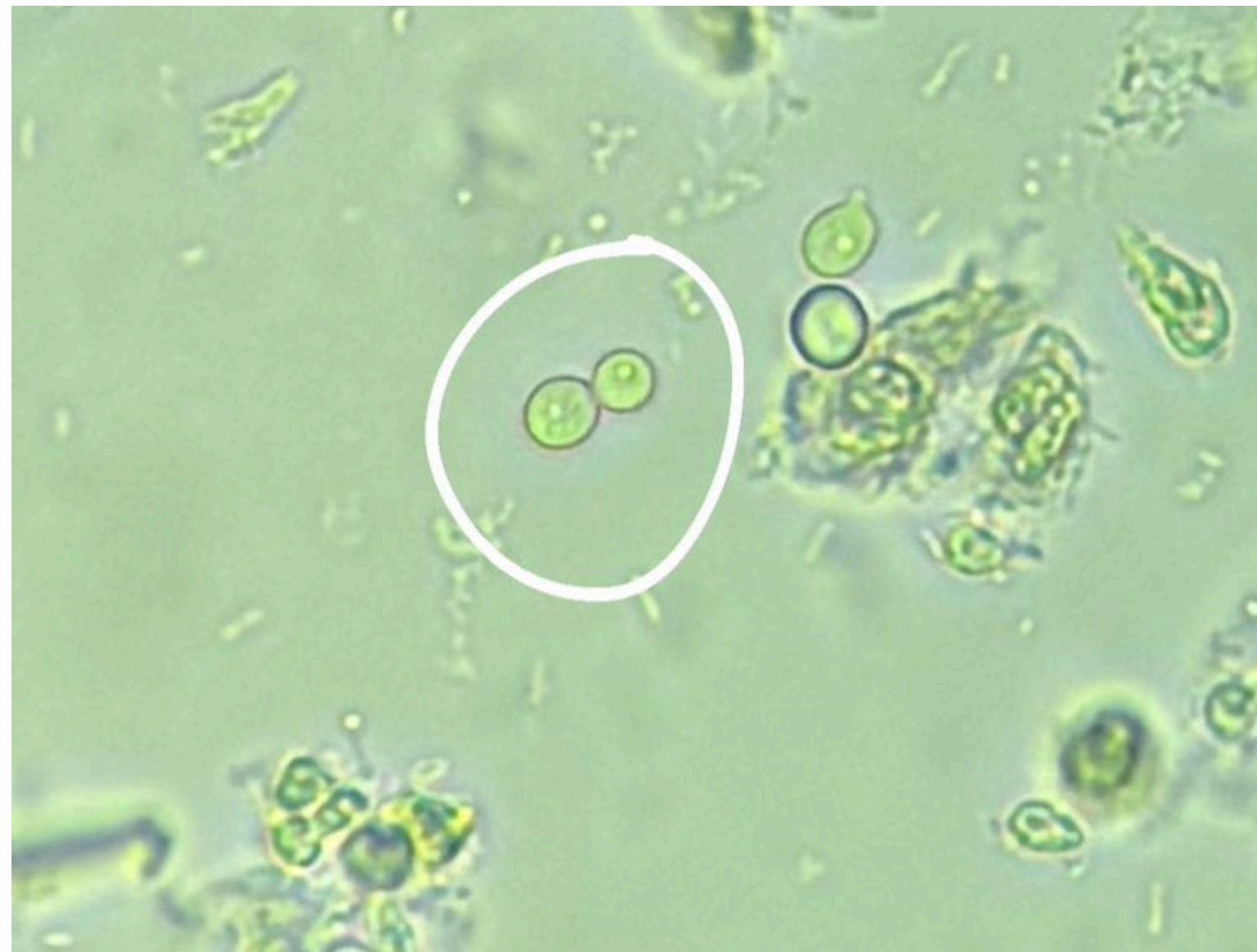

# BLASTOCONIDEO BROTAMENTO COMPOSTO




LEAC- LABORATÓRIO ESCOLA DE  
ANALISES CLINICAS

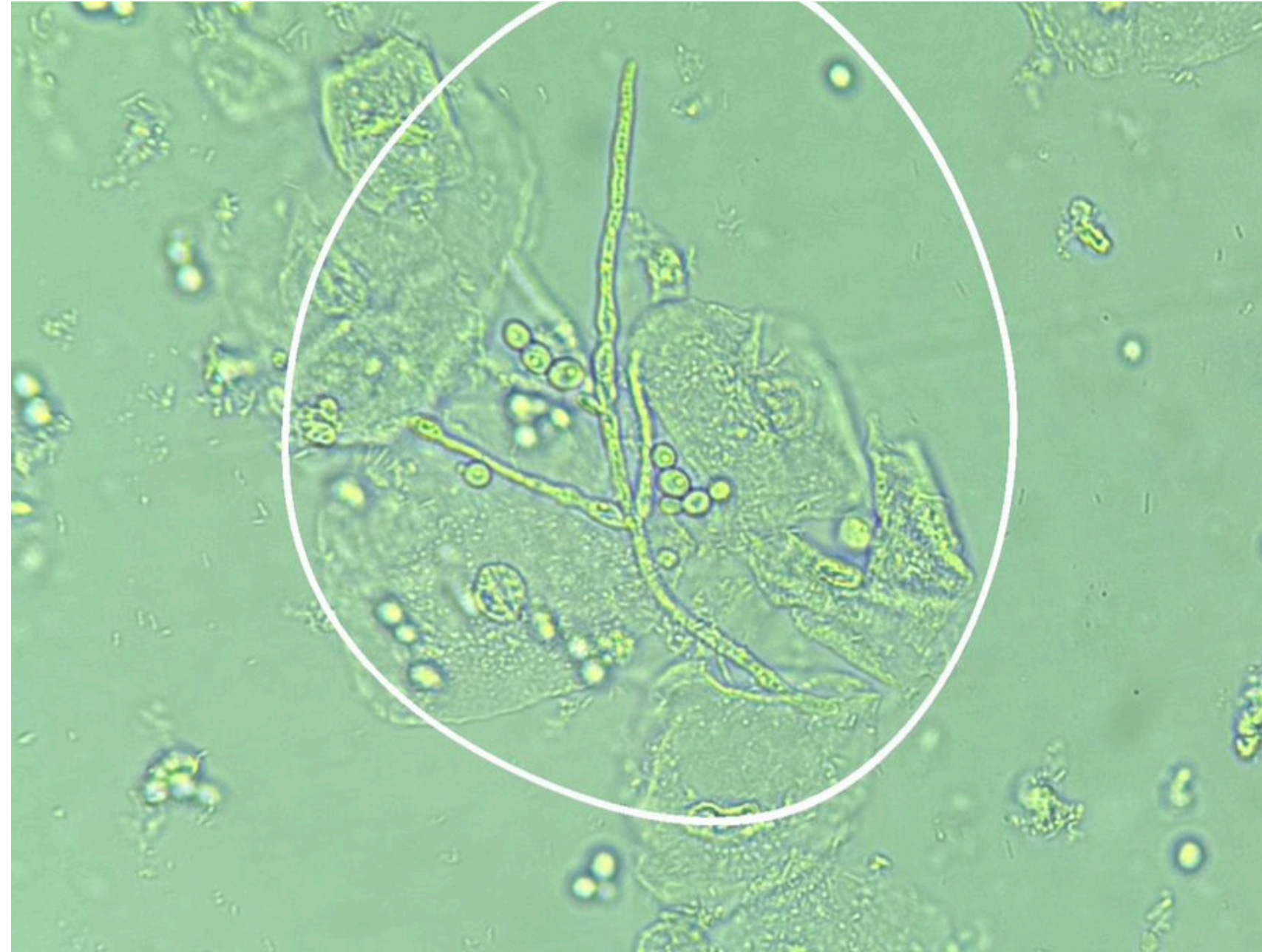# BLASTOCONIDEO BROTAMENTO SIMPLES




LEAC- LABORATÓRIO ESCOLA DE  
ANALISES CLINICAS



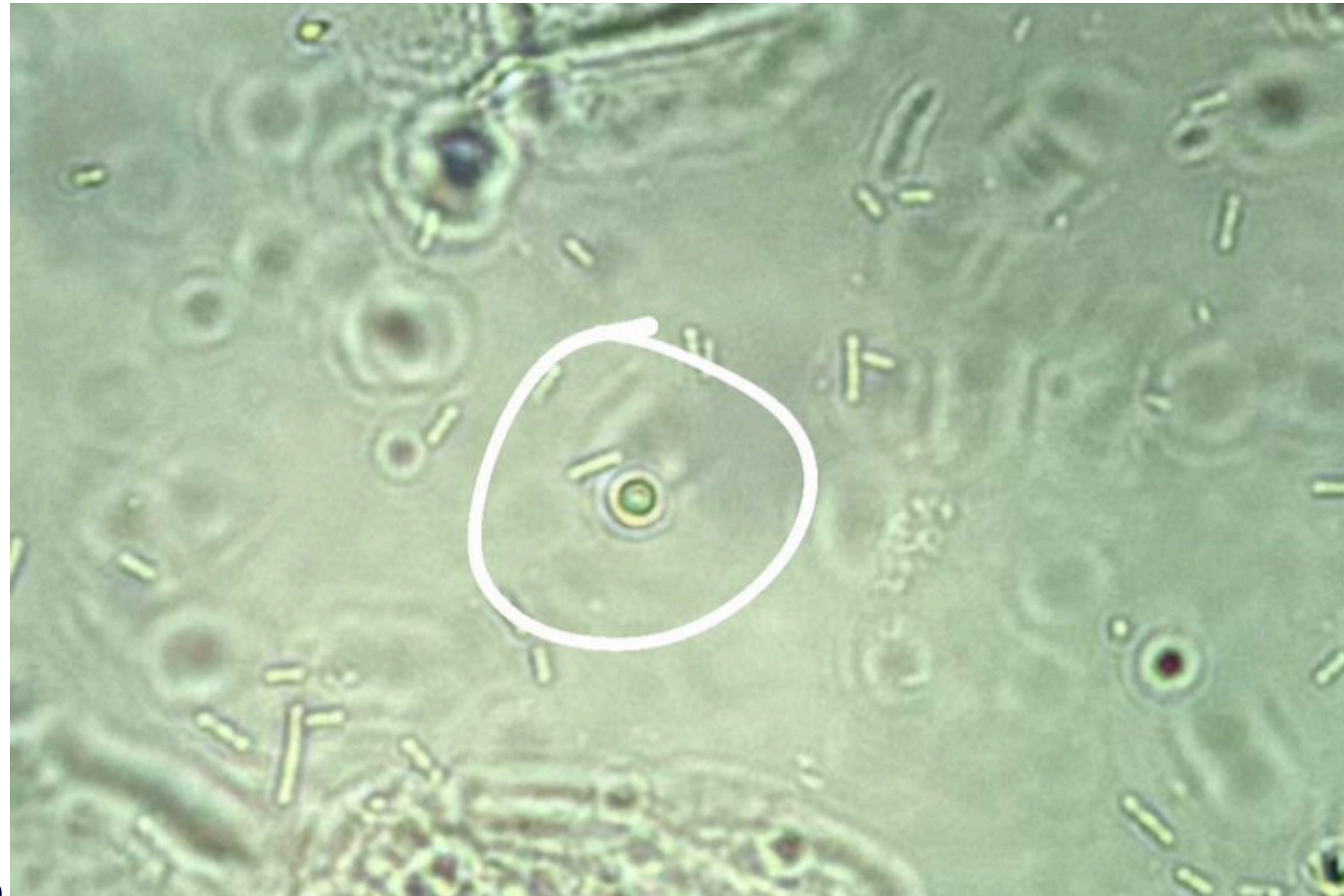# PSEUDO-HIFA




LEAC- LABORATÓRIO ESCOLA DE  
ANALISES CLINICAS



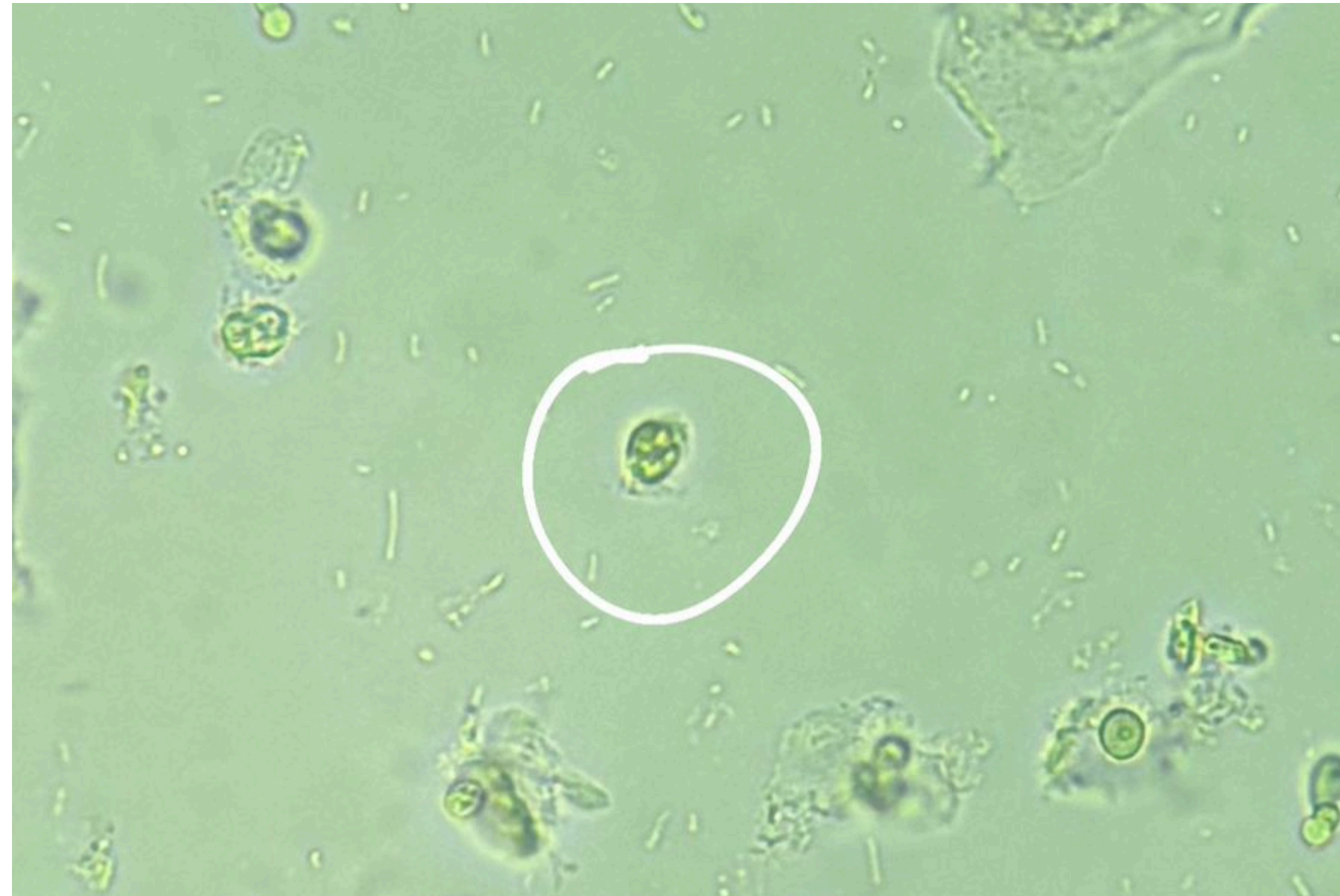# HEMÁCIA



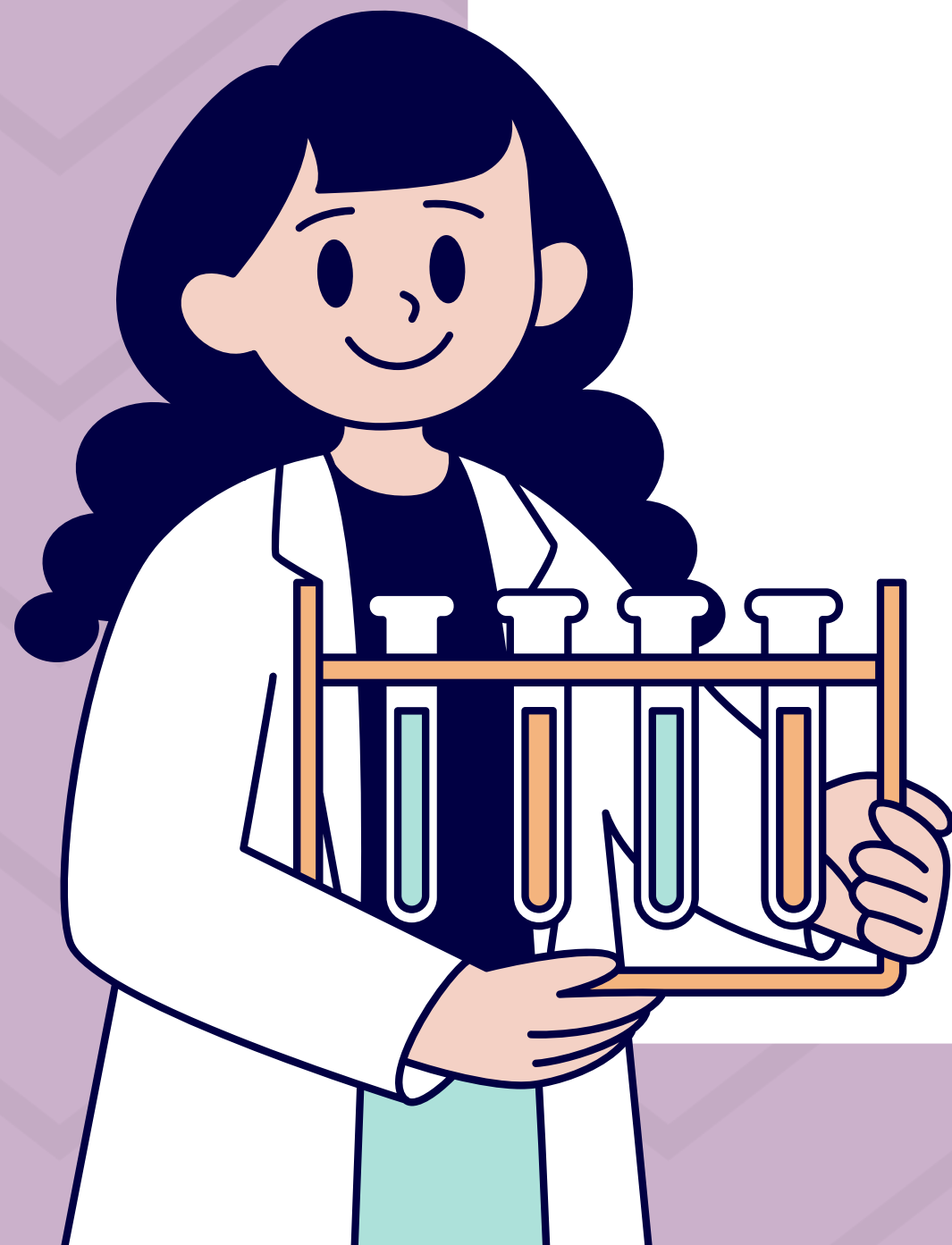LEAC- LABORATÓRIO ESCOLA DE  
ANALISES CLINICAS



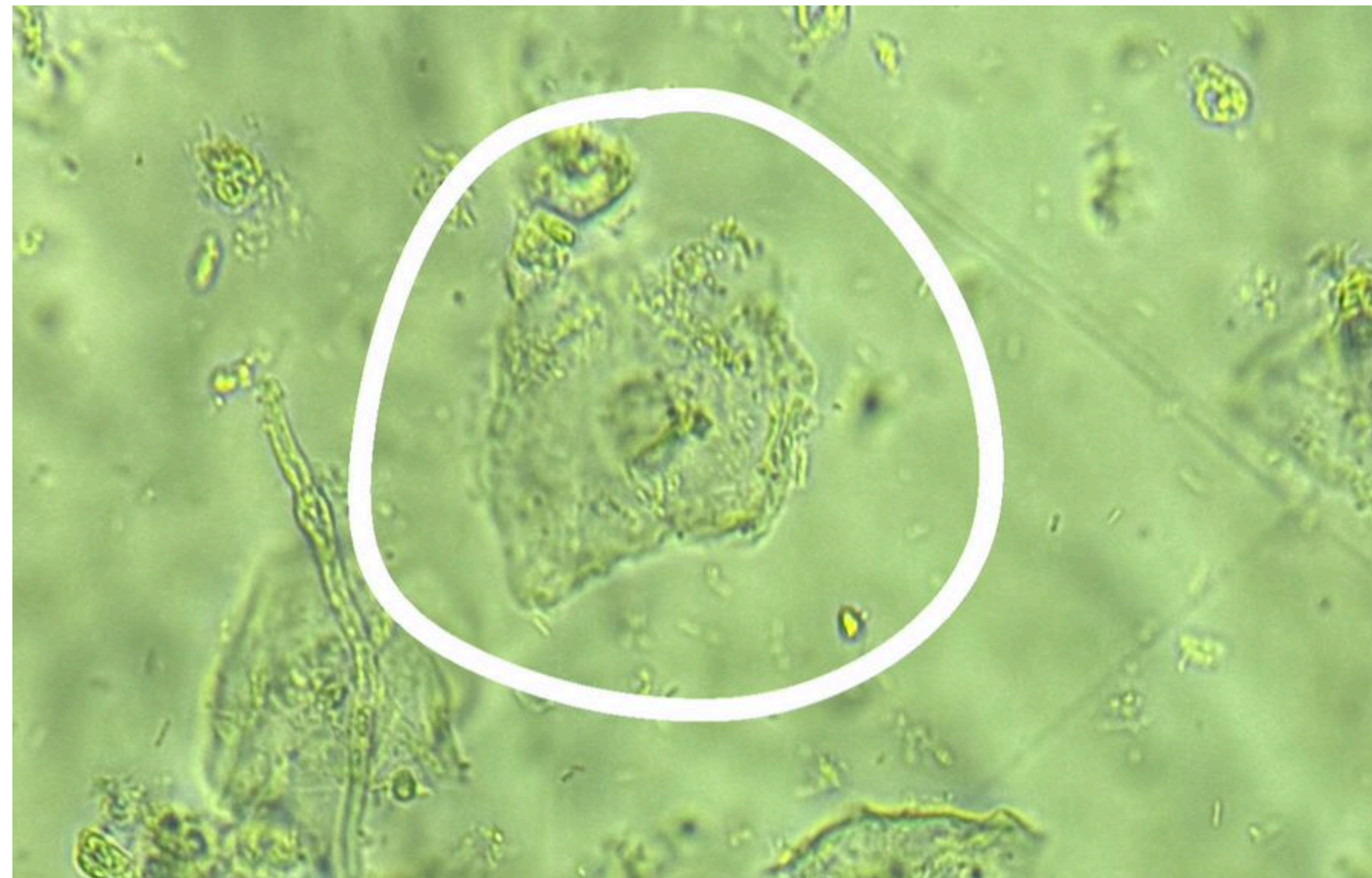# LEOCÓCITO



LEAC- LABORATÓRIO ESCOLA DE  
ANALISES CLINICAS



# CÉLULA EPITELIAL

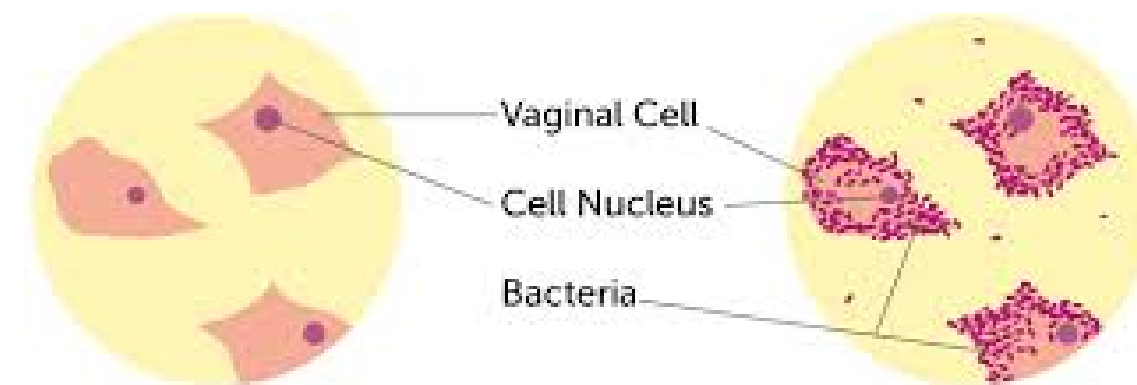
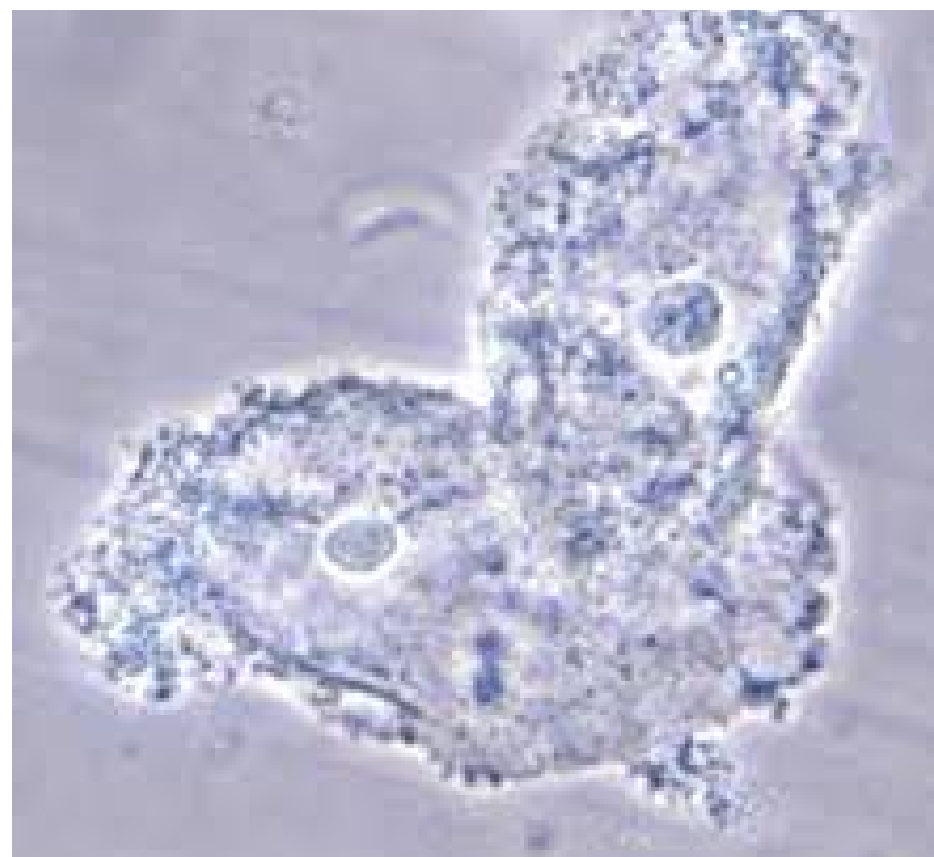


LEAC- LABORATÓRIO ESCOLA DE  
ANALISES CLINICAS



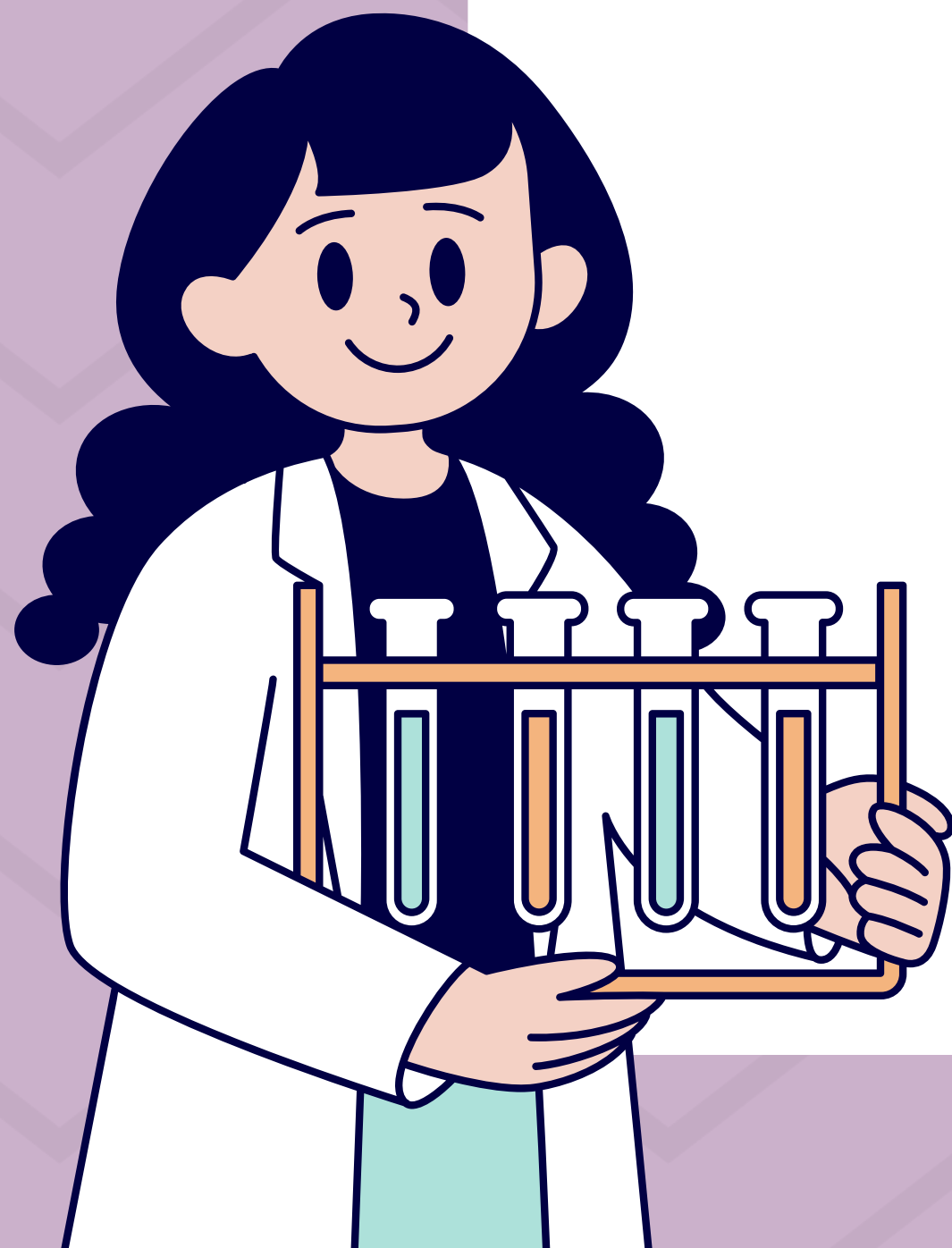
# CLUE CELLS

CLUE CELLS SÃO CÉLULAS DO EPITÉLIO VAGINAL RECOBERTAS POR BACTÉRIAS, INDICATIVAS DE VAGINOSE BACTERIANA.



Normal vaginal cells seen under a microscope.

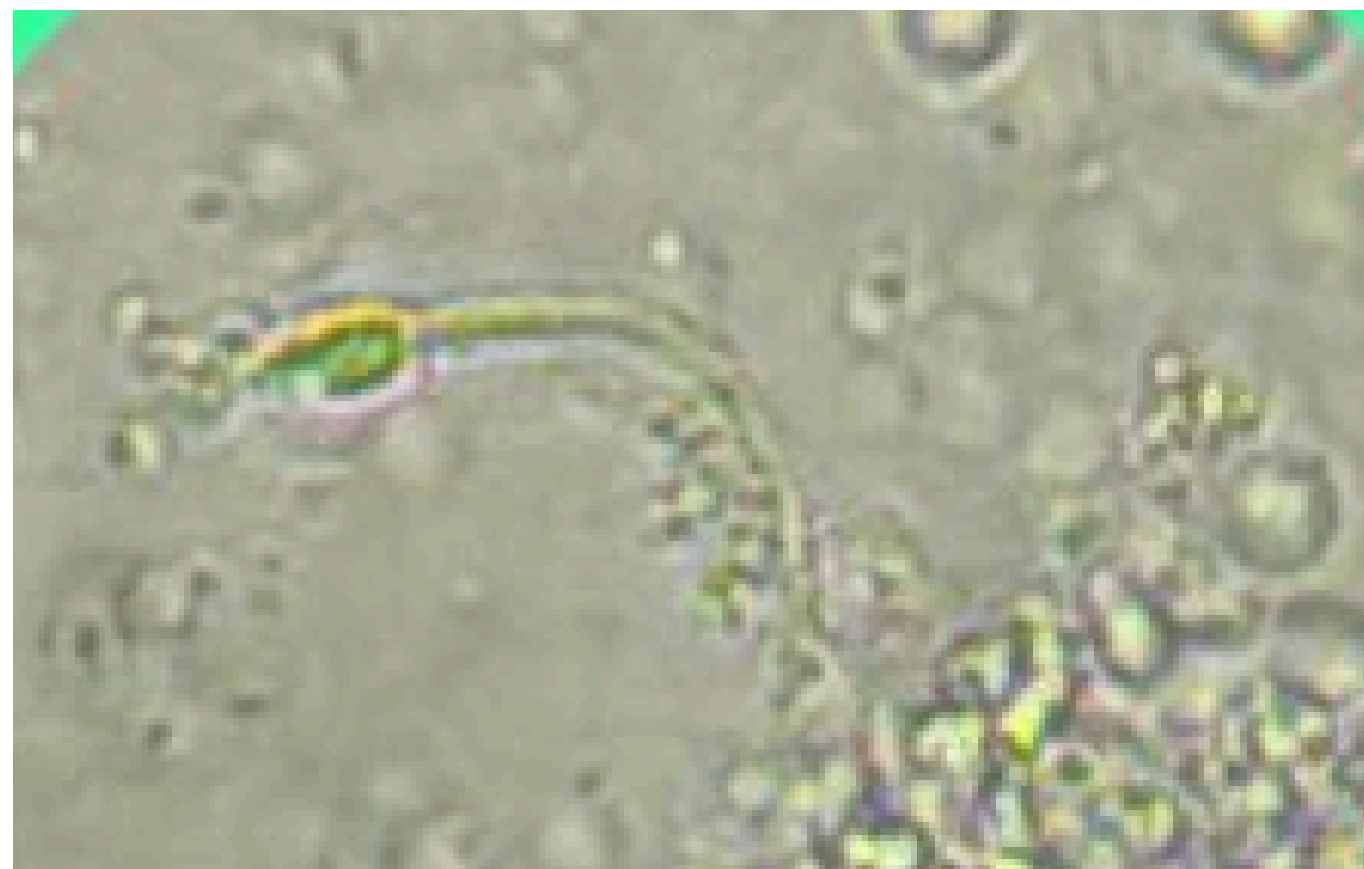"Clue Cells", vaginal cells with bacteria stuck to them.



LEAC- LABORATÓRIO ESCOLA DE  
ANALISES CLINICAS



"PODE ATÉ SER ENCONTRADO, MAS NÃO É FUNGO... É SÓ UM ESPERMATOZOIDE DANDO UM ROLÊ RARO POR AÍ!"



LEAC- LABORATÓRIO ESCOLA DE ANALISES CLINICAS

